



Guideline on the diagnosis and treatment of sclerosing diseases of the skin

Developed by the Guideline Subcommittee of the European Dermatology Forum

Subcommittee members:

Members of the EDF Guideline Committee:

Chairman of EDF Guideline Committee:

Authors:

R. Knobler,¹ P. Moinzadeh,² A. Cozzio,³ M. Cutolo,⁴ C. Denton,⁵ L. Frasin,⁶ A. Gabrielli,⁷
N. Hunzelmann,² A. Kreuter,⁸ L. Mouthon,⁹ F. Ronglietti,¹⁰ L. Rudnicka,¹¹ V. Smith,¹²
T. Krieg²

¹Department of Dermatology, Medical University of Vienna, Vienna, Austria

²Department of Dermatology, University of Cologne, Cologne, Germany

³Department of Dermatology, University Hospital Zürich, Zürich, Switzerland

⁴Research Laboratories and Clinical Academic Division of Rheumatology at the University
Medical School of Genova, Italy

⁵Department of Rheumatology, Royal Free Hospital, London, UK

⁶Department of Dermatology, Pediatric Dermatology, Lecco Hospital, Lecco, Italy

⁷Department of Clinical Sciences and Molecular, University Polytechnic, Ancona, Italy

⁸Department of Dermatology, Venerology and Allergology, HELIOS St. Elisabeth Hospital,
Oberhausen, Germany

⁹Department of Internal Medicine, National Referral Center for Rare Autoimmun and Systemic Diseases Hospital Cochim, Paris, France

¹⁰Department of Dermatology, University of Cagliari, Cagliari, Italy

¹¹Department of Dermatology, Medical University of Warsaw, Warsaw, Poland

¹²Department of Rheumatology, Ghent University Hospital, Ghent University, Ghent, Belgium

Co-Authors:

E. Aberer, M. Bagot, G. Bali, D. Belz, L. Borradori, J.D. Bouaziz, A.K. Braae Olesen, I. Foeldvari, C. Frances, K. Hofoed, A. Jalili, U. Just, V.-M. Kähäri, S. Karpati, D. Krasowska, M. Mogensen, M. Olszewska, C. Orteu, J. Panelius, A. Parodi, A. Petit, C. Pfeiffer, P. Quaglino, A. Ranki, J. Sanchez, J. Seneschal, A. Skrok, M. Sticherling, G. Strauss, C. Sunderkötter, A. Taieb, A. Tanew, F. Trautinger, P. Wolf, M. Worm, N.J. Wutte

Disclosures:

R. Knobler:

P. Moinzadeh:

A. Cozzio:

M. Cutolo has received funds for research (to University of Genova) from Actelion, BMS, Horizon, and Mundipharma.

C. Denton has received consulting and speaker fees from Actelion, GSK, Bayer, Roche, Inventiva and research funds from Actelion, Roche and CSL Behring.

L. Frasin:

A. Gabrielli:

N. Hunzelmann:

A. Kreuter has no disclosures to declare.

L. Mouthon:

F. Ronglioletti:

L. Rudnicka:

V. Smith is Senior Clinical Investigator of the Research Foundation – Flanders (Belgium) (FWO). She also has consultancy relationships and/or has received research funding and/or speaker fees from Actelion Pharmaceuticals Ltd., Boehringer Ingelheim, Roche/Genentech, Galapagos NV, and Merck Sharp & Dohme.

T. Krieg:

Table of Contents

List of abbreviations.....	6
I Localized scleroderma (morphea).....	7
Introduction	7
Epidemiology.....	7
Pathogenesis	7
Potential trigger factors of localized scleroderma.....	8
Clinical classification.....	8
Association with other autoimmune diseases	11
Clinical course, disease activity, and recurrence rates.....	12
Diagnostic procedures	12
Laboratory parameters	12
Histopathology of localized scleroderma.....	13
Clinical scores	13
Radiologic examination	14
Technical outcome measures	14
Differential diagnoses.....	15
Specifics of juvenile localized scleroderma.....	15
Treatment.....	16
Topical therapy	16
Systemic therapy	18
UV phototherapy.....	20
Physiotherapy.....	22
Surgical therapy	22
References	27
II Scleromyxedema	36
Introduction	36
Epidemiology.....	36
Pathogenesis	36
Clinical manifestation.....	36
Cutaneous manifestations	37
Extracutaneous manifestations.....	37
Associated disorders	39
Clinical course	39
Diagnostic procedures	40
Histopathology.....	40
Differential diagnosis	41
Scleroderma	41
Scleredema.....	41
Nephrogenic systemic fibrosis/dermopathy.....	41
Localized lichen myxedematosus	41
Treatment.....	42
First-line therapy	42
Second-line therapies	44
Prognosis and follow-up.....	47
Summary and recommendations	47
References	51
III Systemic sclerosis	55
Introduction	55
Clinical manifestation and classification.....	56
Diagnostic procedures	57

Antinuclear antibodies	57
Capillaroscopy	57
Organ involvement and diagnostic work-up	57
Raynaud's phenomenon	57
Skin fibrosis	58
Digital ulceration	58
Calcinosis cutis	59
Musculoskeletal system	59
Pulmonary involvement	60
Gastrointestinal involvement	61
Cardiac involvement	61
Renal involvement	61
General recommendation for a regular diagnostic work-up in patients with SSc	62
Treatment	62
Therapy for skin involvement	62
Therapy for musculoskeletal involvement	66
Therapy for pulmonary involvement	66
Therapy for gastrointestinal involvement	67
Therapy for renal involvement	67
General recommendations for disease management	68
References	78
IV Nephrogenic systemic fibrosis	84
Definition	84
Epidemiology	84
Pathogenesis	84
Clinical manifestation	85
Diagnostic procedures	85
Treatment	86
Conclusions	86
References	90
V Systemic sclerosis overlap syndromes	93
Introduction	93
Epidemiology	93
Pathogenesis	94
Clinical manifestations	94
Raynaud's phenomenon	94
Skin sclerosis	95
Calcinosis cutis	95
Gastrointestinal involvement	95
Lung fibrosis and myocardial involvement	95
Pulmonary arterial hypertension	95
Clinical characteristics of systemic sclerosis overlap syndromes	95
Systemic sclerosis and myositis	95
Systemic sclerosis and rheumatoid arthritis	96
Systemic sclerosis and systemic lupus erythematosus	96
Systemic sclerosis and Sjögren's syndrome	97
Mixed connective tissue disease	97
Diagnostic procedures	98
Muscle involvement (myositis/myopathy)	98
Sjögren's symptoms	98
Joint involvement	98

Kidney involvement.....	98
Treatment.....	99
Systemic glucocorticoids	99
Methotrexate	99
Mycophenolat mofetil.....	99
Azathioprine.....	99
Cyclophosphamide.....	99
Bioimmunomodulatory agents	100
Therapeutic approaches	100
Systemic sclerosis and myositis.....	100
Systemic sclerosis and rheumatoid arthritis.....	100
Systemic sclerosis and systemic lupus erythematosus.....	100
Mixed connective tissue disease	101
Systemic sclerosis and Sjögren's overlap syndrome	101
References	107
VI Scleredema	111
Introduction	111
Epidemiology.....	111
Pathogenesis	112
Clinical manifestations	112
Cutaneous manifestations	112
Extracutaneous manifestations.....	112
Associated disorders	113
Clinical course	114
Diagnostic procedures	114
Histopathology.....	115
Diagnostic criteria	115
Patient history	115
Physical examination	116
Skin biopsy.....	116
Complementary investigations.....	116
Additional tests	117
Differential diagnosis.....	117
Treatment.....	119
Prognosis and follow-up.....	120
Summary and recommendation	121
References	125

List of abbreviations

ACA	Anti-centromere antibodies
ACE	Angiotensin-converting enzyme
ACR	American College of Rheumatology
ANA	Antinuclear antibodies
CARRA	Childhood Arthritis and Rheumatology Research Alliance
CCP	Cyclic citrullinated peptide
CLASI	Cutaneous Lupus Erythematosus Activity and Severity Index
CNS	Central nervous system
CRP	C-reactive protein
DLCO	Diffusing capacity of the lungs for carbon monoxide
DLQI	Dermatology Life Quality Index
DU	Digital ulceration
ECG	Electrocardiogram
EDF	European Dermatology Forum
EMA	European Medicines Agency
ESR	Erythrocyte sedimentation rate
EULAR	European League Against Rheumatism
FDA	Food and Drug Administration
FVC	Forced vital capacity
GBCA	Gadolinium-based contrast agents
GFR	Glomerular filtration rate
HR-CT	High-resolution computed tomography
ILD	Interstitial lung disease
IVIg	Intravenous immunoglobulin
LFT	Lung function test
LoSCAT	Localized Scleroderma Cutaneous Assessment Tool
LoSDI	Modified Localized Scleroderma Skin Severity Index
LS	Localized scleroderma
MCTD	Mixed connective tissue disease
mLoSSI	Modified Localized Scleroderma Skin Severity Index
MMF	Mycophenolate mofetil
MMP	Matrix metalloproteinases
MRI	Magnetic resonance imaging
mRSS	Modified Rodnan Skin Score
NFD	Nephrogenic fibrosing dermopathy
NSF	Nephrogenic systemic fibrosis
PAH	Pulmonary arterial hypertension
PCR	polymerase chain reaction
PDE	Phosphodiesterase
PUVA	Psoralen combined with UVA
PGA	Physician's Global Assessment
RSS	Rodnan Skin Score
SSc	Systemic sclerosis
SLE	Systemic lupus erythematosus
TGF	Transforming growth factor
TNF	Tumor necrosis factor
UV	Ultraviolet

I Localized scleroderma (morphea)

Introduction

Localized scleroderma (LS) comprises a spectrum of sclerotic diseases that primarily affect the skin. Depending on the respective subtype, LS can also involve adjacent tissues such as the fat, fascia, muscle and bone.¹ Debate continues as to whether the term “localized scleroderma” or “morphea” should be used for the disease because “localized scleroderma” or “circumscribed scleroderma” might be confused with “systemic scleroderma”, resulting in unnecessary patient concern. However, this will change over time because consensus has been reached to abandon systemic scleroderma for the term “systemic sclerosis”.² Nevertheless, especially in Europe, the term LS is used as a heading for the whole spectrum of subtypes, whereas morphea is mainly used for the plaque type of the disease. In contrast to systemic sclerosis, LS does not affect internal organs such as the lungs, heart, kidneys or gastrointestinal tract. Although LS and systemic sclerosis (SSc) share similar pathogenetic pathways, both diseases rarely coexist, and transition from LS to SSc does not occur.

Epidemiology

LS is a rare disease that seems to be most frequent in white individuals, but may affect people of all ethnic backgrounds.³⁻⁵ To date, only a few adequate epidemiologic studies on LS have been conducted, with incidence ranging from 0.4 to 2.7 per 100.000 people.^{6,7} LS occurs more often in women than men, at a ratio of 2.6–6 to 1.⁸ The disease may manifest at all ages, but the peak age of incidence differs depending on the LS subtype. The most frequent subtype of LS (morphea) usually appears in adults between 40 and 50 years of age, whereas linear subtypes primarily present in childhood between 2 and 14 years of age.³ Other, rarer subtypes of LS have a peak incidence in the third and fourth decade of life.

Pathogenesis

The hallmark feature of LS is overproduction of collagen and increased extracellular matrix deposition. Its exact initiation remains unknown. It has been hypothesized that certain stimuli, for example infections, trauma, radiation, or drugs, might cause microvascular injuries and induce T cell activation that subsequently result in a release of various adhesion molecules.³ Up-regulation of some of these adhesion molecules (e.g. vascular cell adhesion molecule-1 and intercellular adhesion molecule-1) might induce T cell activation, which, in turn, activates the

release of key player pro-fibrotic cytokines, such as transforming growth factor-beta (TGF β) and its signal transducers called SMAD proteins, platelet-derived growth factor, connective tissues growth factor, and interleukin 4, 6, and 8.⁹⁻¹² This pro-fibrotic pathway additionally includes a spectrum of chemokines that significantly contribute to skin sclerosis.^{13,14} Ultimately, and similarly to SSc, activation of all of these pro-inflammatory and pro-fibrotic signals leads to excessive collagen production and decrease of matrix metalloproteinases (MMP) responsible for collagen degradation.¹⁵

Potential trigger factors of localized scleroderma

Although much is known about the early inflammatory phase and the molecular mechanisms involved in the fibroblastic reaction of LS, little is known about the potential triggers of the disease. Among infectious agents, *Borrelia* organisms have been extensively studied on both sides of the Atlantic. Whereas high rates of *Borrelia* infections, some of which were detected using highly sensitive new detection techniques such as focus-floating microscopy, have been reported in LS patients from Europe, a variety of studies based on polymerase chain reaction (PCR) from northern Europe or from the United States failed to demonstrate an association.¹⁶⁻¹⁸ Thus, the pathogenetic role of *Borrelia* in LS remains unclear. Among the drugs that have been reported to induce LS, most evidence exists for bleomycin, D-penicillamine, vitamin K1, and L-5-hydroxytryptophane plus carbidopa. Recently, balicatib, an inhibitor of the osteoclastic enzyme cathepsin K used for osteoporosis, has been reported to induce LS.¹⁹ Few reports exist on radiation-induced LS, which primarily occurs in women with breast cancer.^{20,21} Clinically, radiation-induced LS might be indistinguishable from chronic radiodermatitis, but histopathologic analysis usually discerns both conditions. Finally, among the triggers of LS, mechanical injuries and traumata have been reported in case series and large cohort studies, with the highest association in facial subtypes of childhood LS.^{4,5,22}

Clinical manifestation

Clinical classification

To date, no uniformly accepted classification for LS exists. A widely accepted classification was published in 1995 that distinguishes plaque, generalized, deep, bullous, and linear types as the five main groups of LS.²³ However, this classification raises some concerns. First, it includes diseases that are not uniformly accepted to belong to the LS spectrum, such as extragenital lichen sclerosus. Secondly, bullous lesions can appear in all different LS subtypes due to the characteristic subepidermal edema and damage of the basement membrane zone.

Thirdly, there are patients, especially children, who present with more than one subtype of LS. Thus, an alternative classification scheme was published in 2006 to overcome these weaknesses.²⁴ A German group of experts proposed a classification (Table 1) that considers the extent and depth of fibrosis, and refers to the treatment of the respective subtypes.¹

<TABLE 1>

Limited types of LS

Plaque-morphea (the classical plaque type of LS) is the most frequent subtype of LS, especially in adults. In the early active phase, plaque-morphea usually presents with oval-shaped lesions surrounded by an erythematous border (the so-called “lilac ring”). In the later stage of disease, morphea lesions become hard and sclerotic in the center, with a whitish or ivory color. Older lesions may also become atrophic, hypo-, or hyperpigmented and, depending on the location of fibrosis, may also lead to hair loss and loss of the skin appendages. Plaque-morphea is frequently located on the trunk, especially the submammary region, the transitional area between the hip and inguinal regions or in areas with repeated trauma such as pressure from clothing.

Guttate morphea is a rare subtype of morphea that presents with multiple yellowish or whitish, small sclerotic lesions with a shiny surface. Guttate morphea is predominantly located on the trunk. Early inflammatory lesions may simply present as erythematous maculae. Clinically and histopathologically, guttate morphea might be difficult to distinguish from extragenital lichen sclerosis.

Atrophoderma of Pasini and Pierini is possibly an early abortive type of morphea. The recently described term “superficial morphea” seems to be synonymous with atrophoderma of Pasini and Pierini.^{25,26} The clinical presentation of this subtype of LS, which frequently manifests in childhood, is characterized by symmetrical, single or multiple, sharply demarcated, hyperpigmented, non-indurated patches that are located on the trunk or extremities.

Generalized types of LS

Generalized localized scleroderma is a more severe variant of LS. According to Laxer and Zulian, generalized localized scleroderma is defined as the presence of four or more indurated plaques of more than 3 cm in diameter, involving at least two of the seven anatomic sites (head-

neck, each extremity, anterior trunk, and posterior trunk).²⁴ The trunk is commonly affected and skin lesions are often distributed symmetrically and tend to coalesce.

A unique and very rare variant of the generalized type of LS is “disabling pansclerotic morphea.” Disabling pansclerotic morphea, predominantly occurring in childhood, and may lead to extensive involvement of the skin, fat tissue, fascia, muscle, and bone, with only limited tendency of fibrosis to regress. Disabling pansclerotic morphea often results in severe contractures and poorly healing, large ulcerations and skin necroses.

Linear types of LS

Linear localized scleroderma is the most common subtype of LS in childhood. Linear LS is characterized by longitudinally arranged linear, band-like lesions that are predominantly located on the extremities. Evidence indicates that linear LS may follow the lines of Blaschko.²⁷ In mild disease, the lesions may heal with residual hyperpigmentation. However, depending on the extent of the fibrotic process, linear LS may lead to severe growth retardation, muscle atrophy, flexion contractures, myositis and myalgia, arthritis and arthralgia, and psychologic disability.

LS “en coup de sabre” is a subtype located on the frontoparietal region of the head, usually ranging paramedian from the eyebrows into the hair-bearing scalp where it might cause scarring alopecia. Involvement of the underlying central nervous system (CNS; e.g. seizures, migraine, and headache) and abnormal ophthalmologic findings (e.g. uveitis) can occur.

Several authors have speculated that progressive facial hemiatrophy (also called Parry–Romberg syndrome) and LS “en coup de sabre” are variants of the same condition.^{1,5,28,29} Progressive facial hemiatrophy is clinically characterized by a primary atrophy of the subcutaneous tissue, muscle, and bone. Skin fibrosis is usually absent. It often occurs in childhood or adolescence, and may result in severe facial asymmetry. Occurrence of simultaneous linear LS “en coup de sabre” and progressive facial hemiatrophy is quite frequent, with a reported coincidence of up to 40%.³⁰ In the classification proposed in this article, progressive facial hemiatrophy is listed under the linear subtypes of LS (Table 1), although with exclusive involvement of extracutaneous structures it may also be classified as a “deep subtype” of LS.

Deep type of LS

The deep type of LS (also called deep morphea) is the rarest variant, affecting less than 5% of patients. In deep morphea, the fibrotic process mainly affects the deeper layers of the connective tissue (i.e. fat tissue, fascia, and underlying muscle). Deep morphea lesions are typically arranged symmetrically and predominantly located on the extremities.

Mixed type of LS

Mixed types of LS predominantly affect children, occurring in up to 15% of patients with juvenile LS. Mixed types often consist of linear LS and morphea (plaques type of LS) or a combination of linear and generalized LS.⁵

Eosinophilic fasciitis

Eosinophilic fasciitis (or Shulman syndrome) is considered by many experts to be a special subtype belonging to the spectrum of LS.¹ A mechanical trauma often precedes the first manifestation of the disease. Clinically, eosinophilic fasciitis predominantly affects the extremities and presents with a rapid onset of symmetrical swelling of the skin. In the later stage of disease, lesions become more indurated and fibrotic, leading to the typical “peau d’orange” like appearance. A distinctive clinical finding in later stages of eosinophilic fasciitis is that cutaneous veins might appear depressed compared with the surrounding tissue (called “negative vein sign”).

Association with other autoimmune diseases

Several reports of familiar clustering and increased rates of other autoimmune diseases (e.g. Hashimoto thyroiditis, alopecia areata, vitiligo, and type-1 diabetes) in patients with LS suggest a possible genetic component.⁵ However, in contrast to SSc, susceptibility genes for LS are still unknown. In a study including 245 patients with LS, 17.6% had other rheumatic or autoimmune diseases. This rate is four times higher than in the general population. Patients with generalized LS had the highest rate of associated autoimmune diseases (45.9%).³¹ Another study that retrospectively evaluated 472 patients with LS for other autoimmune diseases found other autoimmune diseases in 8.1%.³²

Some decades ago, the coexistence of LS and lichen sclerosis (predominantly extragenital) was reported in several case reports and small case series.^{33,34} In 2012, a prospective study from France including 76 patients with LS showed that 38% of them had concomitant genital lichen

sclerosus; mostly patients with limited LS (morphea) and generalized LS were affected. This high rate of genital lichen sclerosus in patients with LS was later confirmed by a larger retrospective German study.³⁵

Clinical course, disease activity, and recurrence rates

To date, only limited data are available on the long-term clinical course of LS. A recent retrospective analysis including 344 patients with adult or juvenile LS from the Netherlands demonstrated that about one quarter of the patients experienced a reactivation of disease. Univariate analysis demonstrated that the age at onset of disease was a risk factor for recurrent disease; relapses occurred significantly more often in pediatric LS (27%) compared with adult disease (17%). Moreover, disease subtype was another risk factor; 37% of patients with linear LS of the limbs (either solitary or as part of mixed type of LS) experienced a relapse, whereas recurrences in the other subtypes occurred less frequently (17%). The two most frequent subtypes in adults (morphea/plaque type and generalized LS) had recurrence rates of 16% and 25%, respectively. Importantly, this study also showed that disease relapses can occur after years of quiescent disease; the median time between disease remission and first recurrence was 26 months in juvenile and 27 months in adult LS, respectively.³⁶ In the study of Saxton-Daniels et al. regarding long-term outcome of pediatric cases, 89% of the pediatric onset cases developed new or expanded lesion over time.³⁷ Time to recurrence of activity ranged from 6 to 18 years from initial disease onset.

Diagnostic procedures

Laboratory parameters

Depending on the clinical subtype, a high incidence of autoimmune phenomena has been reported in LS patients (e.g. serum antinuclear antibodies, most of them with a homogenous pattern).^{4,31,38} Moreover, active childhood LS might be associated with anti-histone antibodies, hypergammaglobulinemia, and eosinophilia.³⁹ In patients with linear LS of the extremities with concomitant joint involvement, increased levels of rheumatoid factor may be present, and do sometimes correlate with the clinical degree of arthritis activity.⁴⁰ Several other antibodies (e.g. anti-topoisomerase II alpha, anti-U1-small-nuclear-ribonucleoprotein, and anti-U3-small-nuclear-ribonucleo-protein), and anti-MMP antibodies have been evaluated in LS, but their specific role remains to be elucidated.⁴¹⁻⁴³

In daily practice, blood screening in patients with LS who are considered for systemic therapy should include blood differential and serum chemistry (Table 2). Routine screening for antinuclear antibodies is not recommended. Additional diagnostics (e.g. screening for antibodies against extractable nuclear antigens) should be only performed to confirm or exclude systemic sclerosis.

Controversy exists about the pathogenetic role of *Borrelia burgdorferi* in LS (see *Potential trigger factors of LS*, above). Accordingly, a general blood screening for *Borrelia* in patients with LS is not generally recommended and should only be performed in clinically suspicious cases.

<TABLE 2>

Histopathology of localized scleroderma

LS and SSc share the same histopathologic features. Thus, by histopathology, it is neither possible to distinguish between LS and SSc nor to differentiate among different LS subtypes. In general, two phases of LS can be recognized, an early inflammatory and a late fibrotic stage.^{1,44} Early skin lesions of LS are characterized by thickened collagen bundles within the reticular dermis that run parallel to the skin surface, and by the presence of dense inflammatory infiltrates between the collagen bundles, and around blood vessels and sweat glands. Lymphocytes predominate the inflammatory infiltrates, but plasma cells, histiocytes, and eosinophilic granulocytes might be present as well. The overlying epidermis might be either unaffected or thin and atrophic. In the late fibrotic stage, the lesional skin becomes relatively avascular, and often there is only little evidence of ongoing inflammation. Late lesions usually contain collagen fibers that are tightly packed and highly eosinophilic. Sweat glands are atrophic or absent. Collagen may replace fat cells in the subcutaneous tissue. Physicians should ensure that the biopsy excision is sufficiently deep as some LS subtypes may primarily involve the subcutis or underlying fascia and muscle.

Clinical scores

Due to the difficulties of defining clinical improvement in LS, clinical scores were not available for a long period of time. The Rodnan Skin Score (RSS) and its later revised version (the so-called “modified RSS) are validated and widely used clinical tools in SSc.⁴⁵ Both of these scores are inappropriate for the measurement of LS skin involvement due to the overweight of certain

anatomic areas (e.g. face), which are usually spared in LS. In 2009, the first validated skin score for LS, called the modified Localized Scleroderma Skin Severity Index (mLoSSI) was introduced. This score evaluates erythema, skin thickness and development of new skin lesions or lesional extension in 18 anatomic regions, and has demonstrated a high interrater agreement.⁴⁶ The same group of researchers later introduced a score for skin damage in LS, called the Localized Scleroderma Skin Damage Index (LoSDI).⁴⁷ Consequently, it was recommended to combine the mLoSSI, LoSDI, and the Physician's Global Assessment (PGA) to measure both activity and damage in LS. This composes the Localized Scleroderma Cutaneous Assessment Tool (LoSCAT), a combined score that is modeled after a well established tool for cutaneous lupus erythematosus, the Cutaneous Lupus Erythematosus Activity and Severity Index (CLASI). LoSCAT, which is similar to the CLASI, could become a standard tool to evaluate skin affection in LS.

Patient quality of life can be evaluated with the Dermatology Life Quality Index (DLQI) or the Hospital Anxiety and Depression Scale.

Radiologic examination

Morphea, the most common LS subtype in adults, usually affects the skin only and therefore does not require further radiologic examination. In contrast, patients with LS “en coup de sabre” and progressive facial hemiatrophy often suffer from neurologic symptoms (e.g. migraine, headache, and epilepsy). In these cases, cranial magnetic resonance imaging (MRI) should be considered to detect potential involvement of the CNS because subcortical calcifications and brain atrophy are common.^{4,22} In special cases ophthalmologists or oral surgeons should be consulted about abnormalities that have to be corrected. Despite such abnormalities of the CNS, many patients are asymptomatic. In addition, MRI and computed tomography studies might be helpful for surgical planning (e.g. in LS “en coup de sabre” type), and to detect muscle, joint or bone involvement, for instance in linear LS of the extremities. MRI should be considered in cases with linear LS of the extremities that might have concomitant arthritis.

Technical outcome measures

A variety of technical procedures have been reported in clinical trials on LS, for example, ultrasound scanning, cutometer, durometer, thermography, laser Doppler flowmetry, and a computerized skin score. In most of the studies, these procedures were used as secondary outcome measures.

Differential diagnoses

A variety of differential diagnoses should be considered in LS.⁴⁸ In daily routine, the physicians' pivotal challenge is to differentiate LS from SSc.³ Typical facial (e.g. telangiectasia, beak-shaped nose, and microstomia) and vascular (e.g. Raynaud's phenomenon, pitting scars, and digital ulcers) features of SSc, as well as highly specific serum antibodies (e.g. anti-centromere antibodies and anti-Scl-70 antibodies) are absent in LS.⁴⁴

The most relevant differential diagnoses for limited LS (morphea) are extragenital lichen sclerosus and acrodermatitis chronica atrophicans, for generalized LS chronic graft versus host disease, SSc, and nephrogenic systemic fibrosis, and for linear LS lupus erythematosus profundus and other types of panniculitis. All differential diagnoses with respect to LS subtypes and stage of disease are summarized in Table 3.

<TABLE 3>

Specifics of juvenile localized scleroderma

Whereas limited types of LS most commonly occur in adults, linear subtypes predominate in children. A study including 65 patients with juvenile LS revealed that linear subtypes may follow the lines of Blaschko. It was hypothesized that in linear LS, susceptible cells are present in a mosaic state and that exposure to some trigger factors finally result in the initiation of disease.²⁷ Clinical course of disease is often more severe in juvenile LS compared with adult linear LS, and may lead to considerable atrophy of the skin, fat tissue, fascia, and muscle. This might finally result in substantial functional, physical, and mental disability. It has been shown that 30–50% of patients with linear LS experience osteoarticular complications (e.g. arthritis) on the affected extremity.^{49–51} Both linear LS “en coup de sabre” and progressive facial hemiatrophy mainly occur in childhood. It seems that both conditions belong to the same spectrum of disease, with overlapping clinical features. In contrast to other subtypes of LS, linear LS “en coup de sabre” and progressive facial hemiatrophy have a more insidious clinical course, and the active stage of disease persists usually longer than in other subtypes of LS. Neurologic symptoms are frequent and may include epileptic seizures, neuropsychiatric symptoms, headaches, and mental or behavioral disorders.^{28,52,53} Ophthalmologic changes are common in juvenile LS and might manifest as uveitis, dysfunction of the eye muscles, and loss of eyebrows or eyelashes.

“Disabling pansclerotic morphea,” a rare subtype of generalized LS, usually manifests before the age of 14, and is obligatorily associated with affection of extracutaneous structures. It frequently results in disturbance of growth and cachexia.

Abnormal blood findings are frequent in juvenile LS. In the active stage of generalized LS, blood eosinophilia is frequent. Moreover, an elevated rheumatoid factor, increased blood sedimentation rate, hypergammaglobulinemia (increased IgA and IgM in active stages of LS and increased IgG in severe disease with contractures), as well as elevated antinuclear, anti-histone, and single-stranded DNA antibodies might be present.⁵⁴

In order to prevent persistent damage, effective systemic therapy should be initiated in the active stage of all linear types of juvenile LS as early as possible. Similarly to adult LS, subtype and extent of disease have an influence on the respective therapy. Concomitant physiotherapy should be considered in subtypes with (potential) restriction of motion. Surgical interventions should only be performed in the inactive stage of disease.⁵⁵ The same is true for aesthetic-reconstructive interventions in linear LS “en coup de sabre” and progressive facial hemiatrophy.

Treatment

Although no causal treatment for LS exists, a variety of therapeutic options are available, especially for the active phase of disease. In general, treatment options for LS might be divided into topical and systemic therapy as well as ultraviolet (UV) phototherapy. The extent and severity of LS should be taken into account before initiating the respective therapy. For example, topical and UV phototherapy are usually appropriate in limited types of LS that are restricted to the skin, whereas generalized, linear or deep types usually require systemic treatment. Hereafter, all treatment options that have been reported for LS are summarized. Moreover, a treatment algorithm is provided that incorporates the subtype, severity, and extent of LS (Fig. 1). When evaluating the treatment efficacy it should be remembered that reduction of skin sclerosis starts 8–12 weeks after initiation of therapy, at the earliest. None of the therapies mentioned below are officially licensed in Europe.

<FIG. 1>

Topical therapy

Topical glucocorticoids

Although no well-performed studies exist on the use of topical glucocorticoids, they are the mainstay of topical treatment in LS. Therapy with moderate-to-high potent glucocorticoids should be performed in the active phase of disease, and their application should be restricted to a total of 3 months. Longer application of topical glucocorticoids should be given as interval therapy. In order to increase the efficacy, an application under occlusion might be considered. Intralesional glucocorticoid therapy might be performed in LS “en coup de sabre,” with injections into the active margin.

Topical calcipotriol

To date, two uncontrolled studies have been conducted on the use of topical calcipotriol in LS, one of which administered calcipotriol 0.005% along with low-dose UVA1 phototherapy.⁵⁶ In both studies, administration was performed twice daily. In the monotherapy study, calcipotriol 0.005% was applied under occlusion.⁵⁷

Calcipotriol 0.005% should be considered for active inflammatory superficial types of LS with a low degree of sclerosis. Treatment should be performed twice daily (under occlusion) for a minimum of 3 months.

Topical calcineurin inhibitors

Following two open studies on topical tacrolimus 0.1% ointment in LS, a recent double-blind, placebo (petroleum emollient)-controlled pilot study has shown that topical tacrolimus significantly improves LS.^{58–60} Outcome measures in this study were the changes of surface area, a clinical score for erythema, induration, dyspigmentation, telangiectasia, atrophy, and a durometer score.⁵⁸ Early inflammatory lesions resolved and late sclerotic lesions softened, whereas no effects were seen on pre-existing skin atrophy.

Thus, tacrolimus ointment might be an effective treatment option for active LS lesions. To date, no studies on pimecrolimus for LS have been conducted.

Imiquimod

In case reports and small case series, the topical immune response modifier imiquimod has been reported to significantly improve abnormal pigmentation, sclerosis, and erythema in LS.^{61–63}

The mechanism of imiquimod action in LS might be explained by induction of interferon- γ which inhibits TGF- β , thereby possibly exhibiting a broad anti-fibrotic effect.

However, based on these small case series, imiquimod cannot be recommended for LS until more valid data are available.

Intralesional interferon- γ

A double-blinded, placebo-controlled trial demonstrated no significant improvement of intralesional interferon- γ compared with the placebo group. Accordingly, intralesional interferon- γ cannot be recommended for the treatment of LS.⁶⁴

Systemic therapy

Systemic glucocorticoids

Similarly to topical glucocorticoids, there is a paucity of data on systemic glucocorticoids, although they are widely used agents in LS, particularly in linear, generalized, and deep subtypes. In the only published uncontrolled study on 17 patients with LS (glucocorticoid dosage: 0.5–1.0 mg/kg body weight daily), a marked improvement was noticed in nearly all of the patients.⁶⁵ However, about one third of patients experienced recurrences after finishing therapy. Systemic glucocorticoids are safe and effective in active lesions of LS, and should be considered in patients with severe disease, especially in those forms affecting extracutaneous structures (e.g. fat tissue, fascia, muscle, and bone). Moreover, systemic glucocorticoids are the first-line treatment option in eosinophilic fasciitis.⁶⁶ Treatment should be planned for a sufficient duration, as clinical effects are sometimes seen at the earliest 3 months after onset.

Methotrexate

Among systemic treatment of LS, best evidence exists for the use of methotrexate. To date, one placebo-controlled multi-center trial, as well as three prospective and four retrospective studies have been published.^{49,67–73} In the placebo-controlled study, a total of 70 children with active LS (46 patients in the methotrexate group and 24 in the placebo group) were included to receive methotrexate orally (15 mg/m², maximum 20 mg) or placebo. Moreover, oral prednisone (1 mg/kg/day, maximum 50 mg) was added in both arms for 3 months. The computerized scoring system, as well as infrared thermography were used as outcome measures. In both arms, a reduction of the clinical score was observed within the first 6 months. However, at the end of

the study at month 12, a significant decrease of the clinical score as well as infrared thermography was only observed in the methotrexate group.⁶⁷

In the three prospective studies that included 34 patients (24 adults and 10 children), a combination of high-dosage intravenous methylprednisolone and methotrexate (adults 15 mg/weeks; children 0.3 mg /kg/week) was used, and outcome measures were a non-validated clinical score and ultrasound scanning. All adults and nine of the 10 children experienced a significant improvement under therapy.^{49,68,69} In the four retrospective studies, a total of 119 patients were included (52 patients with methotrexate monotherapy and 67 patients with a combination of methotrexate and systemic glucocorticoids). In 97% of patients, a clinical improvement was observed.⁷⁰⁻⁷³ Importantly, it was shown in another study that 28% of patients with juvenile LS experienced a relapse after treatment with methotrexate.⁷⁴

In the studies mentioned above, different dosages of methotrexate and systemic glucocorticoids were used. In 2012, the “Childhood Arthritis and Rheumatology Research Alliance” (CARRA) recommended three different treatment regimens for juvenile LS: 1) methotrexate monotherapy; 2) pulse methotrexate and glucocorticoid therapy with methylprednisolone given intravenously; 3) pulse methotrexate and glucocorticoid therapy with prednisone given orally.⁷⁵ These recommendations have been incorporated in the treatment algorithm (Fig. 1) of this guideline.

Mycophenolate mofetil

In 2009, a small case series of seven methotrexate-resistant LS patients treated with mycophenolate mofetil (MMF) showed improvement of skin sclerosis and inflammation, as documented with infrared thermography and clinical scoring.^{76,77} *In vitro* studies have shown that MMF inhibits the proliferation of lymphocytes, but also of other cell types, including smooth muscle cells and fibroblasts, indicating that it has direct anti-fibrotic properties in addition to its well-known immunosuppressive effects.⁷⁸ These preliminary observations make MMF an interesting new candidate for further clinical studies. According to CARRA, MMF should be considered as a second-line therapy if methotrexate has failed. It is noteworthy that in several countries (e.g. Germany) health insurers sometimes deny re-imburement for this off-label use.

Calcitriol

A randomized controlled study that included 20 patients with LS demonstrated that a 9-month therapy with oral calcitriol (0.75 µg/daily for 6 months, followed by 1.25 µg/daily for 3 months) failed to achieve any significant improvement compared with placebo.⁷⁹ Therefore, oral calcitriol cannot be recommended for LS.

D-penicillamine

Although the efficacy of D-penicillamine has been reported in a small case series of LS patients, no significant differences were found between high-dose (750–1000 mg daily) and low-dose therapy (125 mg daily) in SSc.^{80,81} Given the poor evidence level of efficacy and the problematic side-effect profile of D-penicillamine, it cannot be recommended for the treatment of LS.

Penicillin

For decades penicillin has been used for the treatment of LS because LS can manifest after an infection with *Borrelia*. Although penicillin has anti-inflammatory properties, direct anti-fibrotic effects have so far not been demonstrated. Accordingly, the efficacy of penicillin in LS remains unproven.

Miscellaneous

Numerous other systemic therapies have been used in cases of LS, including cyclosporine, azathioprine, chloroquine and hydroxychloroquine, phenytoin, colchicine, retinoids, extracorporeal photopheresis, plasmapheresis, intravenous immunoglobulin, abatacept, infliximab, rituximab, and imatinib.^{82–87} These treatments should be reserved for single severe cases with contraindications or failure to standard therapy.

UV phototherapy

Within the last two decades, the vast majority of clinical studies on LS came from the field of photodermatology.⁸⁸ One of the rationales for using UV phototherapy in sclerotic skin diseases is the fact that UV can induce interstitial MMP.^{89,90} The first experience of the successful use of UV phototherapy in LS was in 1994.⁹¹ Since then, much information has been gained on the entire spectrum of anti-fibrotic and anti-inflammatory effects of UV phototherapy in skin sclerosis.⁹² In addition, UV phototherapy leads to apoptosis of dermal T cells, depletion of Langerhans cells, and to modulation of several pro-inflammatory cytokines.⁸⁸ The exact mechanism of action of UV therapy in sclerotic skin diseases remain to be determined. Because

longer wavelengths in the UVA range (320–400 nm) penetrate deeper into the dermis compared with UVB (280–320 nm), most studies have focused on UVA. Before initiating UV phototherapy in LS, it should be considered that UV rays only penetrate into the deep dermis. Therefore, UV phototherapy (in combination with topical treatment, e.g. topical glucocorticoids or topical vitamin D analogs) is an effective treatment option for limited disease restricted to the skin, but not in LS subtypes affecting deeper structures (e.g. fat tissue, fascia, muscle, or bone). Such subtypes require systemic therapy. However, it is also known that UV can act indirectly by modulating cytokine release in keratinocytes.

UV irradiation has a major role in the pathogenesis of skin cancer due to its capacity to induce immunosuppression and DNA damage. However, the dosages and duration of UVA irradiation used in the treatment of sclerotic skin diseases are most likely too low to induce any significant skin damage, though there may be an absolute safe threshold dose.⁹³

PUVA phototherapy

In order to avoid the well-known side effects of oral application of 8-methoxypsoralen, psoralen combined with UVA (PUVA) was mainly applied in LS as bath PUVA phototherapy. Besides several case reports, two retrospective case series exist on bath PUVA phototherapy.^{94,95} In the larger study published in 2013, 28 patients were treated with bath PUVA three times per week. In 39% of patients, a complete clearance of all lesions was observed, 50% experienced clinical improvement, and 10% had no response.⁹⁵ Moreover, a small case series of four patients treated with cream PUVA phototherapy showed similar encouraging results.⁹⁶ PUVA phototherapy is usually performed 2–3 times per week for a total of 30 irradiations.

Broadband UVA

Three prospective studies have been published on the use of broadband UVA (320–400 nm) in LS. Among those, the largest study included 63 patients.^{97–99} The three dosages used in this study (5, 10, and 20 J/cm² for a total of 20 irradiations each) showed similar efficacy. Controlled studies comparing broadband-UVA with other UV modalities are lacking.

UVA1 phototherapy

In the area of phototherapy, the most robust data exist for UVA1. Three different dosages of UVA1 can be distinguished: low-dose UVA1 (10–29 J/cm²), medium-dose UVA1 (30–59 J/cm²), and high-dose UVA1 (60–130 J/cm²). All regimens have been used in LS, and the

first report was published in 1991.¹⁰⁰ The first prospective study on UVA1 phototherapy in LS demonstrated that high-dose UVA1 is highly effective, but low-dose UVA1 failed to show any substantial effects in LS.¹⁰¹ Nevertheless, several prospective studies performed some years later showed that low-dose and medium-dose UVA1 are effective as well.^{56,102–108} To date, only one randomized controlled study has been performed that compared low-dose UVA1, medium-dose UVA1, and narrow-band UVB phototherapy in a collective of 64 LS patients. All three UV regimens significantly improved the skin scores, with medium-dose UVA1 being significantly better than narrow-band UVB.¹⁰⁹ Whether patients with darker skin respond less to UVA1 phototherapy is still a matter of debate.^{110,111} Moreover, it has been shown that within 3 years, about 50% of patients treated with UVA1 experience recurrences after therapy.¹¹² In these cases, a second cycle of UVA1 phototherapy should be considered. UVA1 is usually performed 3–5 times per week for a minimum of 30 irradiations.

Physiotherapy

Studies on physiotherapy in LS are lacking. Nevertheless, physiotherapy is an important component in the multimodal treatment concept for LS, and is frequently performed in daily practice. In particular, linear, generalized, deep, and mixed types of LS should be treated with physiotherapy. It should not be performed in the active, inflammatory stage of disease. Massage and lymphatic drainage can be added to systemic therapy in patients with sclerotic stage disease. Physiotherapy is usually performed once or twice per week for at least 3 months.

Surgical therapy

Surgical therapy is predominantly indicated in linear types of LS. It is important that surgical interventions are only considered in the inactive stage of disease in order to minimize the risk of reactivation. If signs for disease activity occur, perioperative immunosuppressive therapy should be considered. In linear LS of the limbs, epiphysiodesis of the healthy extremity can be considered in order to adjust leg length inequality. This procedure should be performed by an experienced pediatric orthopedist.

Plastic surgical interventions might be considered for cosmetic reasons in linear LS “en coup de sabre” or progressive facial hemiatrophy.

Table 1 Classification of localized scleroderma/morphea*

<p>Limited type</p> <ul style="list-style-type: none">• Plaque-morphea (single or multiple lesions)• Guttate morphea• Atrophoderma idiopathica of Pierini and Pasini (superficial morphea) <p>Generalized type</p> <ul style="list-style-type: none">• Generalized localized scleroderma/morphea• Disabling pansclerotic morphea <p>Linear type</p> <ul style="list-style-type: none">• Linear localized scleroderma/morphea of the extremities• Linear localized scleroderma/morphea “en coup de sabre”• Progressive facial hemiatrophy (Parry–Romberg syndrome) <p>Deep type</p> <ul style="list-style-type: none">• Deep morphea^a <p>Mixed type^b</p> <p>Eosinophilic fasciitis (Shulman syndrome)^c</p>

*According to the German guideline for the diagnosis and treatment of localized scleroderma.¹ All types of LS may present with overlapping features of other types (e.g. generalized types with linear or deep aspects).

^aDeep type of localized scleroderma (LS) and deep morphea are synonymous.

^bMixed types of LS predominantly affect children and often consist of linear LS and morphea (plaques type of LS) or a combination of linear and generalized LS.

^cThe authors consider eosinophilic fasciitis as a separate subtype that belongs to the spectrum of LS.

Table 2 Laboratory parameters in localized scleroderma

Blood differential

- Important in linear types of LS and in eosinophilic fasciitis because of eosinophilia)

Clinical chemistry

- Transaminases (aspartate aminotransferase and alanine transaminase) – elevated transaminases are seen in myositis
- Cholestasis parameters (γ -glutamyltransferase and alkaline phosphatase) – to uncover biliary cirrhosis
- Lactate dehydrogenase
- Creatinine
- Creatine kinase – especially in cases of suspected concomitant myositis
- Blood sedimentation rate and C-reactive protein

Additional diagnostics

- Screening for antibodies against extractable nuclear antigens – only to confirm/exclude systemic sclerosis (e.g. with anti-scl-70 or anti-centromere antibodies); anti-histone antibodies are often detectable in linear types that affect the extremities in children)

LS, localized scleroderma.

Table 3 Differential diagnoses of localized scleroderma*

Initial inflammatory phase in limited localized scleroderma (morphea)

- Lichen sclerosus
- Erythema chronicum migrans
- Cutaneous mastocytosis
- Granuloma annulare
- Radiation dermatitis
- Mycosis fungoides
- Drug-related reactions
- Chronic radiation dermatitis

Late stage in limited localized scleroderma (morphea) mainly with hyperpigmentation

- Post-inflammatory hyperpigmentation
- Lichen planus actinicus
- Café-au-lait spots
- Erythema dyschromicum perstans

Late stage in limited localized scleroderma (morphea) mainly with atrophy

- Acrodermatitis chronica atrophicans
- Lipodystrophy
- Lichen sclerosus
- Scarring

Late stage in limited localized scleroderma (morphea) mainly with sclerosis

- Necrobiosis lipoidica
- Pretibial myxedema

Generalized localized scleroderma

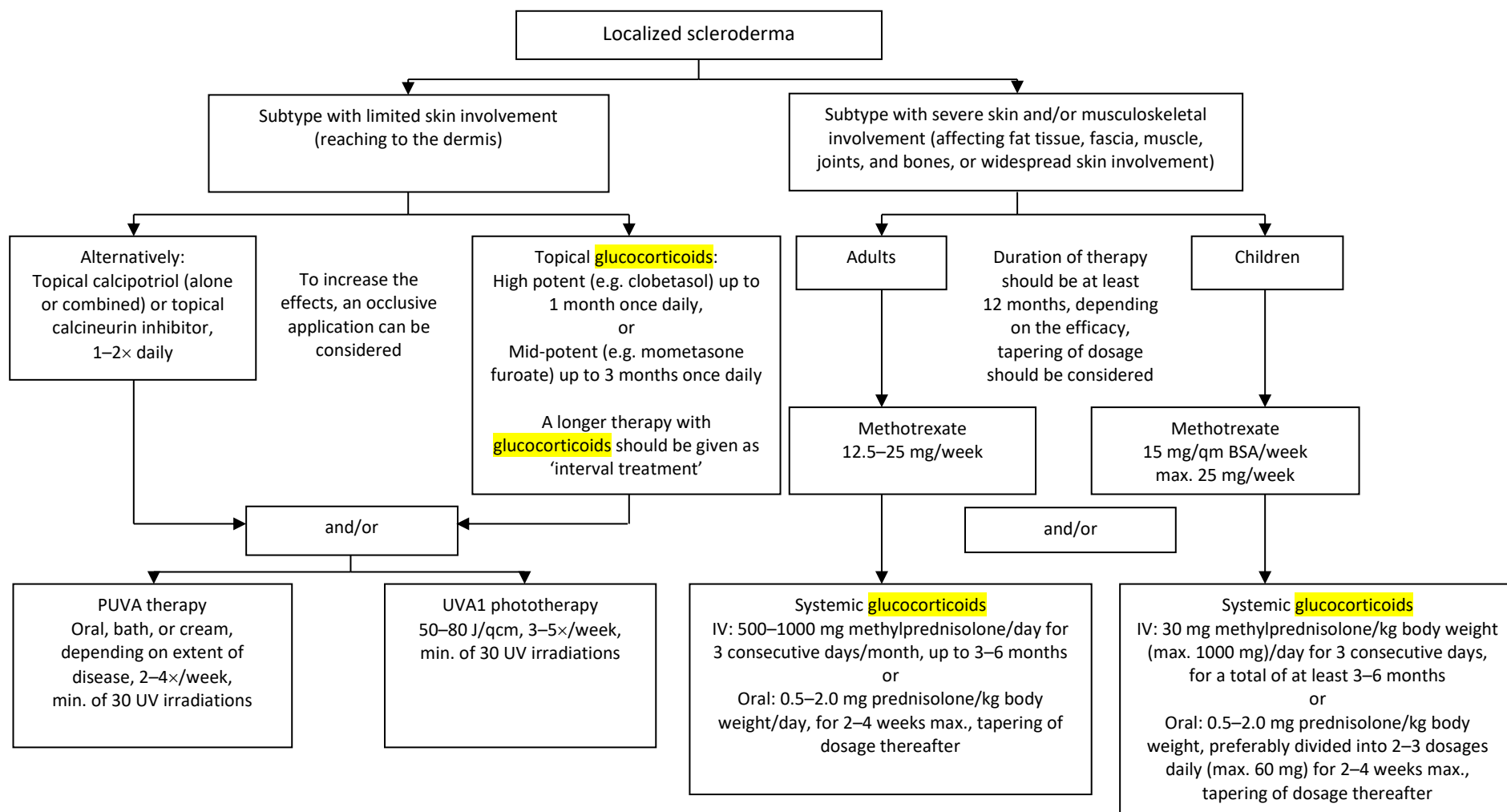
- Systemic scleroderma
- Pseudoscleroderma
- Scleredema adultorum (Buschke's disease)
- Scleromyxedema
- Chronic graft versus host disease
- Mixed connective tissue disease
- Nephrogenic systemic fibrosis, also known as nephrogenic fibrosing dermopathy
- Porphyria cutanea tarda

Linear localized scleroderma, "en coup de sabre"

- Panniculitis
- Progressive lipodystrophy
- Localized lipodystrophy (e.g. lipodystrophia centrifugalis abdominalis infantilis)
- Focal dermal hypoplasia
- Steroid atrophy
- Lupus erythematosus profundus

*According to the German guideline for the diagnosis and treatment of localized scleroderma.¹

Figure 1 Treatment algorithm for localized scleroderma depending on the clinical subtype and extent of disease.



In localized scleroderma subtypes with limited skin involvement that do not adequately respond to topical or phototherapy, systemic therapy should be considered. The dosages and treatment schedules on UVA1 phototherapy and PUVA might also be used in other sclerotic diseases (e.g. sclerotic skin in systemic sclerosis).

References

1. Kreuter A, Krieg T, Worm M, *et al.* AWMF Guideline no. 013/066. Diagnosis and therapy of circumscribed scleroderma. *J Dtsch Dermatol Ges* 2009; **7**(Suppl 6): 1–14.
2. Aringer M, Müller-Ladner U, Burkhardt H, *et al.* Common German language nomenclature for systemic sclerosis. [Article in German]. *Z Rheumatol* 2015; **74**: 100–103.
3. Fett N, Werth VP. Update on morphea: part I. Epidemiology, clinical presentation, and pathogenesis. *J Am Acad Dermatol* 2011; **64**: 217–228.
4. Christen-Zaech S, Hakim MD, Afsar FS, Paller AS. Pediatric morphea (localized scleroderma): review of 136 patients. *J Am Acad Dermatol* 2008; **59**: 385–396.
5. Zulian F, Athreya BH, Laxer R, *et al.* Juvenile localized scleroderma: clinical and epidemiological features in 750 children. An international study. *Rheumatology (Oxford)* 2006; **45**: 614–620.
6. Peterson LS, Nelson AM, Su WP, Mason T, O’Fallon WM, Gabriel SE. The epidemiology of morphea (localized scleroderma) in Olmsted County 1960–1993. *J Rheumatol* 1997; **24**: 73–80.
7. Murray KJ, Laxer RM. Scleroderma in children and adolescents. *Rheum Dis Clin North Am* 2002; **28**: 603–624.
8. Silman A, Jannini S, Symmons D, Bacon P. An epidemiological study of scleroderma in the West Midlands. *Br J Rheumatol* 1988; **27**: 286–290.
9. Leask A, Abraham DJ. TGF-beta signaling and the fibrotic response. *FASEB J* 2004; **18**: 816–827.
10. Higley H, Persichitte K, Chu S, Waegell W, Vancheeswaran R, Black C. Immunocytochemical localization and serologic detection of transforming growth factor beta 1. Association with type I procollagen and inflammatory cell markers in diffuse and limited systemic sclerosis, morphea, and Raynaud’s phenomenon. *Arthritis Rheum* 1994; **37**: 278–288.
11. Ihn H, Sato S, Fujimoto M, Kikuchi K, Takehara K. Demonstration of interleukin-2, interleukin-4 and interleukin-6 in sera from patients with localized scleroderma. *Arch Dermatol Res* 1995; **287**: 193–197.
12. Kreuter A, Hyun J, Skrygan M, *et al.* Ultraviolet A1-induced downregulation of human beta-defensins and interleukin-6 and interleukin-8 correlates with clinical improvement in localized scleroderma. *Br J Dermatol* 2006; **155**: 600–607.
13. Yamamoto T. Chemokines and chemokine receptors in scleroderma. *Int Arch Allergy Immunol* 2006; **140**: 345–356.

14. Gambichler T, Skrygan M, Labanski AA, Kolios AG, Altmeyer P, Kreuter A. Significantly increased CCL5/RANTES and CCR7 mRNA levels in localized scleroderma. *Regul Pept* 2011; **170**: 4–6.
15. Varga J, Abraham D. Systemic sclerosis: a prototypic multisystem fibrotic disorder. *J Clin Invest* 2007; **117**: 557–567.
16. Eisendle K, Grabner T, Zelger B. Morphea: a manifestation of infection with *Borrelia* species? *Br J Dermatol* 2007; **157**: 1189–1198.
17. Colome-Grimmer MI, Payne DA, Tyring SK, Sanchez RL. *Borrelia burgdorferi* DNA and *Borrelia hermsii* DNA are not associated with morphea or lichen sclerosus et atrophicus in the southwestern United States. *Arch Dermatol* 1997; **133**: 1174.
18. Dillon WI, Saed GM, Fivenson DP. *Borrelia burgdorferi* DNA is undetectable by polymerase chain reaction in skin lesions of morphea, scleroderma, or lichen sclerosus et atrophicus of patients from North America. *J Am Acad Dermatol* 1995; **33**: 617–620.
19. Peroni A, Zini A, Braga V, Colato C, Adami S, Girolomoni G. Drug-induced morphea: report of a case induced by balicatib and review of the literature. *J Am Acad Dermatol* 2008; **59**: 125–129.
20. Bleasel NR, Stapleton KM, Commens C, Ahern VA. Radiation-induced localized scleroderma in breast cancer patients. *Australas J Dermatol* 1999; **40**: 99–102.
21. Davis DA, Cohen PR, McNeese MD, Duvic M. Localized scleroderma in breast cancer patients treated with supervoltage external beam radiation: radiation port scleroderma. *J Am Acad Dermatol* 1996; **35**: 923–927.
22. Sommer A, Gambichler T, Bacharach-Buhles M, von Rothenburg T, Altmeyer P, Kreuter A. Clinical and serological characteristics of progressive facial hemiatrophy: a case series of 12 patients. *J Am Acad Dermatol* 2006; **54**: 227–233.
23. Peterson LS, Nelson AM, Su WP. Classification of morphea (localized scleroderma). *Mayo Clin Proc* 1995; **70**: 1068–1076.
24. Laxer RM, Zulian F. Localized scleroderma. *Curr Opin Rheumatol* 2006; **18**: 606–613.
25. Jacobson L, Palazij R, Jaworsky C. Superficial morphea. *J Am Acad Dermatol* 2003; **49**: 323–325.
26. Jablonska S, Blaszczyk M. Is superficial morphea synonymous with atrophoderma Pasini-Pierini? *J Am Acad Dermatol* 2004; **50**: 979–980.
27. Weibel L, Harper JI. Linear morphea follows Blaschko's lines. *Br J Dermatol* 2008; **159**: 175–181.

28. Tollefson MM, Witman PM. En coup de sabre morphea and Parry-Romberg syndrome: a retrospective review of 54 patients. *J Am Acad Dermatol* 2007; **56**: 257–263.
29. Blaszczyk M, Krolicki L, Krasu M, Glinska O, Jablonska S. Progressive facial hemiatrophy: central nervous system involvement and relationship with scleroderma en coup de sabre. *J Rheumatol* 2003; **30**: 1997–2004.
30. Orozco-Covarrubias L, Guzman-Meza A, Ridaura-Sanz C, Carrasco Daza D, Sosa-de-Martinez C, Ruiz-Maldonado R. Scleroderma ‘en coup de sabre’ and progressive facial hemiatrophy. Is it possible to differentiate them? *J Eur Acad Dermatol Venereol* 2002; **16**: 361–366.
31. Leitenberger JJ, Cayce RL, Haley RW, Adams-Huet B, Bergstresser PR, Jacobe HT. Distinct autoimmune syndromes in morphea: a review of 245 adult and pediatric cases. *Arch Dermatol* 2009; **145**: 545–550.
32. Kreuter A, Wischniewski J, Terras S, Altmeyer P, Stücker M, Gambichler T. Coexistence of lichen sclerosus and morphea: a retrospective analysis of 472 patients with localized scleroderma from a German tertiary referral center. *J Am Acad Dermatol* 2012; **67**: 1157–1162.
33. Uitto J, Santa Cruz DJ, Bauer EA, Eisen AZ. Morphea and lichen sclerosus et atrophicus. Clinical and histopathologic studies in patients with combined features. *J Am Acad Dermatol* 1980; **3**: 271–279.
34. Tremaine R, Adam JE, Orizaga M. Morphea coexisting with lichen sclerosus et atrophicus. *Int J Dermatol* 1990; **29**: 486–489.
35. Kreuter A, Kryvosheyeva Y, Terras S, *et al.* Association of autoimmune diseases with lichen sclerosus in 532 male and female patients. *Acta Derm Venereol* 2013; **93**: 238–241.
36. Mertens JS, Seyger MM, Kievit W, *et al.* Disease recurrence in localized scleroderma: a retrospective analysis of 344 patients with paediatric- or adult-onset disease. *Br J Dermatol* 2015; **172**: 722–728.
37. Saxton-Daniels S, Jacobe HT. An evaluation of long-term outcomes in adults with pediatric-onset morphea. *Arch Dermatol* 2010; **146**: 1044–1045.
38. Takehara K, Sato S. Localized scleroderma is an autoimmune disorder. *Rheumatology (Oxford)* 2005; **44**: 274–279.
39. Vierra E, Cunningham BB. Morphea and localized scleroderma in children. *Semin Cutan Med Surg* 1999; **18**: 210–225.
40. Sato S, Fujimoto M, Kikuchi K, Ihn H, Tamaki K, Takehara K. Soluble CD4 and CD8 in serum from patients with localized scleroderma. *Arch Dermatol Res* 1996; **288**: 358–362.

41. Hayakawa I, Hasegawa M, Takehara K, Sato S. Anti-DNA topoisomerase IIalpha autoantibodies in localized scleroderma. *Arthritis Rheum* 2004; **50**: 227–232.
42. Tomimura S, Ogawa F, Iwata Y, *et al.* Autoantibodies against matrix metalloproteinase-1 in patients with localized scleroderma. *J Dermatol Sci* 2008; **52**: 47–54.
43. Yimane K, Ihn H, Kubo M, Asano Y, Yazawa N, Tamaki K. Anti-U3 snRNP antibodies in localised scleroderma. *Ann Rheum Dis* 2001; **60**: 1157–1158.
44. Krieg T, Takehara K. Skin disease: a cardinal feature of systemic sclerosis. *Rheumatology* (Oxford) 2009; **48**(Suppl 3): iii14–18.
45. Clements P, Lachenbruch P, Siebold J, *et al.* Inter and intraobserver variability of total skin thickness score (modified Rodnan TSS) in systemic sclerosis. *J Rheumatol* 1995; **22**: 1281–1285.
46. Arkachaisri T, Vilaiyuk S, Li S, *et al.* The localized scleroderma skin severity index and physician global assessment of disease activity: a work in progress toward development of localized scleroderma outcome measures. *J Rheumatol* 2009; **36**: 2819–2829.
47. Arkachaisri T, Vilaiyuk S, Torok KS, Medsger TA Jr. Development and initial validation of the localized scleroderma skin damage index and physician global assessment of disease damage: a proof-of-concept study. *Rheumatology* (Oxford) 2010; **49**: 373–381.
48. Chung L, Lin J, Furst DE, Fiorentino D. Systemic and localized scleroderma. *Clin Dermatol* 2006; **24**: 374–392.
49. Uziel Y, Krafchik BR, Silverman ED, Thorner PS, Laxer RM. Localized scleroderma in childhood: a report of 30 cases. *Semin Arthritis Rheum* 1994; **23**: 328–340.
50. Marzano AV, Menni S, Parodi A, *et al.* Localized scleroderma in adults and children. Clinical and laboratory investigations on 239 cases. *Eur J Dermatol* 2003; **13**: 171–176.
51. Zulian F, Vallongo C, Woo P, *et al.* Localized scleroderma in childhood is not just a skin disease. *Arthritis Rheum* 2005; **52**: 2873–2881.
52. Holland KE, Steffes B, Nocton JJ, Schwabe MJ, Jacobson RD, Drolet BA. Linear scleroderma en coup de sabre with associated neurologic abnormalities. *Pediatrics* 2006; **117**: e132–136.
53. Stone J. Parry-Romberg syndrome: a global survey of 205 patients using the Internet. *Neurology* 2003; **61**: 674–676.
54. Arkachaisri T, Fertig N, Pino S, Medsger TA Jr. Serum autoantibodies and their clinical associations in patients with childhood- and adult-onset linear scleroderma. A single-center study. *J Rheumatol* 2008; **35**: 2439–2444.

55. Uziel Y, Feldman BM, Krafchik BR, Yeung RS, Laxer RM. Methotrexate and corticosteroid therapy for pediatric localized scleroderma. *J Pediatr* 2000; **136**: 91–95.
56. Kreuter A, Gambichler T, Avermaete A, *et al.* Combined treatment with calcipotriol ointment and low-dose ultraviolet A1 phototherapy in childhood morphea. *Pediatr Dermatol* 2001; **18**: 241–245.
57. Cunningham BB, Landells ID, Langman C, Sailer DE, Paller AS. Topical calcipotriene for morphea/linear scleroderma. *J Am Acad Dermatol* 1998; **39**: 211–215.
58. Kroft EB, Groeneveld TJ, Seyger MM, de Jong EM. Efficacy of topical tacrolimus 0.1% in active plaque morphea: randomized, double-blind, emollient-controlled pilot study. *Am J Clin Dermatol* 2009; **10**: 181–187.
59. Mancuso G, Berdondini RM. Localized scleroderma: response to occlusive treatment with tacrolimus ointment. *Br J Dermatol* 2005; **152**: 180–182.
60. Stefanaki C, Stefanaki K, Kontochristopoulos G, *et al.* Topical tacrolimus 0.1% ointment in the treatment of localized scleroderma. An open label clinical and histological study. *J Dermatol* 2008; **35**: 712–718.
61. Dytoc M, Ting PT, Man J, Sawyer D, Fiorillo L. First case series on the use of imiquimod for morphea. *Br J Dermatol* 2005; **153**: 815–820.
62. Campione E, Paternò EJ, Diluvio L, Orlandi A, Bianchi L, Chimenti S. Localized morphea treated with imiquimod 5% and dermoscopic assessment of effectiveness. *J Dermatolog Treat* 2009; **20**: 10–13.
63. Pope E, Doria AS, Theriault M, Mohanta A, Laxer RM. Topical imiquimod 5% cream for pediatric plaque morphea: a prospective, multiple-baseline, open-label pilot study. *Dermatology* 2011; **223**: 363–369.
64. Hunzelmann N, Anders S, Fierlbeck G, *et al.* Double-blind, placebo-controlled study of intralesional interferon gamma for the treatment of localized scleroderma. *J Am Acad Dermatol* 1997; **36**: 433–435.
65. Joly P, Bamberger N, Crickx B, Belaich S. Treatment of severe forms of localized scleroderma with oral corticosteroids: follow-up study on 17 patients. *Arch Dermatol* 1994; **130**: 663–664.
66. Michet CJ Jr, Doyle JA, Ginsburg WW. Eosinophilic fasciitis: report of 15 cases. *Mayo Clin Proc* 1981; **56**: 27–34.
67. Zulian F, Martini G, Vallongo C, *et al.* Methotrexate treatment in juvenile localized scleroderma: a randomized, double-blind, placebo-controlled trial. *Arthritis Rheum* 2011; **63**: 1998–2006.

68. Seyger MM, van den Hoogen FH, de Boo T, de Jong EM. Low-dose methotrexate in the treatment of widespread morphea. *J Am Acad Dermatol* 1998; **39**: 220–225.
69. Kreuter A, Gambichler T, Breuckmann F, *et al.* Pulsed high-dose corticosteroids combined with low-dose methotrexate in severe localized scleroderma. *Arch Dermatol* 2005; **141**: 847–852.
70. Weibel L, Sampaio MC, Visentin MT, Howell KJ, Woo P, Harper JI. Evaluation of methotrexate and corticosteroids for the treatment of localized scleroderma (morphoea) in children. *Br J Dermatol* 2006; **155**: 1013–1020.
71. Fitch PG, Rettig P, Burnham JM, *et al.* Treatment of pediatric localized scleroderma with methotrexate. *J Rheumatol* 2006; **33**: 609–614.
72. Cox D, O'Regan G, Collins S, Byrne A, Irvine A, Watson R. Juvenile localised scleroderma: a retrospective review of response to systemic treatment. *Ir J Med Sci* 2008; **177**: 343–346.
73. Kroft EB, Creemers MC, van den Hoogen FH, Boezeman JB, de Jong EM. Effectiveness, side-effects and period of remission after treatment with methotrexate in localized scleroderma and related sclerotic skin diseases: an inception cohort study. *Br J Dermatol* 2009; **160**: 1075–1082.
74. Mirsky L, Chakkittakandiyil A, Laxer RM, O'Brien C, Pope E. Relapse after systemic treatment in paediatric morphoea. *Br J Dermatol* 2012; **166**: 443–445.
75. Li SC, Torok KS, Pope E, *et al.* Development of consensus treatment plans for juvenile localized scleroderma: a roadmap toward comparative effectiveness studies in juvenile localized scleroderma. *Arthritis Care Res (Hoboken)*. 2012; **64**: 1175–1185.
76. Martini G, Ramanan AV, Falcini F, Girschick H, Goldsmith DP, Zulian F. Successful treatment of severe or methotrexate-resistant juvenile localized scleroderma with mycophenolate mofetil. *Rheumatology (Oxford)* 2009; **48**: 1410–1413.
77. Mertens JS, Marsman D, van de Kerkhof PC, *et al.* Use of mycophenolate mofetil in patients with severe localized scleroderma resistant or intolerant to methotrexate. *Acta Derm Venereol* 2015; doi: 10.2340/00015555-2297.
78. Roos N, Poulalhon N, Farge D, Madelaine I, Mauviel A, Verrecchia F. In vitro evidence for a direct anti-fibrotic role of the immunosuppressive drug mycophenolate mofetil. *J Pharmacol Exp Ther* 2007; **321**: 583–589.
79. Hulshof MM, Bouwes Bavinck JN, Bergman W, *et al.* Double-blind, placebo-controlled study of oral calcitriol for the treatment of localized and systemic scleroderma. *J Am Acad Dermatol* 2000; **43**: 1017–1023.

80. Falanga V, Medsger TA Jr. D-penicillamine in the treatment of localized scleroderma. *Arch Dermatol* 1990; **126**: 609–612.
81. Clements PJ, Furst DE, Wong WK, *et al.* High-dose versus low-dose D-penicillamine in early diffuse systemic sclerosis: analysis of a two-year, double-blind, randomized, controlled clinical trial. *Arthritis Rheum* 1999; **42**: 1194–1203.
82. Chimenti MS, Teoli M, Di Stefani A, Giunta A, Esposito M, Perricone R. Resolution with rituximab of localized scleroderma occurring during etanercept treatment in a patient with rheumatoid arthritis. *Eur J Dermatol* 2013; **23**: 273–274.
83. Diab M, Coloe JR, Magro C, Bechtel MA. Treatment of recalcitrant generalized morphea with infliximab. *Arch Dermatol* 2010; **146**: 601–604.
84. Moinzadeh P, Krieg T, Hunzelmann N. Imatinib treatment of generalized localized scleroderma (morphea). *J Am Acad Dermatol* 2010; **63**: 102–104.
85. Stausbøl-Grøn B, Olesen AB, Deleuran B, Deleuran MS. Abatacept is a promising treatment for patients with disseminated morphea profunda: presentation of two cases. *Acta Derm Venereol* 2011; **91**: 686–688.
86. Cribier B, Faradji T, Le Coz C, Oberling F, Grosshans E. Extracorporeal photochemotherapy in systemic sclerosis and severe morphea. *Dermatology* 1995; **191**: 25–31.
87. Peter RU, Ruzicka T, Eckert F. Low-dose cyclosporine A in the treatment of disabling morphea. *Arch Dermatol* 1991; **127**: 1420–1421.
88. Gambichler T, Terras S, Kreuter A. Treatment regimens, protocols, dosage, and indications for UVA1 phototherapy: facts and controversies. *Clin Dermatol* 2013; **31**: 438–454.
89. Stein B, Rahmsdorf HJ, Steffen A, Litfin M, Herrlich P. UV-induced DNA damage is an intermediate step in UV-induced expression of human immunodeficiency virus type 1, collagenase, c-fos, and metallothionein. *Mol Cell Biol* 1989; **9**: 5169–5181.
90. Scharffetter K, Wlaschek M, Hogg A, *et al.* UVA irradiation induces collagenase in human dermal fibroblasts in vitro and in vivo. *Arch Dermatol Res* 1991; **283**: 506–511.
91. Kerscher M, Volkenandt M, Meurer M, Lehmann P, Plewig G, Rocken M. Treatment of localised scleroderma with PUVA bath photochemotherapy. *Lancet* 1994; **343**: 1233.
92. Breuckmann F, Gambichler T, Altmeyer P, Kreuter A. UVA/UVA1 phototherapy and PUVA photochemotherapy in connective tissue diseases and related disorders: a research based review. *BMC Dermatol* 2004; **4**: 11.
93. Dawe RS. There are no safe exposure limits for phototherapy. *Br J Dermatol* 2010; **163**: 209–210.

94. Kerscher M, Meurer M, Sander C, *et al.* PUVA bath photochemotherapy for localized scleroderma: evaluation of 17 consecutive patients. *Arch Dermatol* 1996; **132**: 1280–1282.
95. Pavlotsky F, Sakka N, Lozinski A, Barzilai A. Bath psoralen-UVA photochemotherapy for localized scleroderma: experience from a single institute. *Photodermatol Photoimmunol Photomed* 2013; **29**: 247–252.
96. Grundmann-Kollmann M, Ochsendorf F, Zollner TM, *et al.* PUVA-cream photochemotherapy for the treatment of localized scleroderma. *J Am Acad Dermatol* 2000; **43**: 675–678.
97. El-Mofty M, Zaher H, Bosseila M, Yousef R, Saad B. Low-dose broad-band UVA in morphea using a new method for evaluation. *Photodermatol Photoimmunol Photomed* 2000; **16**: 43–49.
98. El-Mofty M, Mostafa W, Esmat S, *et al.* Suggested mechanisms of action of UVA phototherapy in morphea: a molecular study. *Photodermatol Photoimmunol Photomed* 2004; **20**: 93–100.
99. El-Mofty M, Mostafa W, El-Darouty M, *et al.* Different low doses of broad-band UVA in the treatment of morphea and systemic sclerosis. *Photodermatol Photoimmunol Photomed* 2004; **20**: 148–156.
100. Kerscher M, Dirschka T, Volkenandt M. Treatment of localised scleroderma by UVA1 phototherapy. *Lancet* 1995; **346**: 1166.
101. Stege H, Berneburg M, Humke S, *et al.* High-dose UVA1 radiation therapy for localized scleroderma. *J Am Acad Dermatol* 1997; **36**: 938–944.
102. Kerscher M, Volkenandt M, Gruss C, *et al.* Low-dose UVA phototherapy for treatment of localized scleroderma. *J Am Acad Dermatol* 1998; **38**: 21–26.
103. Camacho NR, Sanchez JE, Martin RF, Gonzalez JR, Sanchez JL. Medium-dose UVA1 phototherapy in localized scleroderma and its effect in CD34-positive dendritic cells. *J Am Acad Dermatol* 2001; **45**: 697–699.
104. de Rie MA, Enomoto DN, de Vries HJ, Bos JD. Evaluation of medium-dose UVA1 phototherapy in localized scleroderma with the cutometer and fast Fourier transform method. *Dermatology* 2003; **207**: 298–301.
105. Tuchinda C, Kerr HA, Taylor CR, *et al.* UVA1 phototherapy for cutaneous diseases: an experience of 92 cases in the United States. *Photodermatol Photoimmunol Photomed* 2006; **22**: 247–253.

106. Sator PG, Radakovic S, Schulmeister K, Honigsmann H, Tanew A. Medium-dose is more effective than low-dose ultraviolet A1 phototherapy for localized scleroderma as shown by 20-MHz ultrasound assessment. *J Am Acad Dermatol* 2009; **60**: 786–791.
107. Andres C, Kollmar A, Mempel M, Hein R, Ring J, Eberlein B. Successful ultraviolet A1 phototherapy in the treatment of localized scleroderma: a retrospective and prospective study. *Br J Dermatol* 2010; **162**: 445–447.
108. Su O, Onsun N, Onay HK, *et al.* Effectiveness of medium-dose ultraviolet A1 phototherapy in localized scleroderma. *Int J Dermatol* 2011; **50**: 1006–1013.
109. Kreuter A, Hyun J, Stucker M, Sommer A, Altmeyer P, Gambichler T. A randomized controlled study of low-dose UVA1, medium-dose UVA1, and narrowband UVB phototherapy in the treatment of localized scleroderma. *J Am Acad Dermatol* 2006; **54**: 440–447.
110. Wang F, Garza LA, Cho S; *et al.* Effect of increased pigmentation on the antifibrotic response of human skin to UV-A1 phototherapy. *Arch Dermatol* 2008; **144**: 851–858.
111. Jacobe HT, Cayce R, Nguyen J. UVA1 phototherapy is effective in darker skin: a review of 101 patients of Fitzpatrick skin types I-V. *Br J Dermatol* 2008; **159**: 691–696.
112. Vasquez R, Jabbar A, Khan F, Buethe D, Ahn C, Jacobe H. Recurrence of morphea after successful ultraviolet A1 phototherapy: a cohort study. *J Am Acad Dermatol* 2014; **70**: 481–488.

II Scleromyxedema

Introduction

Scleromyxedema, also known as generalized and sclerodermoid lichen myxedematosus or Arndt–Gottron disease, is a primary cutaneous mucinosis characterized by a generalized papular and sclerodermoid cutaneous eruption that usually occurs in association with monoclonal gammopathy.^{1,2} Affected patients develop numerous waxy firm papules and plaques that demonstrate mucin deposition, increased fibroblast proliferation, and fibrosis on histologic examination. Systemic manifestations may involve the cardiovascular, gastrointestinal, pulmonary, musculoskeletal, renal, or nervous systems, and may lead to significant morbidity and mortality.

Epidemiology

Scleromyxedema is a rare disease that usually affects middle-aged adults between the ages of 30 and 80 years with no race or sex predominance.³ In a multicenter retrospective study of 30 patients with scleromyxedema, the mean age of affected patients was 59 years.³ This illness has rarely been reported in infants and young children.

Pathogenesis

The pathogenesis of scleromyxedema is unknown. The true significance of the associated monoclonal gammopathy and the underlying plasma cell clone is unclear. The main hypothesis is that circulating cytokines such as interleukin (IL)-1, tumor necrosis factor (TNF)-alpha, and transforming growth factor (TGF)-beta, which are known to stimulate glycosaminoglycan synthesis and fibroblast proliferation in the skin, could play a role.^{1,2,4} Clinical remission of scleromyxedema following autologous stem cell transplantation suggests that the bone marrow may be a source of these circulating factors.⁵

However, paraprotein levels usually do not correlate with the severity of disease, disease progression, or the response to treatment.³ Only on an anecdotal basis has the complete resolution of skin lesions coincided with the normalization of the bone marrow and the disappearance of the paraprotein.⁶

Clinical manifestation

The clinical manifestations of scleromyxedema include both cutaneous and extracutaneous features.

Cutaneous manifestations

The characteristic skin finding in scleromyxedema is a widespread eruption of 2 to 3 mm, firm, waxy, closely-spaced, dome-shaped or flat-topped papules involving the hands, forearms, head, neck, upper trunk, and thighs. Papules are often arranged in a strikingly linear array and the surrounding skin is shiny and indurate (i.e. sclerodermoid) in appearance. Rarely, non-tender subcutaneous nodules are present. The glabella is typically involved with deep, longitudinal furrows that produce a characteristic leonine face. Deep furrowing is also typically evident on the trunk or limbs and is called the “Shar-Pei sign.” Erythema, edema, and a brownish discoloration may be seen in the involved areas; pruritus is not uncommon.

Eyebrow, axillary, and pubic hair may be sparse in patients with scleromyxedema. The mucous membranes are spared. As the condition progresses, erythematous and infiltrated plaques may appear with skin stiffening, sclerodactyly, and decreased motility of the mouth and joints. On the proximal interphalangeal joints, a central depression surrounded by an elevated rim (due to skin thickening) can be seen and is referred to as the “doughnut sign.” Unlike scleroderma, telangiectasias and calcinosis are absent and the Raynaud’s phenomenon occurs rarely.

Extracutaneous manifestations

Patients with scleromyxedema can have systemic manifestations, including neurologic, rheumatologic, cardiovascular, gastrointestinal, pulmonary, and renal manifestations of the disease. In a multicenter retrospective study of 30 patients with scleromyxedema, the most common extracutaneous manifestations were neurologic abnormalities (30% of patients), rheumatologic abnormalities (25% of patients), and cardiac abnormalities (22% of patients).³

Neurologic

Neurologic symptoms may involve the peripheral nervous system (e.g. carpal tunnel syndrome or peripheral sensory and motor neuropathy). Carpal tunnel syndrome is thought to be due to either deposition of glycosaminoglycans in the carpal tunnel or to a direct toxic effect in the median nerve.⁷ The central nervous system (CNS) can also be involved (e.g. memory loss, vertigo, gait problems, stroke, seizures, psychosis).^{8,9} The dermatoneuro syndrome is a rare,

and potentially lethal (acute neurologic complication characterized by fever, confusion, dysarthria, lethargy, convulsions, and coma).^{9,10}

Rheumatologic

Rheumatologic manifestations are characterized by arthralgia or arthritis of the peripheral joints, especially of the hands, with non-inflammatory synovial fluids.¹¹ A severe destructive polyarthritis resembling rheumatoid arthritis has also been reported.¹² Proximal or generalized weakness due to inflammatory myopathy and fibromyalgia is common and usually occurs several months or years after the onset of skin involvement.^{4,13} In these patients, muscle biopsy reveals a necrotizing and vacuolar myopathy; interstitial inflammatory infiltrates are found uncommonly and may cause confusion with polymyositis. A few cases of true dermatomyositis have been described in association with scleromyxedema.¹⁴ Spontaneous or interferon alfa-induced rhabdomyolysis is an additional rare finding.^{15,16}

Cardiovascular

Cardiovascular abnormalities with congestive heart failure, myocardial ischemia, heart block, and pericardial effusion may occur.^{3,17,18} Valvular myocardial mucin deposition has been described in a case report.¹⁹

Gastrointestinal

Dysphagia is the most common gastrointestinal manifestation and is related to esophageal dysmotility mainly localized to the upper esophagus.²⁰ Dysphagia is most commonly found in patients with an associated myopathy. Nasal regurgitation may also occur.²⁰

Respiratory

Dyspnea on exertion is the most common pulmonary finding, due to obstructive or restrictive pathology.²⁰⁻²² In addition, hoarseness and aspiration may occur due to laryngeal involvement with decreased epiglottis and vocal cord mobility.²³

Renal

Involvement of the kidney, characterized by a scleroderma renal crisis-like acute renal failure, is a rare event.²⁴

Ocular

Infrequently, corneal opacities and ectropion are seen.

Associated disorders

Scleromyxedema is associated with paraproteinemia. The monoclonal gammopathy is usually IgG with a predominance of lambda light chains over kappa light chains.^{3,20,21} Less frequently, a different paraproteinemia is detected. In a retrospective study of 26 patients with scleromyxedema evaluated at a single academic center between 1966 and 1990, alternative paraproteinemias were detected in three patients (IgM-kappa, IgA-kappa, or IgA-lambda), and a further three patients had no evidence of a paraproteinemia.²⁰ Patients with scleromyxedema in the absence of paraproteinemia are considered to have an atypical form of the disease.

A mild plasmacytosis may be found in the bone marrow of patients with scleromyxedema. However, the disease is estimated to progress to multiple myeloma in less than 10% of cases.⁴ Anecdotal associations with hematologic malignancies (such as Hodgkin and non-Hodgkin lymphomas, Waldenström's macroglobulinemia, and myelomonocytic leukemia) or visceral carcinomas have been reported,^{3,25-27} however, no clear association with any specific non-iatrogenic neoplasm has been identified. Most malignancies in these patients are iatrogenic and associated with the use of melphalan treatment.²⁰

Clinical course

Scleromyxedema follows a chronic, progressive, and sometimes unpredictable course.² Depending on the rapidity of onset and the degree of involvement, patients may be either initially asymptomatic or may notice that skin becomes thick and hard, and that the face shows a diffuse induration and coarsening in the forehead lines and in lateral portions of the chin. As the disease progresses (usually over the course of years and occasionally over the course of several months), a diffuse sclerodermoid induration with overlying papules, sclerodactyly, and decreased motility of the mouth and joints occurs. Our experience suggests that spontaneous resolution does not occur; however, at least one case of apparent spontaneous resolution has been reported.²⁸

Systemic consequences of scleromyxedema may result in death.³ In a case series in which follow-up was available for 21 patients with scleromyxedema (mean follow-up time 33.5 months, range 2 months to 11 years), at the end of follow-up, five patients died (23.8%), whereas 12 patients were alive with disease and four patients were alive without disease.³ Death

was caused by extracutaneous complications of scleromyxedema including dermatoneuro syndrome (two patients) and myocardial insufficiency due to endocardial mucin deposition (one patient) or by an associated myeloid leukemia (one patient) or Hodgkin lymphoma (one patient).

Diagnostic procedures

Histopathology

Scleromyxedema is characterized by a triad of microscopic features that includes:^{29,30}

- a diffuse deposit of mucin composed primarily of hyaluronic acid in the upper and mid-reticular dermis; the presence of mucin can be confirmed with an Alcian blue stain (pH 2.5) or a colloidal iron stain and hyaluronidase digestion;
- an increase in collagen deposition;
- a marked proliferation of irregularly arranged fibroblasts.

A rare interstitial, granuloma annulare-like pattern has been described in cutaneous biopsy specimens from patients with scleromyxedema.³¹ This histologic pattern is characterized by a diffuse, interstitial proliferation of blue-gray histiocytes, giant cells, and lymphocytes within the papillary and mid-reticular dermis forming loose granulomas among collagen fibers and mucin deposits.

Histologic specimens from extracutaneous sites may demonstrate mucin filling endocardium walls of myocardial blood vessels as well as the interstitium of the kidney, lungs, pancreas, adrenal glands, and nerves.¹⁸ Lymph node involvement with infiltration by numerous fibroblasts surrounded by mucin and collagen deposits has been observed.³²

The diagnosis of scleromyxedema is based upon the recognition of the following clinicopathologic criteria:

- generalized papular and sclerodermoid eruption;
- microscopic triad, including mucin deposition, fibrosis, and fibroblast proliferation;
- monoclonal gammopathy;
- absence of thyroid disorder.

Atypical forms of scleromyxedema include scleromyxedema in the absence of monoclonal gammopathy or scleromyxedema demonstrating an interstitial granulomatous-like pattern on histopathology.

Differential diagnosis

The major disorders to be considered in the differential diagnosis of scleromyxedema are localized scleroderma (LS), systemic scleroderma (systemic sclerosis [SSc]), scleredema, and nephrogenic systemic fibrosis/nephrogenic fibrosing dermopathy (NSF, NFD).³³

Scleroderma

Although patients with scleromyxedema may have symptoms that mimic scleroderma, such as sclerodactyly, the Raynaud's phenomenon (rarely), and esophageal dysmotility, clinical and laboratory features distinguish the two diseases. The presence of diffuse, waxy papules in linear arrays and in a characteristic distribution that includes the glabella and posterior auricular area, the involvement of the middle portion of the back (always spared in scleroderma), and the presence of an IgG monoclonal gammopathy all favor a diagnosis of scleromyxedema. Histologically, dermal mucin deposition is absent in LS and SSc.

Scleredema

The histologic findings of scleromyxedema and scleredema differ. The fibroblast proliferation that is evident in histologic specimens of scleromyxedema is absent in scleredema, whereas scleredema shows increased thickness of the dermis and deeper collagen deposition with mucin deposition in the spaces (fenestrations) between collagen bundles.

Nephrogenic systemic fibrosis/dermopathy

NSF and NFD can have a similar histologic appearance to scleromyxedema, with findings of mucin and fibroblastic proliferation in biopsy specimens. Clinical correlation is useful for distinguishing the two diseases. Unlike scleromyxedema, facial involvement (common in scleromyxedema), and monoclonal gammopathy are not features of nephrogenic systemic fibrosis. Further details for NSF can be found in section IV of this guideline.

Localized lichen myxedematosus

In localized lichen myxedematosus the following features of scleromyxedema are absent: sclerotic features, systemic involvement, and monoclonal gammopathy. In the past, the terms

“papular mucinosis,” “lichen myxedematosus,” and “scleromyxedema” were often used indiscriminately. Although scleromyxedema and the localized type of lichen myxedematosus, including subtypes such as acral persistent papular mucinosis, discrete lichen myxedematosus, papular mucinosis of infancy, and nodular lichen myxedematosus, belong to the same disease spectrum, it is important to make a distinction between the two disorders because of differences in prognosis and the approach to therapy.^{1,2} Historically, most patients reported in the literature to have lichen myxedematosus or papular mucinosis without specification of the disease subtype appear to have had scleromyxedema with monoclonal gammopathy. Occasionally, patients have overlapping or atypical features and fall in between scleromyxedema and localized lichen myxedematosus.²

Treatment

No randomized trials have evaluated therapies for scleromyxedema, and data are primarily limited to case reports and case series due to rarity of the disease. No specific treatment appears to be uniformly effective, and the relative efficacies of the treatments that have been utilized remain unclear.

First-line therapy

Systemic therapy is the treatment method of choice for patients with scleromyxedema. Case reports and case series have documented improvement in the cutaneous and extracutaneous signs and symptoms of scleromyxedema during intravenous immunoglobulin (IVIg) therapy, with a generally favorable tolerability profile.^{3,34} IVIg should furthermore be considered the treatment of choice in refractory cases of scleromyxedema with either fast deterioration of skin symptoms, the dermatoneuro syndrome, or life-threatening involvement of internal organs.

Initial duration of treatment

As with the other conditions, the use of IVIg is initially recommended over a period of 6 months. If there is no response to treatment after this time, treatment should be discontinued.

Interval between infusions

The initial interval between infusions should be 4 weeks. The interval between the individual bolus infusions can then be increased gradually to 6 weeks. Any additional increase in the interval is not recommended, as the half-life time of IVIg is about 21 days.

Dosing

Most experience in scleromyxedema exists with the standard dose of 2 g per kg body weight. This should be adopted as the standard recommendation.

Treatment period

Treatment should be administered over a period of 2 days. In the case of severe organ involvement, such as kidney or heart involvement in particular, or in patients at risk of renal involvement, with concomitant diuretics, diabetes, hypertension, obesity or in elderly patients, the treatment period should be increased to 5 days.

Evaluation of treatment efficacy

The focus lies on the clinical evaluation of treatment efficacy. As skin involvement is present in nearly all cases and responds very well to treatment with IVIg, it should be used as an indicator of response. Therefore re-evaluation after three cycles is recommended. In isolated cases, clinical response to CNS or internal organ involvement can be used as an additional indicator of response in scleromyxedema.

Long-term therapy

Relapse has been documented in several cases after discontinuation of IVIg. If a relapse is severe or life-threatening, long-term therapy can be recommended in exceptional cases.^{3,35-37}

The mechanism through which IVIg improves scleromyxedema is unclear. Suggested mechanisms underlying the immunomodulatory effects of IVIg include neutralization of circulating autoantibodies by anti-idiotypic antibodies, functional blockade and modulation of Fc fragment receptors at the surface of macrophages, and inhibition of fibrosis via modulation of the production of cytokines and cytokine antagonists.³⁸

Side-effects

Drawbacks of IVIg treatment are its high cost and the time-consuming administration. IVIg treatment is well tolerated. Side-effects such as skin rash, arthralgia, myalgia, fever, headache, thoracic or abdominal pain, nausea, and tachycardia may occur. Severe adverse events related to IVIg treatment are rare and include anaphylactic shock in patients with IgA deficiency and anti-IgA antibodies, renal insufficiency in at-risk patients, aseptic meningitis, hemolytic anemia, and thrombosis. Myocardial ischemia and death secondary to suspected myocardial

infarction³⁹ have been reported in scleromyxedema patients with known cardiac risk factors during treatment with IVIg. However, the side-effects experienced by patients receiving IVIg for scleromyxedema generally have been mild and self-limiting, and vanish after slowing down the infusion rate.

Second-line therapies

When IVIg treatment is not an option or yields an insufficient response, thalidomide (or lenalidomide) and systemic glucocorticoids are the next-line options for treatment. Thalidomide and systemic glucocorticoids can be given alone or in combination therapy with IVIg.⁴⁰⁻⁴³

Thalidomide

The mechanism of action of thalidomide in scleromyxedema is unknown. The immunomodulatory effects of thalidomide on pro-inflammatory and pro-fibrotic cytokines and the antiangiogenic properties of thalidomide may contribute to inhibition of fibrosis.

Treatment with thalidomide should begin at a dose of 50 to 100 mg per day. The dose is slowly increased according to clinical response and tolerance up to 150 to 400 mg per day. Once a satisfactory response is achieved, the lowest dose effective for maintaining improvement is used for maintenance therapy.

Teratogenicity and irreversible peripheral neuropathy are side-effects of thalidomide that can limit the use of this therapy. Patients should be monitored for the development of peripheral neuropathy during treatment. In the United States, patient and provider participation in the System for Thalidomide Education and Prescribing Safety, a program aimed to prevent the use of thalidomide during pregnancy, is required for the use of this medication. Other potential adverse effects of thalidomide include drowsiness, constipation, thrombosis, and leukopenia.

A few case reports have documented the use of lenalidomide, a thalidomide derivative with a more favorable side-effect profile, for scleromyxedema. Lenalidomide (25 mg per day for 3 weeks per month) appeared beneficial when used in combination with IVIg.⁴⁴

Systemic glucocorticoids

Systemic glucocorticoids have been used for scleromyxedema in conjunction with chemotherapeutic agents or as monotherapy. It is postulated that benefit from systemic glucocorticoids may result from immunosuppressive and anti-fibrotic effects of these agents.

Data on the efficacy of systemic glucocorticoids in scleromyxedema are limited to case reports. Prednisone (0.5 to 1 mg/kg/day), prednisolone (0.3 to 0.5 mg/kg/day), and oral high-dose dexamethasone (40 mg once daily for 4 days per week during three consecutive weeks each month) have been associated with improvement in cutaneous manifestations of scleromyxedema in individual patients.⁴⁵⁻⁴⁷ The associated paraproteinemia may or may not improve in patients in whom systemic glucocorticoid therapy induces remission of scleromyxedema. Failure of systemic glucocorticoid therapy to improve scleromyxedema has also been reported.

Severe and refractory disease

Patients who do not improve with the therapies above may benefit from interventions aimed at treating the associated plasma cell dyscrasia. Examples of the therapeutic options typically reserved for these patients include autologous stem cell transplantation, melphalan, and bortezomib with dexamethasone.⁴⁸ Data are limited on the efficacy of these therapies for cutaneous and extracutaneous manifestations of scleromyxedema. In addition, the response to these treatments is variable and relapse may occur. Thus, the risks associated with these therapies must be considered carefully prior to treatment.

Autologous stem cell transplantation

Multiple cases of scleromyxedema treated with autologous stem cell transplantation have been reported since the initial report of a complete remission in 2001.⁵ In a review of 17 reported cases of scleromyxedema treated with autologous stem cell transplantation published between 2001 and 2011, complete remission (resolution of all clinical symptoms, skin abnormality, and serum paraprotein) was achieved in 10 patients (59%) and partial remission was achieved in five patients (29%).⁴⁹ However, only two of the complete responders remained in remission after follow-up periods that ranged from 14 to >60 months.

Melphalan

Although melphalan was often considered a first-line treatment for scleromyxedema in the past, the potential for drug-related serious adverse events limits the use of this agent. A review of 17

patients who received melphalan for scleromyxedema (1 to 4 mg per day or cyclic therapy) at a single medical center found that although 12 patients had improvement of skin disease with therapy, improvement was temporary in eight patients and nine patients died of hematologic malignancy or septic complications that were considered to be related to therapy.²⁰ Therefore, melphalan is not recommended for scleromyxedema.

Bortezomib and dexamethasone

Combination therapy with bortezomib and dexamethasone has been associated with rapid improvement in cutaneous manifestations and constitutional symptoms of scleromyxedema in case reports, including a patient who relapsed after autologous stem cell transplantation.⁴⁸

Other therapies

Case reports have documented clinical improvement in patients treated with topical betamethasone and topical dimethyl sulfoxide, topical and intralesional glucocorticoid therapy, oral isotretinoin, acitretin, interferon-alfa, hydroxychloroquine, cyclosporine, and chemotherapeutic agents, including cyclophosphamide, methotrexate, chlorambucil, and 2-chlorodeoxyadenosine. The efficacies of these agents for scleromyxedema remain to be confirmed.

UVA-1 or PUVA phototherapy, Grenz ray, and total skin electron-beam therapy have also been reported to improve scleromyxedema in case reports. These therapies do not have an impact on paraproteinemia and systemic involvement.

Dermato-neuro syndrome

The approach to patients with dermato-neuro syndrome is not standardized and various treatments have seemed to yield benefit in case reports. Examples include IVIg,⁵⁰ systemic glucocorticoids plus plasmapheresis or IVIg, systemic glucocorticoids plus cyclophosphamide and plasmapheresis, melphalan plus IVIg and bortezomib plus dexamethasone.⁸⁻¹⁰ The most suitable choice appears to be IVIg associated with systemic glucocorticoids tapered according to the efficacy.

Cosmetic interventions

Case reports suggest that facial disfigurement can be treated with dermabrasion plus surgery or carbon dioxide laser with good cosmetic results. These procedures do not affect systemic manifestations of scleromyxedema.

A treatment algorithm for scleromyxedema is shown in Fig. 1.

Prognosis and follow-up

Scleromyxedema is a disease with an unpredictable but usually progressive and disabling course in the absence of successful treatment. Even when therapy is successful, long-term maintenance therapy is usually required as relapse commonly occurs upon the discontinuation of treatment. Death may result from complications of extracutaneous involvement or adverse effects of therapy.

Because of the various cutaneous and extracutaneous manifestations of scleromyxedema, a multidisciplinary team is often needed for the optimal management of these patients. Depending on the clinical manifestations, dermatologists, hematologists, cardiologists, pulmonologists, gastroenterologists, hand surgeons, and other specialists can be valuable for managing affected patients.

The unpredictable course of scleromyxedema, the variable response to treatment, and the common occurrence of relapse demand close, long-term follow-up of these patients. We usually reassess patients once per month with a full skin examination, review of systems, and re-evaluation of the therapeutic regimen. Serologic studies, including assessment of the status of the associated monoclonal gammopathy, are not useful for monitoring disease activity.

Patients should be cautioned that development of neurologic symptoms (e.g. dysarthria) and flu-like illness may be the initial signs of dermato-neuro syndrome. Patients with such symptoms should be admitted to the hospital for close observation and evaluation.

Summary and recommendations

- Scleromyxedema is a rare skin disease characterized by generalized papular skin eruptions. It is often associated with monoclonal gammopathy and may have accompanying systemic

features. The disorder typically affects adults. There is no sex predilection. The pathogenesis of scleromyxedema is unknown.

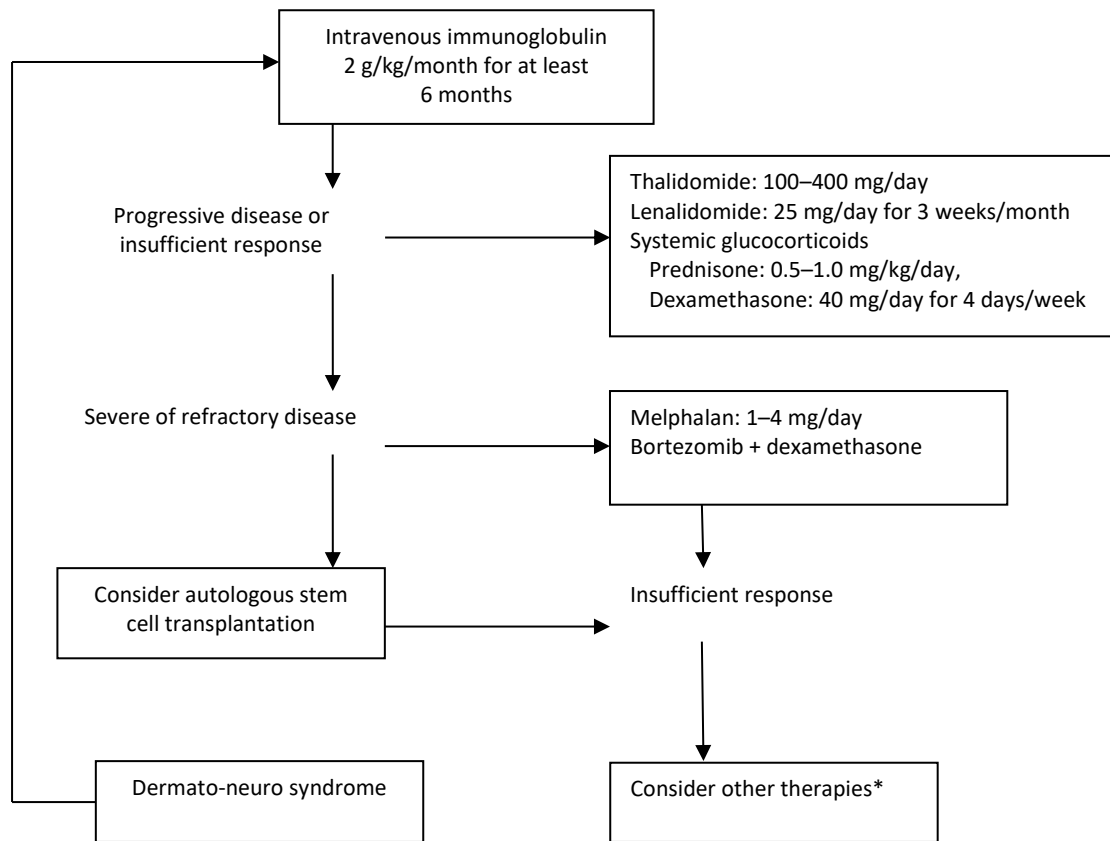
- The cutaneous manifestations of scleromyxedema consist of widespread waxy papules and indurated plaques (Table 1). Progressive cutaneous involvement can lead to decreased motility of the mouth and joints. Extracutaneous involvement in scleromyxedema can present with a variety of manifestations. Neurologic, musculoskeletal, cardiac, gastrointestinal, respiratory, or renal abnormalities may develop.
- The clinical course of scleromyxedema is chronic and progressive. Cutaneous and extracutaneous involvement can lead to significant morbidity. Death may result from complications related to extracutaneous involvement or adverse effects of therapy.
- The diagnosis of scleromyxedema is based upon recognition of consistent clinical, pathologic, and laboratory findings. The presence of the following features is supportive of the diagnosis:
 - generalized papular and sclerodermoid eruption;
 - microscopic triad, including mucin deposition, fibrosis, and fibroblast proliferation;
 - monoclonal gammopathy;
 - absence of thyroid disorder.
- There are no randomized controlled trials on the treatment of scleromyxedema. The available data consist primarily of case reports and case series.
- Patients with scleromyxedema generally require systemic therapy. High-dose IVIg as initial treatment (Grade 2C) is suggested. Thalidomide or other TNF blockers and systemic glucocorticoids are alternative treatment options that may also be used in conjunction with IVIg therapy.
- Patients who do not respond to IVIg, thalidomide, TNF blockers, or systemic glucocorticoids may benefit from other therapies. Examples of treatment options for severe and refractory disease include autologous stem cell transplantation, melphalan, and bortezomib plus dexamethasone. The risk–benefit ratios of treatment must be carefully considered prior to therapy.
- Recurrence of scleromyxedema is common after withdrawal of an effective therapy. Long-term maintenance treatment is usually required, and close clinical follow-up is necessary.

<TABLE 1>

Table 1 Scleromyxedema and scleredema overview

Features	Scleromyxedema	Scleredema
Clinical cutaneous	A widespread papular eruption accompanied by skin induration (particularly involving the hands, face), and edematous fingers and hands	Symmetrical diffuse progressive non-pitting swelling and induration of the upper part of the body (especially neck, posterior neck, and upper back) with occasional erythema
Clinical extracutaneous	Neurologic, musculoskeletal, cardiac, gastrointestinal, respiratory, or renal	Ocular, tongue, upper part of the esophagus, cardiac, pulmonary
Associated disorders	Monoclonal gammopathy	Upper respiratory infection, diabetes mellitus, or blood dyscrasia
Histopathology	Mucin deposition, fibrosis, and fibroblast proliferation in the superficial/mid dermis	Thickness of dermis with interstitial mucin deposition between fenestration of collagen without fibroblast proliferation
Diagnosis	Generalized papular and sclerodermoid eruption Microscopic triad, including mucin deposition, fibrosis, and fibroblast proliferation Monoclonal gammopathy Absence of thyroid disorder	Clinicopathologic correlation with a non-pitting induration of the upper part of the body caused by a thickened dermis and deposition of mucin, associated with diabetes mellitus or with a history of infection or blood dyscrasia
Treatment	Intravenous immunoglobulin	Usually not required or treat the underlying condition

Figure 1 Treatment algorithm for scleromyxedema.



*Other therapies include topical betamethasone and topical dimethyl sulfoxide, topical and intralesional glucocorticoid therapy, oral isotretinoin, acitretin, interferon-alfa, hydroxychloroquine, cyclosporine, and chemotherapeutic agents, including cyclophosphamide, methotrexate, chlorambucil, and 2-chlorodeoxyadenosine. UVA-1 or PUVA phototherapy, Grenz ray, and total skin electron-beam therapy.

References

1. Rongioletti F, Rebora A. Mucinoses. In: *Dermatology* (Bolognia J, Jorizzo JL, Schaffer JV, *et al.*, eds), 3rd edn. Philadelphia: Elsevier, 2012; 1: 687.
2. Rongioletti F. Lichen myxedematosus (papular mucinosis): new concepts and perspectives for an old disease. *Semin Cutan Med Surg* 2006; **25**: 100–104.
3. Rongioletti F, Merlo G, Cinotti E, *et al.* Scleromyxedema: a multicenter study of characteristics, comorbidities, course, and therapy in 30 patients. *J Am Acad Dermatol* 2013; **69**: 66–72.
4. Cokonis Georgakis CD, Falasca G, Georgakis A, Heymann WR. Scleromyxedema. *Clin Dermatol* 2006; **24**: 493–497.
5. Feasel AM, Donato ML, Duvic M. Complete remission of scleromyxedema following autologous stem cell transplantation. *Arch Dermatol* 2001; **137**: 1071.
6. Yeung CK, Loong F, Kwong YL. Scleromyxoedema due to a plasma cell neoplasm: rapid remission with bortezomib, thalidomide and dexamethasone. *Br J Haematol* 2012; **157**: 411.
7. Berger JR, Dobbs MR, Terhune MH, Maragos WF. The neurologic complications of scleromyxedema. *Medicine* 2001; **80**: 313.
8. Rongioletti F, Hazini A, Rebora A. Coma associated with scleromyxoedema and interferon alfa therapy. Full recovery after steroids and cyclophosphamide combined with plasmapheresis. *Br J Dermatol* 2001; **144**: 1283.
9. Fleming KE, Virmani D, Sutton E, *et al.* Scleromyxedema and the dermatoneuro syndrome: case report and review of the literature. *J Cutan Pathol* 2012; **39**: 508.
10. Rey JB, Luria RB. Treatment of scleromyxedema and the dermatoneuro syndrome with intravenous immunoglobulin. *J Am Acad Dermatol* 2009; **60**: 1037.
11. Espinosa A, De Miguel E, Morales C, *et al.* Scleromyxedema associated with arthritis and myopathy: a case report. *Clin Exp Rheumatol* 1993; **11**: 545.
12. Jamieson TW, De Smet AA, Stechschulte DJ. Erosive arthropathy associated with scleromyxedema. *Skeletal Radiol* 1985; **14**: 286.
13. Helfrich DJ, Walker ER, Martinez AJ, Medsger TA Jr. Scleromyxedema myopathy: case report and review of the literature. *Arthritis Rheum* 1988; **31**: 1437.
14. Launay D, Hatron PY, Delaporte E, *et al.* Scleromyxedema (lichen myxedematosus) associated with dermatomyositis. *Br J Dermatol* 2001; **144**: 359.
15. Rothe MJ, Rivas R, Gould E, Kerdel FA. Scleromyxedema and severe myositis. *Int J Dermatol* 1989; **28**: 657.

16. Ozdag F, Akar A, Eroglu E, Erbil H. Acute rhabdomyolysis during the treatment of scleromyxedema with interferon alfa. *J Dermatolog Treat* 2001; **12**: 167.
17. Pomann JJ, Rudner EJ. Scleromyxedema revisited. *Int J Dermatol* 2003; **42**: 31.
18. De Simone C, Castriota M, Carbone A, *et al.* Cardiomyopathy in scleromyxedema: report of a fatal case. *Eur J Dermatol* 2010; **20**: 852.
19. Morris-Jones R, Staughton RC, Walker M, *et al.* Lichen myxoedematosus with associated cardiac abnormalities. *Br J Dermatol* 2001; **144**: 594.
20. Dinneen AM, Dicken CH. Scleromyxedema. *J Am Acad Dermatol* 1995; **33**: 37.
21. Blum M, Wigley FM, Hummers LK. Scleromyxedema: a case series highlighting long-term outcomes of treatment with intravenous immunoglobulin (IVIG). *Medicine* 2008; **87**: 10.
22. Le Moigne M, Mazereeuw-Hautier J, Bonnetblanc JM, *et al.* [Clinical characteristics, outcome of scleromyxoedema: a retrospective multicentre study]. *Ann Dermatol Venereol* 2010; **137**: 782.
23. Rapp MF, Guram M, Konrad HR, *et al.* Laryngeal involvement in scleromyxedema: a case report. *Otolaryngol Head Neck Surg* 1991; **104**: 362.
24. Lee YH, Sahu J, O'Brien MS, *et al.* Scleroderma renal crisis-like acute renal failure associated with mucopolysaccharide accumulation in renal vessels in a patient with scleromyxedema. *J Clin Rheumatol* 2011; **17**: 318.
25. Chan JC, Trendell-Smith NJ, Yeung CK. Scleromyxedema: a cutaneous paraneoplastic syndrome associated with thymic carcinoma. *J Clin Oncol* 2012; **30**: e27.
26. Alfadley A, Al Hoqail I, Al Eisa A. Scleromyxedema: possible association with seminoma. *J Am Acad Dermatol* 2000; **42**: 875.
27. Giménez Garcia R, Garcia SG, Suarez Vilela D, Moro Sanchez MJ. Scleromyxedema associated with non-Hodgkin lymphoma. *Int J Dermatol* 1989; **28**: 670.
28. Hardie RA, Hunter JA, Urbaniak S, Habeshaw JA. Spontaneous resolution of lichen myxoedematosus. *Br J Dermatol* 1979; **100**: 727.
29. Rongioletti F, Rebora A. Cutaneous mucinoses: microscopic criteria for diagnosis. *Am J Dermatopathol* 2001; **23**: 257.
30. Rongioletti F, Rebora A. Updated classification of papular mucinosis, lichen myxedematosus, and scleromyxedema. *J Am Acad Dermatol* 2001; **44**: 273
31. Rongioletti F, Cozzani E, Parodi A. Scleromyxedema with an interstitial granulomatous-like pattern: a rare histologic variant mimicking granuloma annulare. *J Cutan Pathol* 2010; **37**: 1084.

32. Delyon J, Bézier M, Rybojad M, *et al.* Specific lymph node involvement in scleromyxedema: a new diagnostic entity for hypermetabolic lymphadenopathy. *Virchows Arch* 2013; **462**: 679.
33. Nashel J, Steen V. Scleroderma mimics. *Curr Rheumatol Rep* 2012; **14**: 39–46.
34. Bidier M, Zschoche C, Gholam P, *et al.* Scleromyxoedema: clinical follow-up after successful treatment with high-dose immunoglobulins reveals different long-term outcomes. *Acta Derm Venereol* 2012; **92**: 408.
35. Sroa N, Campbell S, Bechtel M. Intravenous immunoglobulin therapy for scleromyxedema: a case report and review of literature. *J Drugs Dermatol* 2010; **9**: 263.
36. Gholam P, Hartmann M, Enk A. Arndt-Gottron scleromyxoedema: successful therapy with intravenous immunoglobulins. *Br J Dermatol* 2007; **157**: 1058.
37. Körber A, Franckson T, Grabbe S, Dissemond J. Successful therapy of scleromyxoedema Arndt-Gottron with low-dose intravenous immunoglobulin. *J Eur Acad Dermatol Venereol* 2007; **21**: 553.
38. Samuelsson A, Towers TL, Ravetch JV. Anti-inflammatory activity of IVIG mediated through the inhibitory Fc receptor. *Science* 2001; **291**: 484.
39. Binitha MP, Nandakumar G, Thomas D. Suspected cardiac toxicity to intravenous immunoglobulin used for treatment of scleromyxedema. *Indian J Dermatol Venereol Leprol* 2008; **74**: 248.
40. Sansbury JC, Cocuroccia B, Jorizzo JL, *et al.* Treatment of recalcitrant scleromyxedema with thalidomide in 3 patients. *J Am Acad Dermatol* 2004; **51**: 126.
41. Guarenti I, Sebastiani V, Pinto G, *et al.* Successful treatment of scleromyxedema with oral thalidomide. *Int J Dermatol* 2013; **52**: 631.
42. Martins A, Paiva Lopes MJ, Tavares Belo R, Rodrigues JC. Scleromyxedema – thalidomide therapy. *J Eur Acad Dermatol Venereol* 2008; **22**: 622.
43. Efthimiou P, Blanco M. Intravenous gammaglobulin and thalidomide may be an effective therapeutic combination in refractory scleromyxedema: case report and discussion of the literature. *Semin Arthritis Rheum* 2008; **38**: 188.
44. Brunet-Possenti F, Hermine O, Marinho E, *et al.* Combination of intravenous immunoglobulins and lenalidomide in the treatment of scleromyxedema. *J Am Acad Dermatol* 2013; **69**: 319.
45. Rayson D, Lust JA, Duncan A, Su WP. Scleromyxedema: a complete response to prednisone. *Mayo Clin Proc* 1999; **74**: 481.

46. Lin YC, Wang HC, Shen JL. Scleromyxedema: an experience using treatment with systemic corticosteroid and review of the published work. *J Dermatol* 2006; **33**: 207.
47. Horn KB, Horn MA, Swan J, *et al.* A complete and durable clinical response to high-dose dexamethasone in a patient with scleromyxedema. *J Am Acad Dermatol* 2004; **51**: S120.
48. Cañueto J, Labrador J, Román C, *et al.* The combination of bortezomib and dexamethasone is an efficient therapy for relapsed/refractory scleromyxedema: a rare disease with new clinical insights. *Eur J Haematol* 2012; **88**: 450.
49. Bos R, de Waal EG, Kuiper H, *et al.* Thalidomide and dexamethasone followed by autologous stem cell transplantation for scleromyxoedema. *Rheumatology* 2011; **50**: 1925.
50. Gholam P, Hartmann M, Enk A. Arndt-Gottron scleromyxoedema: successful therapy with intravenous immunoglobulins. *Br J Dermatol* 2007; **157**: 1058–1060.

III Systemic sclerosis

Introduction

The diagnosis and treatment of systemic scleroderma/systemic sclerosis (SSc) is challenging due to the heterogeneity of disease manifestations and disease course. Diagnosis and care should, at least in part, be in the hands of specialists who have daily exposure to the disease and have access to modern diagnostic procedures (e.g. high-resolution computed tomography [HR-CT], magnetic resonance imaging (MRI), body plethysmography, echocardiography, gastroscopy, spirometry, and nailfold capillaroscopy) and to a laboratory with expertise in autoimmune serology. In order to provide optimal care, cooperation with different subspecialties (e.g. rheumatology, dermatology, gastroenterology, pulmonary medicine, cardiology, nephrology) is necessary due to the nature of the disease, which affects several organ systems.

Systematic baseline and longitudinal assessments to define the complications are mandatory. Multidisciplinary care for patients with early progressive disease should be provided in a setting where the outpatient facilities also have access to hospital beds in order to ensure timely and appropriate treatment for patients presenting with exacerbation of their disease. In these specialized facilities, access to physical therapy should be available.

In 2009, for the first time evidence-based recommendations for the treatment of SSc were published by the European League against Rheumatism Scleroderma Trials and Research (EUSTAR) study group,¹ where many of the recommendations given below are described in more detail. An updated form of the EUSTAR treatment recommendations is in preparation and is due to be published in 2016. In addition, for a more detailed description, the reader is referred to the “*Consensus best practice recommendations for scleroderma*” developed by UK Scleroderma Study Group.²

The present guideline has been prepared bearing in mind that healthcare systems differ considerably between countries in Europe. The recommendations, as presented here, may be influenced, among others, by hospitalization rules, the availability of outpatient facilities, and financial reimbursement of specific procedures and therapies.

Clinical manifestation and classification

SSc is a heterogeneous, chronic autoimmune disorder, leading to fibrosis of the skin and many internal organs.³ In 1980, the American College of Rheumatology published preliminary criteria for the classification of patients with established disease.⁴ A subclassification, developed by LeRoy *et al.*, has been the most widely used classification system in clinical practice,⁵ and forms the basis for many registries worldwide (Table 1). In this classification, diffuse cutaneous SSc (dcSSc) is defined as a progressive form with an early onset of Raynaud's phenomenon, usually within 1 year of the onset of skin changes. This subset is characterized by rapid involvement of trunk, face, proximal and distal extremities. Very frequently, anti-topoisomerase-1 antibodies (anti-topo-1, anti-Scl-70) are present.⁶⁻⁸

<TABLE 1>

Limited cutaneous SSc (lcSSc) is defined by skin affection of the extremities distal to the elbow and knee joints. These patients often (50–70%) have anti-centromere antibodies (ACA).⁶⁻⁸ It has been widely accepted that the so called “CREST syndrome” and “systemic sclerosis sine scleroderma” can be seen as part of the disease spectrum of the limited cutaneous form of SSc.⁹

In 2013, the American College of Rheumatology (ACR) and the European League Against Rheumatism (EULAR) published new classification criteria (Table 2).¹⁰ The classification incorporates diagnostic measures, such as anti-nuclear antibodies and capillaroscopy, which have not been included before. However, when applying these new classification criteria it should be kept in mind that they were developed primarily for clinical research purposes and cannot be applied to patients without skin involvement of the hands or to patients with scleroderma-like disorders.

For patients with very early disease (also referred to as very early/early SSc, pre-SSc, or undifferentiated connective tissue disease), there are no generally accepted criteria.¹¹ In these cases, it has to be considered, that, for instance, only two-thirds of patients with Raynaud's phenomenon, nailfold capillaroscopic changes, and/or SSc-specific antibodies (ACA, anti-topo-1) will develop definite SSc after 5 years.¹² Nevertheless, almost 80% of these patients develop SSc in the long term. In addition, patients without a scleroderma pattern on capillaroscopy nor presence of SSc-specific antibodies do not develop SSc (1.8% during long-term follow-up).¹² Subsequently, capillaroscopy and SSc-specific antibodies seem to be good

prognostic predictors for the disease. Therefore, it is recommended that patients with suspected early SSc are referred to centers that are experienced in SSc diagnosis and care.

Diagnostic procedures

Antinuclear antibodies

Autoantibodies targeting characteristic nuclear antigens are one of the hallmarks of SSc. The frequency of detection of antinuclear antibodies (ANA) in SSc patients in a recent study approached 95%,⁸ which corresponds well with ANA frequencies of between 85% and 99% reported in the literature. In this study, 86.6% of the ANA-positive patients had SSc-specific antibodies, 96.4% of which were detecting five antigens (i.e. centromere, topoisomerase-1, RNA polymerase III, PM/Scl, U1-RNP) (Table 3). It is generally well accepted that the SSc-specific antibodies described above are largely mutually exclusive. Coincidences in individual patients do occur but are rare.

For a more detailed description of autoantibodies linked to overlap syndromes, please see section V (*Systemic sclerosis overlap syndromes*).

<TABLE 3>

Capillaroscopy

Capillaroscopy (e.g. videocapillaroscope, stereomicroscope, or dermatoscope) is a well-established, non-invasive technique for the identification of changes in the nailfold capillary that differentiate primary Raynaud's phenomenon from SSc.

For a detailed review the reader is referred to the article by Cutolo *et al.*¹³

Organ involvement and diagnostic work-up

Raynaud's phenomenon

Raynaud's phenomenon is characterized by a vasospasm resulting in blanching, cyanosis, and then reactive hyperemia (triphasic). Raynaud's phenomenon is present in more than 90% of patients. It typically affects the hands, less commonly the feet, but may also involve the tongue, ears, and nose. Cold exposure is the usual trigger, but emotional stress may evoke the same symptoms.

Primary Raynaud's phenomenon is mainly caused by functional disturbances, whereas in secondary Raynaud's phenomenon in the context of SSc, there is also involvement of structural alterations in digitate arteries. These combined changes are considered to be major causes for the formation of ulcers. To distinguish primary from secondary Raynaud's phenomenon, nailfold capillaroscopy and the analysis of autoantibodies are required. Additional laboratory and radiologic examinations may become necessary in order to exclude other factors that may contribute to the symptoms of Raynaud's phenomenon.¹⁴

Skin fibrosis

At the onset of the disease, particularly in the diffuse form, patients tend to have swollen fingers and hands over extended periods of time, so called "puffy hands." Sclerotic changes follow later on, finally leading to dermatogenic contractures and sclerodactyly. Perioral plication and microstomia are typical features of the face, as is a mask-like stiffness.

The best and validated tool to measure the progress of the skin sclerosis is the modified Rodnan Skin Score (mRSS). At 17 different anatomical areas, the skin score is evaluated by manual palpation. The skin score is 0 for uninvolved skin, 1 for mild thickening, 2 for moderate thickening, and 3 for severe thickening. Subsequently, the sum will be used as the total skin score. The mRSS is feasible, reliable, and has been validated for initial and follow-up skin evaluation. The administration of this simple method requires some experience, and a careful teaching process is warranted.¹⁵

Skin involvement and its rate of progression are thought to reflect the severity of internal organ involvement. However, in later disease stages, internal organ involvement may progress while skin fibrosis of the trunk and proximal extremities will diminish.

Fibrosis may be accompanied by additional symptoms such as hair loss, diminished sweating, hyperpigmentation, depigmentation, or severe pruritus.

Digital ulceration

Among patients with SSc, 15–25% have active digital ulceration (DU) and 35% have or have had DUs in the past, although this number varies considerably between centers and studies.^{16–19} Analysis of registry data indicates that the extent of skin sclerosis, male sex, presence of pulmonary arterial hypertension, involvement of the esophagus, presence of anti-topo-1 (but

not anti-centromere) antibodies, early age at onset of Raynaud's phenomenon, and elevated erythrocyte sedimentation rate could be independent risk factors.^{16,18} History of DU when patients first present has been shown to predict the occurrence of DUs at follow-up, and is associated with cardiovascular worsening and decreased survival.²⁰

Ulcers that occur on the fingertip are thought to be exclusively due to ischemia, whereas ulcers over the extensor surfaces of the proximal and distal interphalangeal joints have a mixed etiology. They are usually due to a combination of poor perfusion, stretched fibrotic skin, and trauma. DUs are complicated by secondary infection, osteomyelitis, gangrene, and amputation. Acro-osteolysis may further complicate wound healing. Recurring ulcers lead to chronic use of pain relievers and antibiotics, and eventually to hospitalization either for treatment of active DUs or for surgery (amputation).²¹

Contributory causes, such as coexisting large vessel disease, should be excluded. In addition, differential diagnoses, such as vasculitis, thrombangitis, or arteriosclerotic vascular disease, should be ruled out. Calcinosis cutis should be distinguished from superficial ulceration, but is a possible risk factor for DU.

Calcinosis cutis

Calcinosis cutis is marked by subcutaneous calcium carbonate deposits, which appear in all subtypes of SSc and most frequently on the acral parts of the body. They may induce superficial erosions and cause intense pain for the patient. Calcinosis cutis is an important differential diagnosis to DUs and can be excluded via X-ray of the affected body parts.

Musculoskeletal system

Arthralgia and musculoskeletal pain are among the most frequent complaints in SSc and may lead to secondary fibromyalgia. Tendon friction rubs are a typical sign of an inflammatory, progressive form of the disease. Muscle weakness and a varying increase in serum creatine kinase levels are quite common and can indicate the presence of an SSc-myositis overlap syndrome (i.e. Scl syndrome, anti-synthetase syndrome, mixed connective tissue disease). In these cases, magnetic resonance imaging and a muscle biopsy to determine the type of myositis should be considered.

Inflammatory arthritis can occur in up to 10% of patients and raises the suspicion of the presence of an SSc overlap syndrome (SSc-rheumatoid arthritis). In these cases, rheumatoid factors and anti-cyclic citrullinated peptide (CCP) antibodies (ACPA) (Table 3) should be determined and a rheumatologic work-up initiated. A more detailed description of the diagnosis and treatment can be found in section V (*Systemic sclerosis overlap syndromes*).

Pulmonary involvement

Interstitial lung disease

Interstitial lung disease (ILD) affects up to 65% of SSc patients to varying degrees. The typical presentation is a predominantly bibasilar pattern. While some patients develop a rapid decline of forced vital capacity (FVC) within the first 3 years, others may remain remarkably stable or may even experience improvement.²² In early disease, inflammatory alveolitis may precede and/or accompany interstitial fibrosis, leading to loss of pulmonary function as evidenced by decreased diffusing capacity of the lungs for carbon monoxide (DLCO) and decreased FVC in more severe cases. Most often the ILD corresponds to a non-specific interstitial pneumonitis.

The majority of patients will present with symptoms such as dyspnea, a dry cough, and reduced exercise tolerance. Chest X-ray can be useful but is a relatively insensitive method for the detection of ILD. Chest HR-CT has a markedly higher diagnostic sensitivity and is the recommended diagnostic tool to determine the extent and distribution of ILD. The sensitivity of HR-CT is superior when compared with lung function testing (LFT).²³ LFT should include spirometry, body plethysmography, and DLCO (corrected for hemoglobin). LFT should be performed every 6 months, or more frequently if the patient is developing a loss in FVC and/or a decrease in transfer factor (DLCO).

Pulmonary hypertension

Pulmonary arterial hypertension (PAH) occurs in about 15% of patients, and develops particularly in patients with long disease duration and anti-centromere antibodies. PAH is associated with significant mortality and is among the most common causes of death in SSc.²⁴ All SSc patients should be evaluated for possible PAH in line with current recommendations, and referred for specialist management. Annual screening on symptoms (unexplained or progressive dyspnea, syncope, signs of right heart failure) and by echocardiography are strongly recommended in all SSc patients,¹ and are part of the current recommendations of cardiologic and pulmonary societies (see 2015 Guidelines of the European Society of Cardiology²⁵).

Gastrointestinal involvement

The gastrointestinal tract is frequently involved, with 80% of patients having esophageal involvement and 40–70% having involvement of the stomach, small intestine, and large intestine.^{7,26} In longstanding disease (i.e. >10 years), upper gastrointestinal involvement occurs in nearly all patients. The most common symptoms are heartburn, esophageal dysfunction in the upper gastrointestinal tract, diarrhea due to bacterial overgrowth, and fecal incontinence in the distal tract. Barrett's esophagus is a late sequel of reflux disease and requires surveillance according to the respective guidelines.²⁷

Rarely, telangiectasias may also be present on the mucosa, representing a potential source of occult intestinal bleeding. The standard diagnostic procedure is endoscopy.

Cardiac involvement

The nature and severity of cardiac disease depends on the extent of myocardial fibrosis, and on the extent to which concurrent fibrosis of the lung and thickening and fibrosis of the small pulmonary arteries place an additional burden on the circulation. Myocarditis and pericarditis can be observed in a subset of patients and may lead to diagnostic uncertainty. Risk factors for cardiac involvement are diffuse disease, particularly with rapid progression, and signs of inflammation such as tendon friction rubs. Patchy myocardial fibrosis contributes to diastolic dysfunction and to a diminished left ventricular ejection fraction.

Arrhythmias are quite common in SSc. In patients with the diffuse form of SSc, severe forms of arrhythmias are considered an important source of mortality.²⁸ As regular electrocardiogram is relatively insensitive, there should be a low threshold to use Holter monitoring.

Renal involvement

Acute renal crisis is a serious and potentially fatal SSc complication. It occurs most likely in patients with the progressive, diffuse form with a disease duration of less than 4 years. The presence of anti-RNA polymerase III antibodies is considered a particular risk factor and is detected in about one third of cases.²⁹ Thus, regular control of blood pressure (at least twice weekly/home monitoring) is recommended to detect acute renal involvement early on. Glucocorticoids in higher doses exceeding 15 mg prednisone equivalents should be avoided due to their long-term side-effects and association with renal crisis.²⁹

In a small subset of patients, normotensive acute renal crisis will develop. In these cases, patients often present with signs of thrombotic microangiopathy. Chronic renal involvement in SSc is associated with a slowly progressive obliterative vasculopathy. Urinary protein excretion has been determined in several studies as a major independent risk factor for mortality.³⁰ Therefore, urinary protein excretion should be determined at least annually.

General recommendation for a regular diagnostic work-up in patients with SSc

After an initial baseline assessment (Table 4), at least annual, life-long, follow-up of patients is recommended due to the chronic nature of the disease. In patients with progressive disease, corresponding with disease activity, patients should be followed more frequently. The annual work-up should include a thorough clinical investigation including mRSS and the following diagnostic measures: lung function test with plethysmography including DLCO, blood pressure, electrocardiography, echocardiography, Erythrocyte sedimentation rate/C-reactive protein, complete blood count, clinical chemistry (liver function, creatinine, urea) and urinary protein.

Particularly in patients with an increased risk for renal crisis (progressive diffuse disease, anti-RNA polymerase III antibodies), frequent blood pressure measurements are recommended (preferably home monitoring) (Table 5).

<TABLE 4>

<TABLE 5>

Treatment

Therapy for skin involvement

Treatment of Raynaud's phenomenon

Avoidance of cold exposure and the constant protection against cold is paramount. Heated gloves, shoes, and pockets are usual measures. Furthermore, paraffin baths, heated seed pillows, therapy balls, and physical therapy are recommended.³¹ Smoking should be stopped. Beta-blocker treatment should be substituted, if feasible.

These lifestyle measures should be supported by pharmacologic therapy (Fig. 1). First-line therapy consists of calcium antagonists such as nifedipine or amlodipine. Large meta-analyses

have revealed that calcium antagonists reduce the severity and frequency of Raynaud's attacks. The dosage should be increased carefully. Recent controlled studies indicated that PDE-5 inhibitors (i.e. sildenafil, vardenafil) may also be effective in the treatment of Raynaud's phenomenon, by reducing the severity and frequency of attacks.³²⁻³⁴ However, these drugs have not been licensed for this indication. Selective serotonin reuptake inhibitors, such as fluoxetine, have shown benefit in some patients,³⁵ and angiotensin-converting enzyme (ACE) inhibitors or angiotensin-receptor antagonists may also be considered.³⁶

<FIGURE 1>

An improvement of severe Raynaud's phenomenon has been demonstrated following intravenously administered iloprost.^{37,38} A dosage of 0.5–2 ng/kg/min for 3–6 hours on at least five consecutive days at monthly intervals is generally recommended.^{1,39} The most frequent side-effects are headaches, low blood pressure, and cutaneous flushing. To minimize these side-effects, a slow daily increase of the dosage, depending on the individual patient's condition, is necessary.³⁹

Digital (palmar) sympathectomy (with or without botulinum toxin injection) may be considered in severe and/or refractory cases.

Treatment of digital ulceration

Avoidance of cold exposure and cessation of smoking are accompanying measures. Beta-blocker treatment should be substituted, if feasible. A modified algorithm as published by Riemekasten *et al.*⁴⁰ is shown in Fig. 2.

Infections, especially those that affect deep adjacent structures, should be treated with antibiotics in order to prevent osteomyelitis and avoid amputation.⁴¹ If possible, the antibiotic therapy should be combined with a vasodilatory therapy to improve perfusion of the involved area. Sufficient analgesic therapy is recommended to improve quality of life and to reduce pain-induced vasoconstriction. Adequate wound care and regular clinical inspection are mandatory, in order to prevent infections, gangrene or necrosis.⁴¹ In the case of dry, superficial ulcers, non-occlusive wound care is recommended. The use of a protective wound dressing (i.e. alginate) is advised when deep ulcers are present in order to protect the wound from sources of infection

and to support granulation. Wound care includes a thorough cleaning and disinfection of the wound with sodium chloride, antiseptics or wound cleansing solutions.

Two randomized controlled trials demonstrated that intravenous iloprost is efficacious in healing digital ulcers in SSc. It should be administered at a dosage of 0.5–2 ng/kg per minute for 3–6 hours for at least five consecutive days.^{1,39} The recommended treatment duration varies between 3 and 14 days, and is in part influenced by restrictions in the respective national healthcare system.³⁹

A recent meta-analysis of several randomized controlled trials indicated that PDE-5 inhibitors improve healing of digital ulcers.⁴² Therefore, PDE-5 inhibitors can be considered for the treatment of active digital ulcers.

Bosentan is a non-selective endothelin receptor antagonist that demonstrated efficacy in the prevention of digital ulcers in two randomized and controlled studies (RAPIDS-1 and -2) in SSc patients.^{43–45} A significant reduction in the number of new ulcers was revealed, particularly in patients with multiple ulcers. Side-effects consist of possible liver toxicity, teratogenicity, and reduced effectiveness of oral contraceptive pills through interference with the cytochrome P450 system.^{1,42} Bosentan does not affect healing of active DUs.

Digital (palmar) sympathectomy (with or without botulinum toxin injection) may be considered in severe and/or refractory cases.³⁶

Treatment of skin fibrosis

Therapy for skin sclerosis should be guided by the phase of the fibrotic process (early phase vs. late phase), the disease activity, and the progression of the fibrosis. General measures include skin protection from cold and trauma, skin care with moisturising creams, lymph drainage, and active physiotherapy for the prevention of contractures. These general measures may suffice in mild, non-progressing forms of fibrosis.

In the early phase with limited skin involvement and LS, UVA1 or photochemotherapy (PUVA) should be considered. Similarly to the successful treatment of LS with UVA modalities, a number of uncontrolled studies have indicated a beneficial effect on fibrosis in SSc.^{46–48} However, controlled studies are still lacking. Pruritus often occurs in fibrotic skin, and may

respond to standard therapy and phototherapy. For further details, the reader is referred to Fig. 1 in the LS section, However, longer treatment durations may be needed.

Photopheresis (extracorporeal photochemotherapy) has shown promise in several controlled studies.^{49,50} It can be used as second-line or adjuvant therapy. It is recommended that it should be applied in early progressive disease, preferably of less than 2 years' duration. For more details, the reader is referred to the 2014 EDF guideline.⁵¹

The systemic use of glucocorticoids, which is considered a standard therapy for most autoimmune diseases, plays no role in the therapy of fibrosis in patients with SSc.¹ More importantly, it is well known that glucocorticoids in a dose of >15 mg are associated with a higher incidence of renal crisis.²⁹

The best data for systemic therapy of progressive skin fibrosis are available for methotrexate. In two randomized, controlled studies it was shown that methotrexate decreased skin fibrosis in early diffuse SSc. Positive effects on other organs such as the lung could not be shown.^{52,53} A dosage of 10–15 mg per week for 6–12 months is generally recommended. Higher dosages may be considered. The use of mycophenolate mofetil (MMF) is recommended by the EUSTAR study group as second-line therapy following methotrexate.^{1,54} The recommended standard dosage varies at about 1–2 g per day for at least 12 months.^{1,54}

An improvement of skin sclerosis was demonstrated for cyclophosphamide in the scleroderma lung study.^{1,55} The use of cyclophosphamide is recommended after failure of methotrexate and MMF due to high rates of side-effects.⁵⁴ As renewed deterioration of mRSS and lung involvement were observed during follow-up in the scleroderma lung study, a continuation of immunosuppression with MMF or azathioprine after cyclophosphamide therapy is recommended by some experts. An algorithm for the treatment of SSc skin fibrosis is shown in Fig. 3.

Treatment of calcinosis cutis

Various therapeutic strategies have been investigated, but there is currently no evidence of an effective therapy for calcinosis cutis. Ectopic calcifications or calcinosis that compromise blood circulation or cause symptoms may be removed surgically or by the use of carbon dioxide laser.

Surgical excision seems to be the best option after failure of conservative treatment attempts. However, surgery should only be performed in cases of urgent medical indication.⁵⁶⁻⁵⁸

Treatment of telangiectasias

Telangiectasia may appear in the face, the hands (even on the palms), and the mucosa of patients with SSc.^{59,60} Laser (i.e. potassium titanyl phosphate or flashlamp pulsed dye laser) or intense pulsed light therapy is the treatment of choice to remove telangiectasias.^{59,61} Cosmetics are often used to cover the affected area.

Therapy for musculoskeletal involvement

For detailed treatment recommendations, the reader is referred to Section V (*Systemic sclerosis overlap syndromes*).

Therapy for pulmonary involvement

Treatment of lung fibrosis

ILD in many patients is relatively mild and has a low rate of progression. However, particularly in patients with progressive diffuse disease, a severe reduction in FVC can ensue and the progressive lung fibrosis is recognized as a major cause of mortality.²² It is therefore crucial to identify patients with risk for ILD and to identify patients with a significant progression as measured by a reduction of FVC (>5% in 6 months or >10% in 1 year) or DLCO (>15% in 1 year). Patients with ILD should be considered for early treatment, when the disease is active and the damage is not yet irreversible. Another component of therapy should be adequate treatment of reflux disease, as this may prevent progression of ILD.⁶²

The best available data exist for cyclophosphamide, which showed a modest, statistically significant benefit in a randomized, controlled, double-blind trial on both lung and skin fibrosis.⁵⁵ As the follow-up data of this trial indicated a renewed progression of fibrosis, several groups recommend the prolongation of immunosuppression after 6 or 12 pulses of cyclophosphamide by the use of azathioprine or MMF.⁵⁴

Two randomized controlled trials and a number of uncontrolled studies have shown that hematopoietic stem cell transplantation improves lung function and skin fibrosis compared with standard immunosuppressive treatment.^{63,64} Transplantation can result in rapid (over months) and sustained improvement of mRSS and FVC. However, in the first year, a significantly

increased mortality was observed in the transplantation arm.⁶³ Careful selection of SSc patients for transplantation is mandatory.

Treatment of pulmonary arterial hypertension

Drugs targeting different aspects of vascular pathology have become available in recent years and have dramatically changed therapy of PAH. The diagnosis and therapy of PAH belong in the hands of an experienced cardiologist/pulmonologist with special expertise in right heart disease. The primary task of the dermatologist taking care of an SSc patient will be to initiate regular (i.e. at least annual) echocardiography, and to have a high clinical suspicion for this complication (see 2015 guidelines of the European Society of Cardiology²⁵).

Therapy for gastrointestinal involvement

Standard treatment for gastrointestinal reflux disease and the prevention of esophageal ulcers and strictures is proton pump inhibitors (i.e. pantoprazole 40 mg/day). The majority of patients require maintenance therapy. Second-line options are H₂-blockers and antacids, in addition to appropriate lifestyle changes.^{1,65}

Telangiectasias may occur and cause gastrointestinal bleeding (i.e. gastric antral venous ectasia), which should be treated by endoscopic coagulation.

Prokinetic dopamine agonists may be used for dysphagia and reflux (e.g. metoclopramide, octreotide).⁶⁶ Bacterial overgrowth and fungal infections (e.g. candida esophagitis) can be managed by intermittent antimicrobial therapy and antimycotics.⁶⁷ Anti-diarrheal agents (e.g. loperamide) or laxatives may be used for the symptomatic management of diarrhea or constipation that often alternate as clinical problems. Parenteral nutrition should be considered for patients with severe weight loss refractory to enteral supplementation. For a more detailed overview, the reader is referred to the consensus best practice pathway of the UK scleroderma study group.²⁷

Therapy for renal involvement

Acute renal crisis was the major cause of death before the advent of ACE-inhibitor therapy. Prompt recognition of scleroderma renal crisis and initiation of therapy with an ACE inhibitor offers the best opportunity for a good outcome. Other anti-hypertensive agents may be

considered for managing refractory hypertension in conjunction with ACE in scleroderma renal crisis.

General recommendations for disease management

In order to tailor treatment to the individual patient, it is important to determine disease subset, organ involvement, and disease activity. In recent years, the organ-based approach has brought forward significant pharmacologic advancements, changing remarkably the prognosis and life quality of patient subgroups (Table 6).

Multidisciplinary care of SSc patients should aim beyond the treatment of classic organ involvement. Quality of life is increasingly acknowledged in clinical studies and has to be addressed. The psychosocial well-being of SSc patients is often severely affected by the impression of disfigurement (e.g. from telangiectasias, microstomia, contractures), and patients should be appropriately counseled. This also applies to the treatment of chronic pain and depression/anxiety. It has been shown that pain is an important indicator of sexual dysfunction among women with SSc.⁶⁸ Similarly, erectile dysfunction in male patients is markedly underdiagnosed and undertreated.⁶⁹ Involvement of the masticatory organ may be significant and lead to remarkable deterioration of life quality. Sicca syndrome, gingivitis, tooth decay, and osteolysis/necrosis all contribute to a deterioration of oral health-related quality of life. Adjunctive therapy such as physiotherapy and respiratory therapy should be considered early in the course of organ involvement. Small open controlled trials suggest that manual lymphatic drainage may improve hand function in SSc.

Modern comprehensive disease management in SSc patients should be directed at the underlying disease process and the resulting organ complications, and should also consider the associated physical and psychological consequences.

Table 1 Subclassification of LeRoy *et al.* (1988)⁵

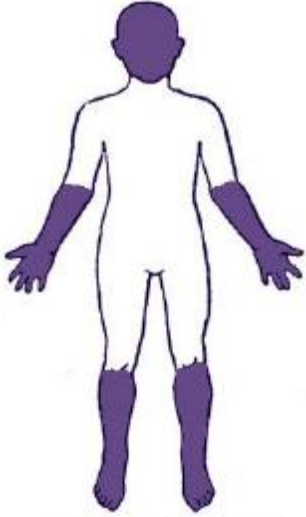
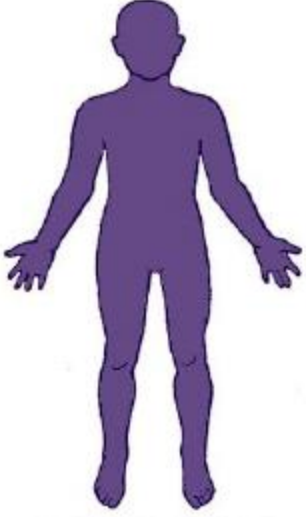
Limited form	Diffuse form
<ul style="list-style-type: none">• Acral sclerosis• Skin involvement of the extremities distal to the elbow and knee joints• Possible involvement of the face• Long duration of Raynaud’s phenomenon• Late pulmonary arterial hypertension• Often anti-centromere positive	<ul style="list-style-type: none">• Progressive systemic sclerosis• Rapid involvement of the trunk, face, and extremities• Lung fibrosis• Early onset of Raynaud’s phenomenon (within 1 year of skin changes)• Often anti-topoisomerase-1 positive
	

Table 2 American College of Rheumatology/European League against Rheumatism 2013 criteria for classification of systemic sclerosis

Item	Sub-item(s)	Weight/score*
Skin thickening of the fingers of both hands extending proximal to the metacarpophalangeal joints (<i>sufficient criterion</i>)	–	9
Skin thickening of the fingers (<i>only count the higher score</i>)	Puffy fingers	2
	Sclerodactyly of the fingers (distal to the metacarpophalangeal joints but proximal to the proximal interphalangeal joints)	4
Fingertip lesions (<i>only count the higher score</i>)	Digital tip ulcers	2
	Fingertip pitting scars	3
Telangiectasia	–	2
Abnormal nailfold capillaries	–	2
Pulmonary arterial hypertension and/or interstitial lung disease (<i>maximum score is 2</i>)	Pulmonary arterial hypertension	2
	Interstitial lung disease	2
Raynaud's phenomenon	–	3
SSc-related autoantibodies (anti-centromere, anti-topoisomerase-1 [anti-topo-1, anti-Scl-70], anti-RNA polymerase III) (<i>maximum score is 3</i>)	Anti-centromere	3
	Anti-topoisomerase-1	
	Anti-RNA polymerase III	

SSc, systemic sclerosis.

*Score ≥ 9 is classified as SSc.

Table 3 Autoantibodies in systemic sclerosis

Antibodies	Organ involvement
Ssc-specific autoantibodies	
Centromere	Pulmonary arterial hypertension
Topoisomerase-1 (Scl-70)	Digital ulcerations, interstitial lung disease, skin fibrosis
RNA polymerase III	Renal crisis, skin fibrosis, paraneoplasia
PM/Scl	Myositis, interstitial lung disease
U1-RNP	Joints
Ssc-associated antibodies	
Ro, La	Parotis (Sjögren syndrome)
CCP	Arthritis
Rheumatoid factor	Arthritis
Mitochondrial (M2)	Liver (primary biliary cirrhosis)

CCP, cyclic citrullinated peptide.

Table 4 Organ oriented baseline work-up

General

- History and physical examination
- ESR/CRP
- Blood count
- Clinical chemistry
- Autoantibody testing

Skin

- Modified Rodnan Skin Score

Musculoskeletal

- Clinical exam
- Creatine kinase
- Anti-CCP
- Rheumatoid factor

Gastrointestinal

- Upper gastrointestinal endoscopy

Lung

- High-resolution computed tomography
- Lung function (FVC, DLCOc/SB)

Heart

- Electrocardiogram
- Echocardiography

Kidney

- Blood pressure (weekly self-monitoring in high-risk patients [anti-RNA polymerase III+])
- Creatinine
- Urinary protein

ESR, erythrocyte sedimentation rate; CRP, C-reactive protein; CCP, cyclic citrullinated peptide; FVC, forced vital capacity; DLCOc/SB, diffusing capacity of the lungs for carbon monoxide per single breath.

Table 5 Organ oriented recommended annual work-up

<p>General</p> <ul style="list-style-type: none">• History and physical examination• ESR/CRP• Blood count• Clinical chemistry <p>Skin</p> <ul style="list-style-type: none">• Modified Rodnan Skin Score <p>Lung</p> <ul style="list-style-type: none">• Lung function (FVC, DLCOc/SB) <p>Heart</p> <ul style="list-style-type: none">• Electrocardiogram• Echocardiography <p>Kidney</p> <ul style="list-style-type: none">• Blood pressure (weekly self-monitoring in high-risk patients [RNA-polymerase +])• Creatinine• Urinary protein
--

ESR, erythrocyte sedimentation rate; CRP, C-reactive protein; FVC, forced vital capacity; DLCOc/SB, diffusing capacity of the lungs for carbon monoxide per single breath.

Table 6 Therapy of internal organ involvement

Gastrointestinal involvement

- Proton pump inhibitor, H₂ blockers, antacids
- Prokinetics (metoclopramide, octreotide)
- Antibiotics (bacterial overgrowth)
- Laxatives, loperamide
- Parenteral nutrition

Pulmonary arterial hypertention

- Prostanoids
- Endothelin receptor antagonist, PDE-5 inhibitor, Riociguat

Lung (interstitial lung disease)

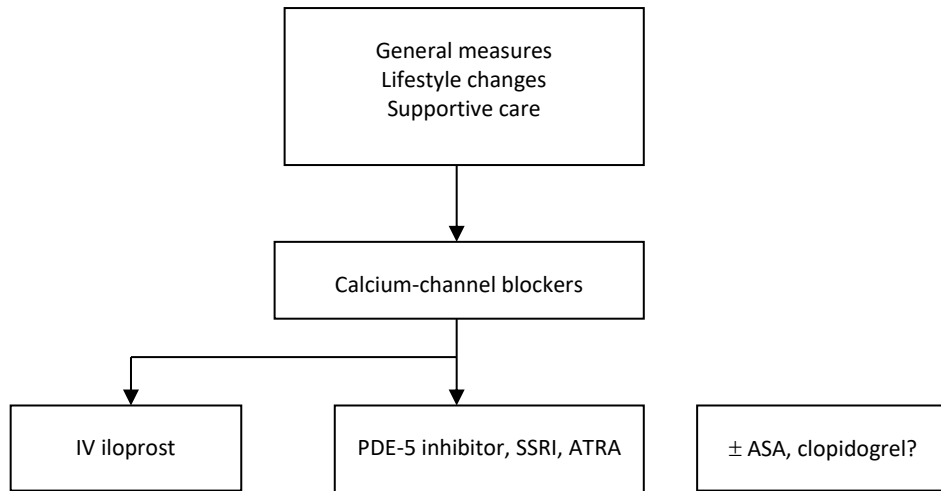
- Cyclophosphamide
- Hematopoietic stem cell transplantation

Kidney

- Angiotensin-converting enzyme inhibitor

PDE, phosphodiesterase.

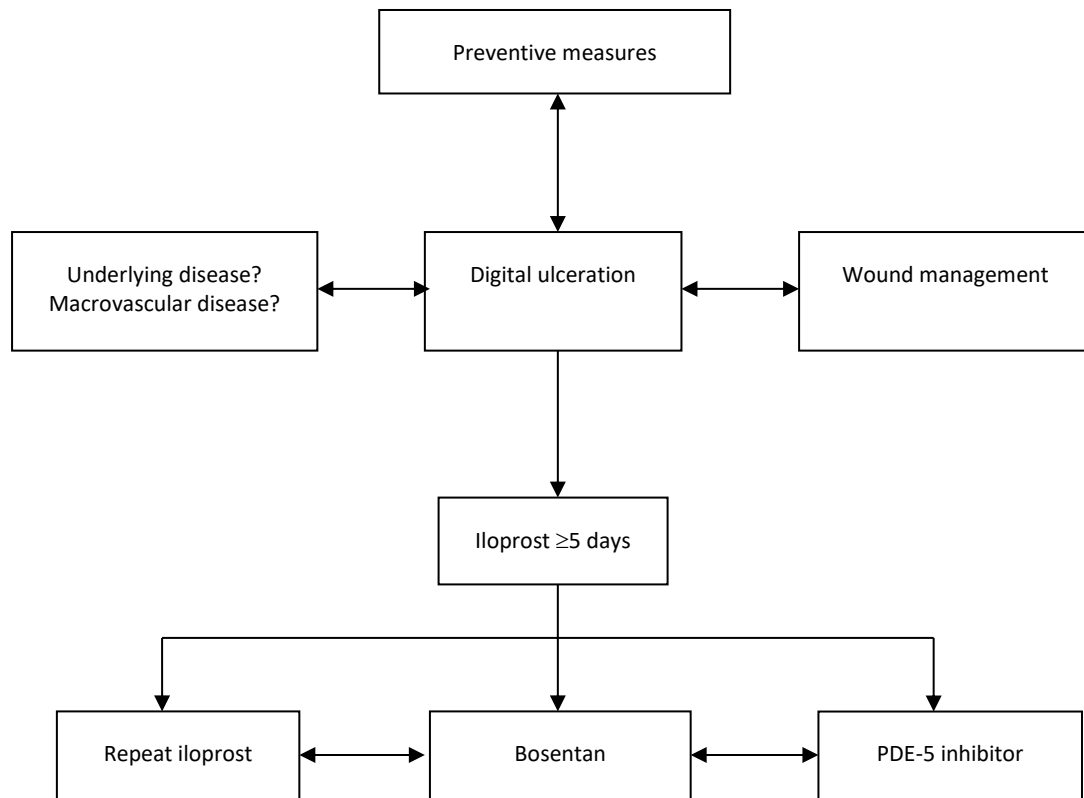
Figure 1 Flow chart for management of Raynaud's phenomenon.



Adapted from Herrick et al., 2012.¹⁴

PDE, phosphodiesterase; SSRI, selective serotonin reuptake inhibitor; ATRA, angiotensin receptor antagonist; ASA, acetylsalicylic acid.

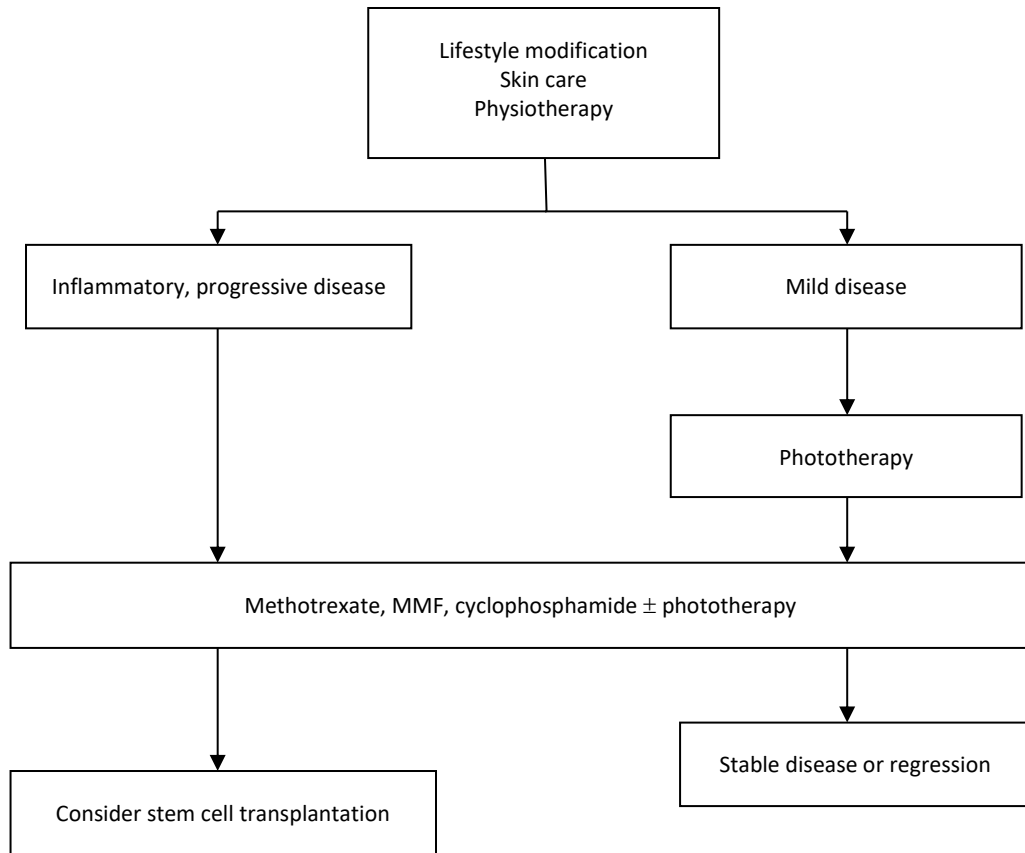
Figure 2 Flow chart for management of digital ulcerations.



Adapted from Riemekasten *et al.*, 2012.⁴⁰

PDE, phosphodiesterase.

Figure 3 Flow chart for therapy of skin fibrosis.



MMF, mycophenolate mofetil.

References

1. Kowal-Bielecka O, Landewé R, Avouac J, Chwiesko S, Miniati I, *et al.* EULAR recommendations for the treatment of systemic sclerosis: a report from the EULAR Scleroderma Trials and Research group (EUSTAR). *Ann Rheum Dis* 2009; **68**: 620–628.
2. UK Scleroderma Study group. *Consensus best practice recommendations for scleroderma*. Available at: <http://www.scleroderma-royalfree.org.uk/UKSSG.html> (last accessed 28 February 2016)
3. Gabrielli A, Avvedimento EV, Krieg T. Scleroderma. *N Engl J Med* 2009; **360**: 1989–2003.
4. Masi AT and Subcommittee for Scleroderma Criteria of the American Rheumatism Association Diagnostic and Therapeutic Criteria Committee (1980). Preliminary criteria for the classification of systemic sclerosis (scleroderma). *Arthritis Rheum* 1980; **23**: 581–590.
5. LeRoy EC, Black C, Fleischmajer R, *et al.* Scleroderma (systemic sclerosis): classification, subsets and pathogenesis. *J Rheumatol* 1988; **15**: 202–205.
6. Mayes MD, Lacey JV Jr, Beebe-Dimmer J, *et al.* Prevalence, incidence, survival, and disease characteristics of systemic sclerosis in a large US population. *Arthritis Rheum* 2003; **48**: 2246–2255.
7. Walker UA, Tyndall A, Czirják L, *et al.* Clinical risk assessment of organ manifestations in systemic sclerosis – a report from the EULAR Scleroderma Trials and Research (EUSTAR) group data base. *Ann Rheum Dis* 2007; **66**: 754–763.
8. Mierau R, Moinzadeh P, Riemekasten G, *et al.* Frequency of disease-associated and other nuclear autoantibodies in patients of the German network for systemic scleroderma: correlation with characteristic clinical features. *Arthritis Res Ther* 2011; **13**: R172.
9. Poormoghim H, Lucas M, Fertig N, Medsger TA Jr. Systemic sclerosis sine scleroderma: demographic, clinical, and serologic features and survival in forty-eight patients. *Arthritis Rheum* 2000; **43**: 444–451.
10. van den Hoogen F, Khanna D, Fransen J, Johnson SR, Baron M, Tyndall A, *et al.* 2013 classification criteria for systemic sclerosis: an American College of Rheumatology/ European League against Rheumatism collaborative initiative. *Ann Rheum Dis* 2013; **72**: 1747–1755.
11. Valentini G. Undifferentiated connective tissue disease at risk for systemic sclerosis (SSc) (so far referred to as very early/early SSc or pre-SSc). *Autoimmun Rev* 2015; **14**: 210–213.

12. Koenig M, Joyal F, Fritzler MJ, *et al.* Autoantibodies and microvascular damage are independent predictive factors for the progression of Raynaud's phenomenon to systemic sclerosis: a twenty-year prospective study of 586 patients, with validation of proposed criteria for early systemic sclerosis. *Arthritis Rheum* 2008; **58**: 3902–3912.
13. Cutolo M, Sulli A, Smith V. How to perform and interpret capillaroscopy. *Best Pract Res Clin Rheumatol* 2013; **27**: 237–248.
14. Herrick AL. The pathogenesis, diagnosis and treatment of Raynaud phenomenon. *Nat Rev Rheumatol* 2012; **8**: 469–479
15. Czirják L, Foeldvari I, Müller-Ladner U. Skin involvement in systemic sclerosis. *Rheumatology* 2008; **47**(Suppl 5): v44–45.
16. Khimdas S, Harding S, Bonner A, *et al.* Associations with digital ulcers in a large cohort of systemic sclerosis: results from the Canadian Scleroderma Research Group registry. *Arthritis Care Res* 2011; **63**:142–149.
17. Mouthon L, Mestre-Stanislas C, Bérezné A, *et al.* Impact of digital ulcers on disability and health-related quality of life in systemic sclerosis. *Ann Rheum Dis* 2010; **69**: 214–217
18. Sunderkoetter, Herrgott I, Brückner C, *et al.* Comparison of patients with and without digital ulcers in systemic sclerosis: detection of possible risk factors. *Br J Dermatol* 2009; **160**: 835–843.
19. Ennis H, Vail A, Wragg E, *et al.* A prospective study of systemic sclerosis-related digital ulcers: prevalence, location, and functional impact. *Scand J Rheumatol* 2013; **42**: 483–486
20. Mihai C, Landewé R, van der Haijde D, *et al.* Digital ulcers predict a worse disease course in patients with systemic sclerosis. *Ann Rheum Dis* 2015; doi: 10.1136/annrheumdis-2014-205897.
21. Hachulla E, Clerson P, Launay D, *et al.* Natural history of ischemic digital ulcers in systemic sclerosis: single-center retrospective longitudinal study. *J Rheumatol* 2007; **34**: 2423–2430.
22. Solomon JJ, Olson AL, Fischer A, Bull T, Brown KK, Raghu G. Scleroderma lung disease. *Eur Respir Rev* 2013; **22**: 6–19.
23. Hoffmann-Vold AM, Aaløkken TM, Lund MB, *et al.* Predictive value of serial high-resolution computed tomography analyses and concurrent lung function tests in systemic sclerosis. *Arthritis Rheumatol* 2015; **67**: 2205–2212.
24. Steen VD, Medsger TA Jr. Changes in causes of death in systemic sclerosis, 1972–2002. *Ann Rheum Dis* 2007; **66**: 940–944.

25. The Joint Task Force for the Diagnosis and Treatment of Pulmonary Hypertension of the European Society of Cardiology (ESC) and the European Respiratory Society (ERS). 2015 ESC/ERS Guidelines for the diagnosis and treatment of pulmonary hypertension. *Eur Respir J* 2015; **46**: 1855–1856
26. Hunzelmann N, Genth E, Krieg T, *et al.* The registry of the German Network for Systemic Scleroderma: frequency of disease subsets and patterns of organ involvement. *Rheumatology* 2008; **47**: 1185–1192.
27. Hansi N, Thoua N, Carulli M, *et al.* Consensus Best Practice pathway of the UK Scleroderma Study Group: gastrointestinal manifestations of systemic sclerosis. *Clin Exp Rheumatol* 2014; **32**(Suppl 86): S-214–221.
28. Vacca A, Meune C, Gordon J, *et al.* Scleroderma Clinical Trial Consortium Cardiac Subcommittee. Cardiac arrhythmias and conduction defects in systemic sclerosis. *Rheumatology* 2014; **53**: 1172–1177.
29. Mouthon L, Bussone G, Berezné A, Noël LH, Guillevin L. Scleroderma renal crisis. *J Rheumatol* 2014; **41**: 1040–1048.
30. Fransen J, Popa-Diaconu D, Hesselstrand R, *et al.* Clinical prediction of 5-year survival in systemic sclerosis: validation of a simple prognostic model in EUSTAR centres. *Ann Rheum Dis* 2011; **70**: 1788–1792
31. Sticherling M. Systemic sclerosis - focus on dermatological aspects. Part 2: diagnostics, therapy. *J Dtsch Dermatol Ges* 2012; **10**: 783–791.
32. Fries R, Shariat K, von Wilmowsky H, Bohm M. Sildenafil in the treatment of Raynaud's phenomenon resistant to vasodilatory therapy. *Circulation* 2005; **112**: 2980–2985.
33. Caglayan E, Huntgeburth M, Karasch T, *et al.* Phosphodiesterase type 5 inhibition is a novel therapeutic option in Raynaud disease. *Arch Intern Med* 2006; **166**: 231–233.
34. Roustit M, Blaise S, Allanore Y, Carpentier PH, Caglayan E, Cracowski JL. Phosphodiesterase-5 inhibitors for the treatment of secondary Raynaud's phenomenon: systematic review and meta-analysis of randomised trials. *Ann Rheum Dis* 2013; **72**: 1696–1699.
35. Coleiro B, Marshall SE, Denton CP, *et al.* Treatment of Raynaud's phenomenon with the selective serotonin reuptake inhibitor fluoxetine. *Rheumatology* 2001; **40**: 1038–1043.
36. Hughes M, Ong VH, Anderson ME, *et al.* Consensus best practice pathway of the UK Scleroderma Study Group: digital vasculopathy in systemic sclerosis. *Rheumatology* 2015; **54**: 2015–2024.

37. Wigley FM, Wise RA, Seibold JR, *et al.* Intravenous iloprost infusion in patients with Raynaud phenomenon secondary to systemic sclerosis. A multicenter, placebo-controlled, double-blind study. *Ann Intern Med* 1994; **120**: 199–206.
38. Pope J, Fenlon D, Thompson A, *et al.* Iloprost and cisaprost for Raynaud's phenomenon in progressive systemic sclerosis. *Cochrane Database Syst Rev* 2000; (2): CD000953.
39. Bali G, Aberer E. Iloprost therapy in systemic sclerosis. *Hautarzt* 2003; **54**: 845–851.
40. Riemekasten G, Hoffmann U, Sunderkötter C, Weiss N, Kuhn A; angiologisch-dermatologisch-rheumatologische DU-Expertenboard. Management of digital ulcers in patients with systemic sclerosis. *Dtsch Med Wochenschr* 2012; **137**: 34–40.
41. Herrick AL. Contemporary management of Raynaud's phenomenon and digital ischaemic complications. *Curr Opin Rheumatol* 2011; **23**: 555–561
42. Tingey T, Shu J, Smuczek J, Pope J. Meta-analysis of healing and prevention of digital ulcers in systemic sclerosis. *Arthritis Care Res* 2013; **65**: 1460–1471.
43. Korn JH, Mayes M, Matucci Cerinic M, *et al.* Digital ulcers in systemic sclerosis: prevention by treatment with bosentan, an oral endothelin receptor antagonist. *Arthritis Rheum* 2004; **50**: 3985–3993.
44. Seibold JR, Denton CP, Furst DE, *et al.* Bosentan prevents occurrence but does not speed healing of digital ulcers in patients with systemic sclerosis (SSc). *Arthritis Rheum* 2005; **52**(Suppl 9): 552.
45. Matucci-Cerinic M, Denton CP, Furst DE, *et al.* Bosentan treatment of digital ulcers related to systemic sclerosis: results from the RAPIDS-2 randomised, double-blind, placebo-controlled trial. *Ann Rheum Dis* 2011; **70**: 32–38.
46. Morita A, Sakakibara S, Sakakibara N, Yamauchi R, Tsuji T. Successful treatment of systemic sclerosis with topical PUVA. *J Rheumatol* 1995; **22**: 2361–2365.
47. Kreuter A, Breuckmann F, Uhle A, *et al.* Low-dose UVA1 phototherapy in systemic sclerosis: effects on acrosclerosis. *J Am Acad Dermatol* 2004; **50**: 740–747.
48. Connolly KL, Griffith JL, McEvoy M, Lim HW. Ultraviolet A1 phototherapy beyond morphea: experience in 83 patients. *Photodermatol Photoimmunol Photomed* 2015; **31**: 289–295.
49. Rook AH, Freundlich B, Jegasothy BV, *et al.* Treatment of systemic sclerosis with extracorporeal photochemotherapy. Results of a multicenter trial. *Arch Dermatol* 1992; **128**: 337–346.
50. Knobler RM, French LE, Kim Y, *et al.* A randomized, double-blind, placebo-controlled trial of photopheresis in systemic sclerosis. *J Am Acad Dermatol* 2006; **54**: 793–799.

51. Knobler R, Berlin G, Calzavara-Pinton P, *et al.* Guidelines on the use of extracorporeal photopheresis. *J Eur Acad Dermatol Venereol* 2014; **28**(Suppl 1): 1–37.
52. van den Hoogen FH, Boerbooms AM, Swaak AJ, Rasker JJ, van Lier HJ, van de Putte LB. Comparison of methotrexate with placebo in the treatment of systemic sclerosis: a 24 week randomized double-blind trial, followed by a 24 week observational trial. *Br J Rheumatol* 1996; **35**: 364–372.
53. Pope JE, Bellamy N, Seibold JR, *et al.* A randomized, controlled trial of methotrexate versus placebo in early diffuse scleroderma. *Arthritis Rheum* 2001; **44**: 1351–1358.
54. Walker KM, Pope J, participating members of the Scleroderma Clinical Trials Consortium (SCTC); Canadian Scleroderma Research Group (CSRG). Treatment of systemic sclerosis complications: what to use when first-line treatment fails-a consensus of systemic sclerosis experts. *Semin Arthritis Rheum* 2012; **42**: 42–55.
55. Tashkin DP, Elashoff R, Clements PJ, *et al.* Cyclophosphamide versus placebo in scleroderma lung disease. *N Engl J Med* 2006; **354**: 2655–2666.
56. Balin SJ, Wetter DA, Andersen LK, Davis MD. Calcinosis cutis occurring in association with autoimmune connective tissue disease: the Mayo Clinic experience with 78 patients, 1996–2009. *Arch Dermatol* 2012; **148**: 455–462.
57. Wu JJ, Metz BJ. Calcinosis cutis of juvenile dermatomyositis treated with incision and drainage. *Dermatol Surg* 2008; **34**: 575–577.
58. Saddic N, Miller JJ, Miller OF 3rd, Clarke JT. Surgical debridement of painful fingertip calcinosis cutis in CREST syndrome. *Arch Dermatol* 2009; **145**: 212–213.
59. Murray AK, Moore TL, Richards H, Ennis H, Griffiths CE, Herrick AL. Pilot study of intense pulsed light for the treatment of systemic sclerosis-related telangiectases. *Br J Dermatol* 2012; **167**: 563–569.
60. Halachmi S, Gabari O, Cohen S, Koren R, Amitai DB, Lapidot M. Telangiectasis in CREST syndrome and systemic sclerosis: correlation of clinical and pathological features with response to pulsed dye laser treatment. *Lasers Med Sci* 2014; **29**: 137–140.
61. Dinsdale G, Murray A, Moore T, *et al.* A comparison of intense pulsed light and laser treatment of telangiectases in patients with systemic sclerosis: a within-subject randomized trial. *Rheumatology* 2014; **53**: 1422–1430.
62. Lee JS, Collard HR, Anstrom KJ, *et al.* Anti-acid treatment and disease progression in idiopathic pulmonary fibrosis: an analysis of data from three randomized controlled trials. *Lancet Respir Med* 2013; **1**: 369–376.

63. Van Laar JM, Farge D, Sont JK, *et al.* Autologous hematopoietic stem cell transplantation vs intravenous pulse cyclophosphamide in diffuse cutaneous systemic sclerosis: a randomized clinical trial. *JAMA* 2014; **311**: 2490–2498.
64. Burt RK, Shah SJ, Dill K, *et al.* Autologous non-myeloablative haemopoietic stem-cell transplantation compared with pulse cyclophosphamide once per month for systemic sclerosis (ASSIST): an open-label, randomised phase 2 trial. *Lancet* 2011; **378**: 498–506.
65. Ntoumazios SK, Voulgari PV, Potsis K, Koutis E, Tsifetaki N, Assimakopoulos DA. Esophageal involvement in scleroderma: gastroesophageal reflux, the common problem. *Semin Arthritis Rheum* 2006; **36**: 173–181.
66. Nikou GC, Toumpanakis C, Katsiari C, Charalambopoulos D, Sfikakis PP. Treatment of small intestinal disease in systemic sclerosis with octreotide: a prospective study in seven patients. *J Clin Rheumatol* 2007; **13**: 119–123.
67. Frech TM, Khann D, Maranian P, *et al.* Probiotics for the treatment of systemic sclerosis-associated gastrointestinal bloating/distention. *Clin Exp Rheumatol* 2011; **29**(2 Suppl 65): S22–25.
68. Knafo R, Haythornthwaite JA, Heinberg L, Wigley FM, Thombs BD. The association of body image dissatisfaction and pain with reduced sexual function in women with systemic sclerosis. *Rheumatology* 2011; **50**: 1125–1130.
69. Foocharoen C, Tyndall A, Hachulla E, *et al.* Erectile dysfunction is frequent in systemic sclerosis and associated with severe disease: a study of the EULAR Scleroderma Trial and Research group. *Arthritis Res Ther* 2012; **14**: R37

IV Nephrogenic systemic fibrosis

Definition

Nephrogenic fibrosing dermopathy, a dermatologic form of the generic term nephrogenic systemic fibrosis (NSF), is a relatively new disease entity. It was first reported in 2000 and is believed to be seen almost only in patients with moderate-to-severe kidney failure, particularly patients on dialysis.¹ It was linked to the usage of gadolinium-based contrast agents (GBCAs) in magnetic resonance imaging (MRI), which were adopted in the late 1990s for use in patients with impaired renal function, as it was widely accepted that these agents were not nephrotoxic.²

Epidemiology

Depending on the type of gadolinium used for the imaging process, the incidence rate of NSF may vary and, for gadodiamide, it has been estimated to be between 3% and 7% in patients with renal insufficiency.³ Accumulating reports on clinically relevant fibrosing processes led to the release in 2006 of an alert by the US Food and Drug Administration (FDA) regarding the use of GBCA in patients with renal insufficiency.⁴ Based on multicenter retrospective reviews^{5,6} and a European Medicines Agency (EMA) report,⁷ important risk factors for NSF have been identified (Table 1). Other incriminated factors such as erythropoietin, which gained widespread use at the time NSF emerged, or hepatic insufficiency, could not be confirmed. The adapted, selective use of GBCA thereafter led to a reduction in the incidence of NSF to zero – or almost zero.¹⁰ However, as there is no mandatory reporting system for NSF, and given that the only NSF registry (with over 380 reported cases) was last updated back in June 2013,¹¹ the decline in the number of publications reporting new cases has to be taken as a surrogate marker for the assumed reduction in incidence.

<TABLE 1>

Pathogenesis

It has been proposed that excess GBCA in patients with renal insufficiency undergoing MRI may be deposited in the tissue upon transmetallation. GBCAs include lanthanides, which were reported to induce profibrogenic processes decades ago.^{12,13} More recently, chelated gadodiamide and gadopentetate forms of GBCA specifically have been shown to increase the release of profibrotic cytokines and growth factors in macrophages/monocytes in vitro within

minutes upon receptor-mediated cellular uptake.¹⁴ The exact mechanism of increased collagen bundle deposition in skin and other organs has not yet been fully understood.

On routine light microscopy, depending on the disease severity, a deep biopsy may show fibrocyte proliferation ranging from subtle proliferation of dermal fibrocytes in early lesions to florid proliferation. Thick collagen bundles with surrounding clefts are a prominent finding, with a variable increase in dermal mucin and elastin. Immunohistochemical staining shows CD34+ dermal dendritic cells. Gadolinium may be visualized with special testing but is not diagnostic.¹⁵

Clinical manifestation

NSF is a rare differential diagnosis of other sclerosing skin processes that may occur in patients with impaired renal function, such as scleromyxedema, lipodermatosclerosis, eosinophilic fasciitis, or localized and systemic sclerosis. Initial symptoms include hyperpigmented skin areas and papules, which may coalesce to patches and plaques with a peau d'orange appearance. NSF commonly forms symmetrical lesions, which are predominantly located on the lower legs, and develops within the first 2–8 weeks after exposure to GBCA.¹⁰ Pain and pruritus are frequent symptoms, but unlike in eosinophilic fasciitis, fever, arthritis and malaise are uncommon.¹⁶ Unlike systemic sclerosis, Raynaud's phenomenon is typically absent. Systemic involvement has been described (scleral plaques, muscle fibrosis and induration, flexion contractures, fibrosis of vessel walls of internal organs such as lung and kidney, calcification of the soft tissue). The sclerosing process may proceed within days or weeks, but delayed onset of NSF has been described up to 10 years after gadolinium uptake.¹⁷ NSF has been documented in all age groups, including in children.¹⁸

Diagnostic procedures

There is no specific test available for the diagnosis of NSF. Abnormal creatinine and increased blood urea nitrogen are to be considered in the context of the pre-existing renal insufficiency. Antinuclear antibodies and rheumatoid factors are typically negative, and there is no association with paraproteinemia. Some patients show eosinophilia in the peripheral blood. Girardi *et al.*, proposed a scoring system that has been tested on the reported cases in the NSF registry.¹⁹ (Table 2, Fig. 1). The variety of clinical findings in NSF are classified into major (patterned plaques of the skin, joint contractures, cobblestone appearance of the skin, peau d'orange) and minor (linear banding of the skin, superficial plaque/patch, dermal papules, scleral plaques in

patients aged <45 years) clinical criteria, and a clinicopathologic scoring system has been proposed in order to allow the diagnostic of NSF.¹⁹ As the incidence of NSF appears to diminish, evaluation of this scoring system will be a difficult task. Nevertheless, the use of this score will aid the standardization of diagnostic procedures for NSF, and may be helpful to differentiate between borderline cases of NSF and other sclerosing skin disorders.

<TABLE 2>

<Fig. 1>

Treatment

Established NSF lesions do not respond to systemic or local glucocorticoid treatment or to other immunosuppressive drugs. Other approaches such as extracorporeal photopheresis, UVA1 phototherapy, plasmapheresis, or imatinib mesylate have been used with inconsistent clinical improvement.^{20–27} Based on the published data, no specific therapeutic recommendation can be made. Reconstitution of renal function is considered the best therapeutic approach.²⁸ Prevention consists of avoidance of gadolinium-containing contrast agents in patients with an estimated glomerular filtration rate of <30 mL/min. If clinical conditions require the use of gadolinium, then, in order to reduce the risk of NSF development, and based on the recommendations of the FDA and EMA, low-risk gadolinium media should be the contrast agents of choice. Doses of GBCA should be reduced to the minimum effective dosage for imaging.^{7,8} Based on the dialysability of GBCA, it is recommended that at least one full 4-hour dialysis session is performed after GBCA-based MRI in patients with renal insufficiency; this should remove 97% of the GBCA that was present prior to dialysis. Three full sessions of dialysis increase the GBCA clearance up to 99.7%.²⁹

Conclusions

NSF is an iatrogenic condition observed in patients with end-stage renal failure and is associated with gadolinium exposure. No treatments with proven efficacy based on randomised controlled trials are available. Avoidance of high-risk GBCA is the key prophylactic measure. Prophylactic measures have led to a significant drop in incidence of NSF.³⁰

Table 1 Risk factors for nephrogenic systemic fibrosis⁵⁻⁹

Use of GBCA-based MRI in patients with acute or chronic renal insufficiency (GFR <30 mL/min/1.73m²)

Use of higher-than-standard dose of GBCA for MRI

Current inflammatory or thrombotic episodes in patient

Risk stratification based on GBCA type

High-risk GBCA

- Linear non-ionic chelates (gadoversetamide [OptiMARK[®]], gadiodiamide [Omniscan[®]])
- Linear ionic chelates (gadopentetic acid [Magnevist[®], Gado-MRT-ratiopharm[®], Magnebita[®], Marktiv[®]])

Medium-risk GBCA

- Linear ionic chelates including gadofosveset trisodium (Vasovist[®]), gadoxetic acid disodium (Primovist[®]), and gadobenate dimeglumine (MultiHance[®])

Low-risk GBCA

- Macrocyclic chelates (gadoteric acid [Dotarem[®]], gadoteridol [ProHance[®]], gadobutrol [Gadovist[®]])

GBCA, gadolinium-based contrast agents; GFR, glomerular filtration rate; MRI, magnetic resonance imaging.

Table 2 Girardi score for diagnosis of NSF¹⁹

Clinical findings

Major criteria

- Patterned plaques
- Joint contractures
- “Cobblestoning”
- Marked induration/Peau d’orange

Minor criteria

- Puckering/linear banding
- Superficial plaque/patch
- Dermal papules
- Scleral plaques (age <45 years)

Histologic findings

- Increased dermal cellularity (score +1)
- CD34+ cells with tram-tracking (score +1)
- Thick and thin collagen bundles (score +1)
- Preserved elastic fibers (score -1 if absent)
- Septal involvement (score +1)
- Osseous metaplasia (score +3)

Figure 1 Girardi score table based on clinical and histologic scoring (see Table 2).¹⁹

Pathology score	Clinical score									
	0	1	2	3	4					
0	Alternative Diagnose									
1						Not NSF			Inconsistent with NSF	
2								Suggestive for NSF	Consistent with NSF	
3								Consistent with NSF	NSF	
4						Inconsistent with NSF				

NSF, nephrogenic systemic fibrosis.

References

1. Gathings RM, Reddy R, Santa Cruz D, Brodell RT. Gadolinium-associated plaques: a new, distinctive clinical entity. *JAMA Dermatol* 2015; **151**: 316–319.
2. Prince MR, Arnoldus C, Frisoli JK. Nephrotoxicity of high-dose gadolinium compared with iodinated contrast. *J Magn Reson Imaging* 1996; **6**: 162–166.
3. Thomsen HS, Marckmann P. Extracellular Gd-CA: differences in prevalence of NSF. *Eur J Radiol* 2008; **66**: 180–183.
4. US Food and Drug administration. Public Health Advisory – Gadolinium-containing contrast agents for magnetic resonance imaging (MRI). Available at: <http://www.fda.gov/Drugs/DrugSafety/PostmarketDrugSafetyInformationforPatientsandProviders/ucm053112.htm>. (Last accessed 5 October 2015.)
5. Prince MR, Zhang H, Morris M, *et al.* Incidence of nephrogenic systemic fibrosis at two large medical centers. *Radiology* 2008; **248**: 807–816.
6. Wertman R, Altun E, Martin DR, *et al.* Risk of nephrogenic systemic fibrosis: evaluation of gadolinium chelate contrast agents at four American universities. *Radiology* 2008; **248**: 799–806.
7. European Medicines Agency. Assessment report for Gadolinium-containing contrast agents. Available at: http://www.ema.europa.eu/docs/en_GB/document_library/Referrals_document/gadolinium_31/WC500099538.pdf. (Last accessed 5 October 2015.)
8. Khawaja AZ, Cassidy DB, Al Shakarchi J, McGrogan DG, Inston NG, Jones RG. Revisiting the risks of MRI with Gadolinium based contrast agents-review of literature and guidelines. *Insights Imaging* 2015; **6**: 553–558.
9. Sadowski EA, Bennett LK, Chan MR, *et al.* Nephrogenic systemic fibrosis: risk factors and incidence estimation. *Radiology* 2007; **243**: 148–157.
10. Thomsen HS, Morcos SK, Almen T, *et al.* Nephrogenic systemic fibrosis and gadolinium-based contrast media: updated ESUR Contrast Medium Safety Committee guidelines. *Eur Radiol* 2013; **23**: 307–318.
11. The International Center for Nephrogenic Systemic Fibrosis Research (ICNSFR). Available at: <http://www.icnfd.org/>. (Last accessed 5 October 2015.)
12. Evans CH, Drouven BJ. The promotion of collagen polymerization by lanthanide and calcium ions. *Biochem J* 1983; **213**: 751–758.
13. Drouven BJ, Evans CH. Collagen fibrillogenesis in the presence of lanthanides. *J Biol Chem* 1986; **261**: 11792–11797.

14. Newton BB, Jimenez SA. Mechanism of NSF: new evidence challenging the prevailing theory. *J Magn Reson Imaging* 2009; **30**: 1277–1283.
15. Galan A, Cowper SE, Bucala R. Nephrogenic systemic fibrosis (nephrogenic fibrosing dermatopathy). *Curr Opin Rheumatol* 2006; **18**: 614–617.
16. Cowper SE. Nephrogenic fibrosing dermatopathy: the first 6 years. *Curr Opin Rheumatol* 2003; **15**: 785–790.
17. Larson KN, Gagnon AL, Darling MD, Patterson JW, Cropley TG. Nephrogenic systemic fibrosis manifesting a decade after exposure to gadolinium. *JAMA Dermatol* 2015; **151**: 1117–1120.
18. Jan F, Segal JM, Dyer J, LeBoit P, Siegfried E, Frieden IJ. Nephrogenic fibrosing dermatopathy: two pediatric cases. *J Pediatr* 2003; **143**: 678–681.
19. Girardi M, Kay J, Elston DM, Leboit PE, Abu-Alfa A, Cowper SE. Nephrogenic systemic fibrosis: clinicopathological definition and workup recommendations. *J Am Acad Dermatol* 2011; **65**: 1095–1106 e7.
20. Mathur K, Morris S, Deighan C, Green R, Douglas KW. Extracorporeal photopheresis improves nephrogenic fibrosing dermatopathy/nephrogenic systemic fibrosis: three case reports and review of literature. *J Clin Apher* 2008; **23**: 144–150.
21. Tran KT, Prather HB, Cockerell CJ, Jacobe H. UV-A1 therapy for nephrogenic systemic fibrosis. *Arch Dermatol* 2009; **145**: 1170–1174.
22. Tsagalis G, Psimenou E, Laggouranis A. Combination treatment with plasmapheresis and sirolimus does not seem to benefit nephrogenic systemic fibrosis. *Int J Artif Organs* 2008; **31**: 913–914.
23. Elmholdt TR, Buus NH, Ramsing M, Olesen AB. Antifibrotic effect after low-dose imatinib mesylate treatment in patients with nephrogenic systemic fibrosis: an open-label non-randomized, uncontrolled clinical trial. *J Eur Acad Dermatol Venereol* 2013; **27**: 779–784.
24. Gilliet M, Cozzio A, Burg G, Nestle FO. Successful treatment of three cases of nephrogenic fibrosing dermatopathy with extracorporeal photopheresis. *Br J Dermatol* 2005; **152**: 531–536.
25. Lauchli S, Zortea-Cafilisch C, Nestle FO, Burg G, Kempf W. Nephrogenic fibrosing dermatopathy treated with extracorporeal photopheresis. *Dermatology* 2004; **208**: 278–280.
26. Richmond H, Zwerner J, Kim Y, Fiorentino D. Nephrogenic systemic fibrosis: relationship to gadolinium and response to photopheresis. *Arch Dermatol* 2007; **143**: 1025–1030.

27. Kintossou R, D'Incan M, Chauveau D, *et al.* [Nephrogenic fibrosing dermopathy treated with extracorporeal photopheresis: role of gadolinium?] *Ann Dermatol Venereol* 2007; **134**: 667–671.
28. Cuffy MC, Singh M, Formica R, *et al.* Renal transplantation for nephrogenic systemic fibrosis: a case report and review of the literature. *Nephrol Dial Transplant* 2011; **26**: 1099–1101.
29. Gheuens E, Daelemans R, Mesens S. Dialysability of gadoteric acid in patients with end-stage renal disease undergoing hemodialysis. *Invest Radiol* 2014; **49**: 505–508.
30. Bennett CL, Qureshi ZP, Sartor AO, *et al.* Gadolinium-induced nephrogenic systemic fibrosis: the rise and fall of an iatrogenic disease. *Clin Kidney J* 2012; **5**: 82–88.

V Systemic sclerosis overlap syndromes

Introduction

Systemic sclerosis (SSc) overlap syndrome is a term used to describe a very heterogeneous group of patients with features of different connective tissue diseases, combined with clinical signs of SSc.¹⁻³ To date, no firm classification criteria for SSc overlap syndromes have been established, but they are generally considered when musculoskeletal involvement or features of other rheumatic diseases are significantly greater than usually found in general SSc patients.^{4,5} Other autoimmune rheumatic disorders are classified depending on internationally accepted classification systems.⁶⁻¹⁰ Most SSc overlap syndromes appear to encompass a subtype of SSc similar to limited cutaneous SSc (lcSSc), but with more frequent involvement of the musculoskeletal system than in lcSSc or diffuse cutaneous (dcSSc), and an apparently earlier onset of lung fibrosis or heart involvement.⁵

Epidemiology

SSc overlap syndromes represent the third major subgroup of SSc, and epidemiologic studies report divergent frequencies (incidence and prevalence rates are not reported yet) of overlap subgroups, ranging between 9% and 38% (Table 1).^{1,2,4,5}

The most common SSc overlap syndromes are SSc and myositis (polymyositis or dermatomyositis), SSc and rheumatoid arthritis, SSc and Sjögren's, and SSc and systemic lupus erythematosus (SLE) overlap syndromes.⁴ Pakozdi *et al.* reported recently that 20% of SSc patients attending the Centre for Rheumatology at the Royal Free Hospital (London, UK) had features overlapping with other rheumatologic diseases. Of these 43% overlapped with polymyositis/dermatomyositis, 8% with SLE, 17% with Sjögren's syndrome, and 32% with rheumatoid arthritis.⁴ The German Network for Systemic Scleroderma (DNSS) reported that 10% of the registered patients suffered from SSc overlap syndromes.⁵

A recent meta-analysis has revealed that the mean age at diagnosis of patients with SSc overlap syndromes was 47.6 years (SD 2.6), and that it was found more often in European patients than in patients from North America.¹¹

Balbir-Gurman reported that the overall mortality in their SSc overlap cohort did not differ from other SSc patients.¹ Depending on different geographical regions/centers, a wide range of frequencies of SSc overlap syndromes have been reported (Table 1).

<TABLE 1>

Pathogenesis

To date, the pathogenesis of SSc overlap syndromes remains unclear. The question of why some patients develop only one connective tissue disease and other patients have a combination of clinical features of different rheumatic diseases has not yet been answered. A common or overlapping genetic susceptibility possibly plays an important role. Genetic studies have shown the existence of some susceptibility genes, which predispose to multiple autoimmune diseases.¹¹ Koumakis *et al.* reported that a regulatory gene located in the TNFAIP3 region is associated with a higher risk of developing SSc polyautoimmunity.^{11,16}

Clinical manifestations

Clinical features of SSc overlap syndrome are very heterogeneous. Patients usually present with skin sclerosis typical of lcSSc, although organ manifestations clearly separate these patients as distinct subset.⁵ A German study showed that patients suffering from SSc overlap syndromes developed an involvement of the musculoskeletal system significantly earlier and more often than patients with dcSSc and lcSSc. In addition, they interestingly developed lung fibrosis and heart involvement significantly earlier and more often than lcSSc patients, but still less frequently and later than dcSSc patients.⁵

Therefore, the identification of these patients is essential for clarifying prognosis and facilitating therapeutic options. The clinical signs include both cutaneous and extracutaneous features, depending on the overlapping connective tissue disease (CTD), and often overlap between the different overlap forms, especially regarding vasculopathy, gastrointestinal and cardiopulmonary involvement.

For more details on the following conditions, please refer to Section III (*Systemic sclerosis*).

Raynaud's phenomenon

Raynaud's phenomenon is also a very common feature in patients with SSc overlap syndromes.³ Some SSc overlap patients also develop digital ulcerations but significantly less often compared with lcSSc and dcSSc patients.⁵

Skin sclerosis

The skin sclerosis in patients with SSc overlap syndromes can be generalized, similar to the diffuse form of SSc, but more frequently it is only located below the elbow and knee joints, which is similar to the limited form of SSc.^{4,5}

Calcinosis cutis

Calcinosis cutis can be also observed in patients with SSc overlap syndromes. It is associated with longer disease duration, positive anti-centromere and anti-PM/Scl antibodies, and occurs usually over pressure points (acral or next to joints).¹⁷

Gastrointestinal involvement

As in SSc the involvement of the gastrointestinal tract is probably the most common internal organ system involved (approx. 50–60%).^{5,14}

Lung fibrosis and myocardial involvement

Lung fibrosis and myocardial involvement are significantly less frequent than in patients with diffuse SSc, but significantly more frequent than in limited forms of SSc.⁵

Pulmonary arterial hypertension

Pulmonary arterial hypertension (PAH) occurs less frequently in patients with SSc overlap syndromes than in patients with dcSSc, but similarly to those with the limited form of SSc.⁵

Clinical characteristics of systemic sclerosis overlap syndromes

Systemic sclerosis and myositis

Myositis is the most frequent systemic involvement in patients with SSc overlap syndromes. In some SSc patients, muscle weakness, pain, and atrophy result from disuse secondary to joint contractures, dermatogenous contractures, or chronic disease. However, significantly more patients with SSc overlap syndromes present with myositis, characterized by proximal muscle weakness with no loss of reflexes or sensitivity, myalgia, increased creatine kinase serum levels, and later atrophy of muscles. Patients suffering from SSc-myositis overlap syndrome may

develop myositis simultaneously, before, or in already established SSc.¹ Some patients may show cutaneous symptoms of dermatomyositis. The limited extent of skin thickening is still the most frequent form in patients with SSc overlap syndromes.^{1,4,5}

Recent studies have shown that an increased proportion of patients also develop lung fibrosis,^{5,18} which is in line with a high percentage (up to 30%) of interstitial lung disease (ILD) in patients with dermatomyositis. Patients with SSc-myositis overlap syndromes have a higher risk of developing a diffuse interstitial myocardial fibrosis, which may lead to diastolic dysfunctions as well as restricted contractibility of the myocardium. These patients typically present symptoms, such as cardiac arrhythmia, paroxysmal tachycardia, incomplete or complete right-heart blocks, finally leading to heart insufficiency. The frequency of lung and gastrointestinal involvement varies among studies, ranging between 32.0% and 78.1%.²

It is well established that patients suffering from the SSc-myositis overlap syndrome (except those with antibody to PM/Scl) have a worse prognosis due to an increased risk of myocardial involvement compared with patients with only SSc.¹⁸ SSc-myositis overlap syndromes may be associated with specific autoantibodies, including PM/Scl, anti-Ku, anti-U2RNP, and anti-U5snRNP (Table 2).^{1,19} Patients, carrying the antibody to PM/Scl are usually younger, have limited skin involvement, and suffer from arthritis and a benign course of ILD,¹ which is also the reason for their better survival.¹⁵ Positive antibodies against Ku are more characteristic for patients suffering from muscle involvement as well as severe ILD (Table 1).²³

<TABLE 2>

Systemic sclerosis and rheumatoid arthritis

Joint involvement is reported to be the second most frequent manifestation in patients with musculoskeletal involvement and overlap syndromes.⁴ These patients may present with typical clinical symptoms (usually limited skin involvement, morning stiffness, arthritis), together with high titers of anti-cyclic citrullinated peptides (CCP/ACPA) and/or higher rheumatoid factors (SSc-RA overlap syndrome). However, it is often very difficult to distinguish between SSc patients with mild, sero-negative arthralgia and the significant arthritis associated with SSc-RA overlap syndrome.

Systemic sclerosis and systemic lupus erythematosus

This subtype is a very rare condition.²⁴ Patients often have a fatal course of the disease due to a higher risk of developing polyserositis, pancreatitis, avascular bone necrosis, PAH, lung involvement, lupus glomerulonephritis, skin rashes, and leukoencephalopathy.¹ It is also difficult to distinguish whether the patient suffers from a lupus-nephritis or a scleroderma renal crisis. Depending on the reason for renal failure, patients need a different therapeutic strategy to improve renal function. Skin lesions can be a major esthetic disturbing factor, because of the predilection for the face. These patients usually have a combination of SSc-associated antibodies and double-stranded DNA antibodies.

Systemic sclerosis and Sjögren's syndrome

This SSc overlap syndrome was first described in 1965 by Bloch *et al.*²⁵ Xerostomia and xerophthalmia are very common in patients suffering from SSc (68–83%), but only 14–20% of SSc patients really fulfill the criteria of Sjögren's syndrome,²⁶ so that the diagnosis of SSc/SS overlap syndromes is always a challenge.²⁷ It is defined by a lymphocytic infiltration of the salivary glands. Patients with SSc-SS overlap syndrome show a limited form of skin involvement (83.6% vs 16.4%) and a very low frequency of lung involvement.¹ Antibodies against Ro are very likely in SSc-SS overlap syndromes, often together with anti-centromere antibodies (ACA).⁴

Mixed connective tissue disease

Mixed connective tissue disease (MCTD) was first described by Sharp *et al.* in 1972.²⁸ These patients present clinical symptoms typically found in patients with myositis, SLE, inflammatory arthritis (RA) and SSc. Typical for this condition are puffy fingers (50%), polyarthritis (65%), Raynaud's phenomenon (53%), sclerodactyly (35%), muscle involvement, and esophageal involvement.^{20,29} and the occurrence of high antinuclear antibodies titers with high levels of U1snRNP antibodies, which helps to differentiate MCTD from other connective tissue diseases. Arthralgia occurs in approximately 60% of patients, and muscle disease is present in 80–90% of cases with proximal muscle involvement and elevation of serum creatine kinase levels.²⁹ Cardiovascular involvement (lung fibrosis and especially PAH) is less frequent, but is a major contributor to a poor outcome/prognosis.²⁰

SSc may also occur together with other organ-specific autoimmune diseases, such as autoimmune hepatitis/primary biliary cirrhosis, autoimmune thyroiditis, sarcoidosis, and antiphospholipid syndrome (Table 3).

<TABLE 3>

Diagnostic procedures

Muscle involvement (myositis/myopathy)

Typical clinical symptoms include a symmetrical proximal muscle weakness, muscle pain, and/or muscle atrophy with intact reflexes and sensitivity. Serologic tests usually show an elevation of serum creatine phosphokinase (≥ 4 -fold) and acute phase parameters in blood (e.g. C-reactive protein and erythrocyte sedimentation rate). An electromyography, magnetic resonance imaging (MRI), and muscle biopsy will help to identify affected muscles.^{6,7,14,30}

Sjögren's symptoms

Due to a reduced glandular function, patients with SSc-Sjögren's overlap syndrome suffer from dry mouth (xerostomia) and dry eyes (xerophthalmia). In addition, these patients also typically show anti-Ro and anti-La antibodies, often together with anti-centromere antibodies. Further diagnostics include functional tests for ocular and oral sicca symptoms, together with a glandular biopsy.³¹

Joint involvement

A rheumatologic examination is essential to identify rheumatoid arthritis. Joint involvement can be due to dermatogenous contractures or inflammation. It is recommended to examine the rheumatoid factor and anti-CCP antibodies in the serum of affected patients. X-ray, ultrasound of affected joints, as well as MRI scans can be helpful tools to identify inflammation areas and damage of the joints.¹⁴

Kidney involvement

Creatinine clearance, urine analysis to control proteinuria and hematuria, as well as regular blood pressure tests are necessary for the early identification of renal involvement.^{14,32} In patients with SSc-SLE overlap syndromes it may be necessary to perform a kidney biopsy to distinguish between renal failures due to lupus nephritis³³ (see also the ACR/EULAR guidelines on SLE) or scleroderma renal crisis³² (see also Section III – *Systemic sclerosis*).³²

For more details on diagnostic procedures and SSc-associated organ manifestations/ complications see Section III (*Systemic sclerosis*).

<FIG. 1>

Treatment

There have been major advances in treating many of the organ-specific complications of SSc and overlapping diseases. See also Section III (*Systemic sclerosis*).

Systemic glucocorticoids

Systemic glucocorticoids can be used for musculoskeletal involvement together with other immunosuppressive agents. The use of high-dose glucocorticoids should be used with caution due to the increased risk of renal crisis in SSc patients with diffuse extent of skin involvement.²

Methotrexate

Methotrexate is a well-known immunosuppressive agent that has been used in adults and children, with well-documented side-effects. Methotrexate is still a first-line therapy in many autoimmune diseases. It is the treatment of choice in patients with SSc-myositis and SSc-RA overlap syndromes.^{34,35}

Mycophenolat mofetil

MMF is a well-tolerated immunosuppressive agent, which is recommended as long-term therapy in scleroderma and has successfully been applied in several overlap syndromes.

Azathioprine

This immunosuppressive agent is usually well tolerated and has been used successfully in patients with MCTD as well as patients with SSc-SLE overlap. However, compared with MMF, side-effects seem to be more pronounced and the response to the therapy more limited.

Cyclophosphamide

Cyclophosphamide is often used for lung involvement in patients with SSc,³⁶ and also SSc-myositis overlap or SSc-SLE overlap syndromes, in case of lupus nephritis. Cyclophosphamide

should be used for musculoskeletal involvement as a second-line immunosuppressive therapy after other treatments (methotrexate, MMF) have failed or cannot be used due to defined side-effects. As in other autoimmune diseases, it can be used as intravenous pulse or oral treatment.

Bioimmunomodulatory agents

Only limited information is available for the use of intravenous immunoglobulin (IVIg), rituximab, and anti-tumor necrosis factor (TNF) in the treatment of overlap syndromes.

Therapeutic approaches

Systemic sclerosis and myositis

In this group of patients, treatment is mainly directed against muscle inflammation, alveolitis, and skin sclerosis (Fig. 2).

Glucocorticoid therapy (not in patients with a higher risk for renal crisis (see Section III – *Systemic sclerosis*), methotrexate (not in case of alveolitis), azathioprine, IVIg, cyclophosphamide, and rituximab (in patients with uncontrolled myositis) may be helpful agents.

Agents of choice in mild cases are methotrexate together with low-dose glucocorticoids. In severe cases, IVIg can be added. In patients with a refractory course of the disease, cyclophosphamide (also known to improve skin and lung involvement), MMF (also known to improve skin thickening), or rituximab (also known to improve skin and lung involvement) can be tried to improve clinical symptoms.^{1,37–39}

Systemic sclerosis and rheumatoid arthritis

These patients are usually treated with hydroxychloroquine, possibly together with methotrexate and low-dose glucocorticoids. If this therapeutic strategy is not effective, tocilizumab, rituximab as well as anti-TNF agents should be considered. All these treatments have to be used with caution, in the context of serious infections, tuberculosis, and fibrosis.

For further details see Section III (*Systemic sclerosis*) and ACR/EULAR guidelines on rheumatoid arthritis.⁴⁰

Systemic sclerosis and systemic lupus erythematosus

Treatment in patients with cutaneous lesions due to SLE should start with topical glucocorticoid therapy, together with UV skin protection. The topical treatment can be combined with hydroxychloroquine together with low-dose glucocorticoids. In severe cases, cyclophosphamide or MMF can be initiated. The treatment of renal involvement differs between a lupus- and a scleroderma-associated renal failure (cyclophosphamide vs vasoactive treatment with ace inhibitors and iloprost).

For further details see Section III (*Systemic sclerosis*) and EULAR/ACR guidelines on rheumatoid arthritis.⁴⁰

Mixed connective tissue disease

Patients with MCTD usually respond well to systemic glucocorticoid and immunosuppressive therapy with several classical agents. But some long-term studies have shown that a group of patients with MCTD develop more severe organ manifestations and need a more aggressive therapeutic strategy. Inflammatory features (elevated temperature, serositis, pleuritis, myositis, and arthritis) respond well to glucocorticoid treatment, while symptoms, such as sclerotic skin changes and cardiopulmonary involvement need immunosuppressive/cytotoxic drugs.^{29,41} The most frequently used drugs are hydroxychloroquine, methotrexate, and cyclophosphamide.²⁹

Systemic sclerosis and Sjögren's overlap syndrome

Clinical features such as the xerostomia can usually be improved by using various antiseptic mouth rinse and saliva substitutes. Xerophthalmia can be improved by using artificial tear drops.⁴² This topical treatment should be combined with hydroxychloroquine and low-dose glucocorticoids. In severe cases, cyclophosphamide, azathioprine, or rituximab have shown to be effective in open-label studies.⁴³

For further details see Section III (*Systemic sclerosis*) and guidelines for Sjögren's syndrome.⁴⁴

<Fig. 2>

Table 1 Frequencies of different systemic sclerosis overlap syndromes (with references)²

SSc overlap syndrome	Frequency of syndrome*	Total
SSc	118 ¹² , 719 ¹³ , 1483 ¹⁴ , 165 ¹ , 1700 ⁴ , 2425 ¹⁵	6610 ²
SSc overlap syndromes	32.2% ¹² , 38% ¹³ , 10.9% ¹⁴ , 24.2% ¹ , 20% ⁴ , 9.2% ¹⁵	16.2% ²
SSc–polymyositis or SSc–dermatomyositis	5.3% ¹² , 47.5% ¹ , 42.8% ⁴ , 60.1% ¹⁵	44.6% ²
SSc–Sjögren’s syndrome	26.3% ¹² , 18% ¹³ , 42.5% ¹ , 16.8% ⁴	18.5% ²
SSc–rheumatoid arthritis	8% ¹² , 21.1% ¹³ , 15.4% ¹ , 32% ⁴ , 6.2% ¹⁵	19.3% ²

SSc, systemic sclerosis

*Frequencies of syndromes are shown as a percentage of patients with SSc.

Table 2 Autoantibodies associated with systemic sclerosis overlap syndromes

SSc overlap syndrome	Autoantibodies
MCTD	Anti-U1snRNP (specific), found in 75-90% of MCTD patients ^{20,21}
SSc–myositis	Anti-PM/Scl (specific) ¹⁵ Anti-Ku, -U1RNP, -Scl70, -Jo1, -Ro/SSA, -U3RNP, -RNA-polymerase have also been reported ² Anti-RuvBL1/2 antibody is a new SSc-related autoantibody, associated with muscle involvement and diffuse skin thickening ²²
SSc–rheumatoid arthritis	High titers of RF (60–72%), ACPA (prevalence of 64%) ² ACPA more frequent in patients with rheumatoid arthritis features in SSc patients ⁴ Anti-Scl-70 and anti-ACA antibodies have been reported ⁴
SSc–Sjogren’s	Anti-Ro/SSA and La/SSB have been reported ^{2,4} Clearly more often associated with ACA ^{2,4}
SSc–SLE	Anti-dsDNA together with anti-Scl70 antibodies have been reported ² Also, single cases with anti-ACA and -PM/Scl have been reported ²

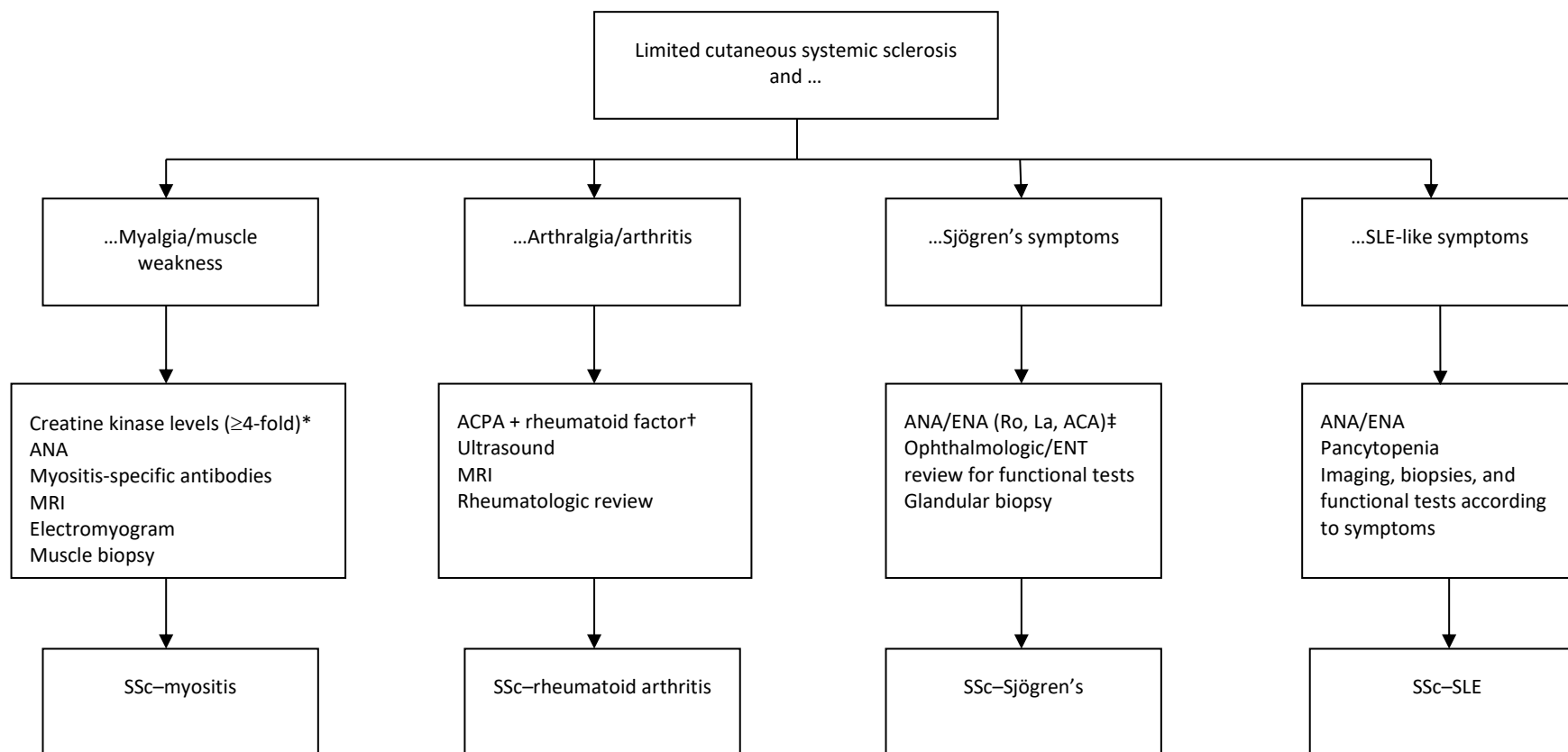
MCTD, mixed connective tissue disease; SSc, systemic sclerosis; SLE, systemic lupus erythematosus; ACPA, anti-citrullinated peptide antibodies; ACA, anti-centromere antibodies;

Table 3 Rare cases of systemic sclerosis overlap syndromes¹

SSc overlap syndrome with	Definition
Antiphospholipid syndrome	Incidence varies between 7% and 13% ¹ Presence of lupus anticoagulant, anti-cardiolipid or anti-β2-glycoprotein-1 antibodies has been reported in SSc patients, ¹ and has been associated with severe ischemia, PAH, digital loss, thromboembolism
Sarcoidosis	Very rare variant of SSc overlap syndrome Elevated temperature, weight loss and hilar adenopathy has been shown in SSc sarcoidosis overlap syndromes Lung and lymph node biopsy are necessary to diagnose the disease ¹
Primary biliary cirrhosis	Prevalence ranges between 7% and 15% Mostly associated with lcSSc Positive ACA reveals a higher risk for lcSSc Often clinically silent, but anti-mitochondrial antibodies, elevation of cholestatic enzymes, as well as hyperglobulinemia are possible ¹

SSc, systemic sclerosis; PAH, pulmonary arterial hypertension; ACA, anti-centromere antibodies; lcSSc, limited cutaneous systemic sclerosis.

Figure 1 Flow chart for diagnostic procedures in patients with different systemic sclerosis overlap syndromes.



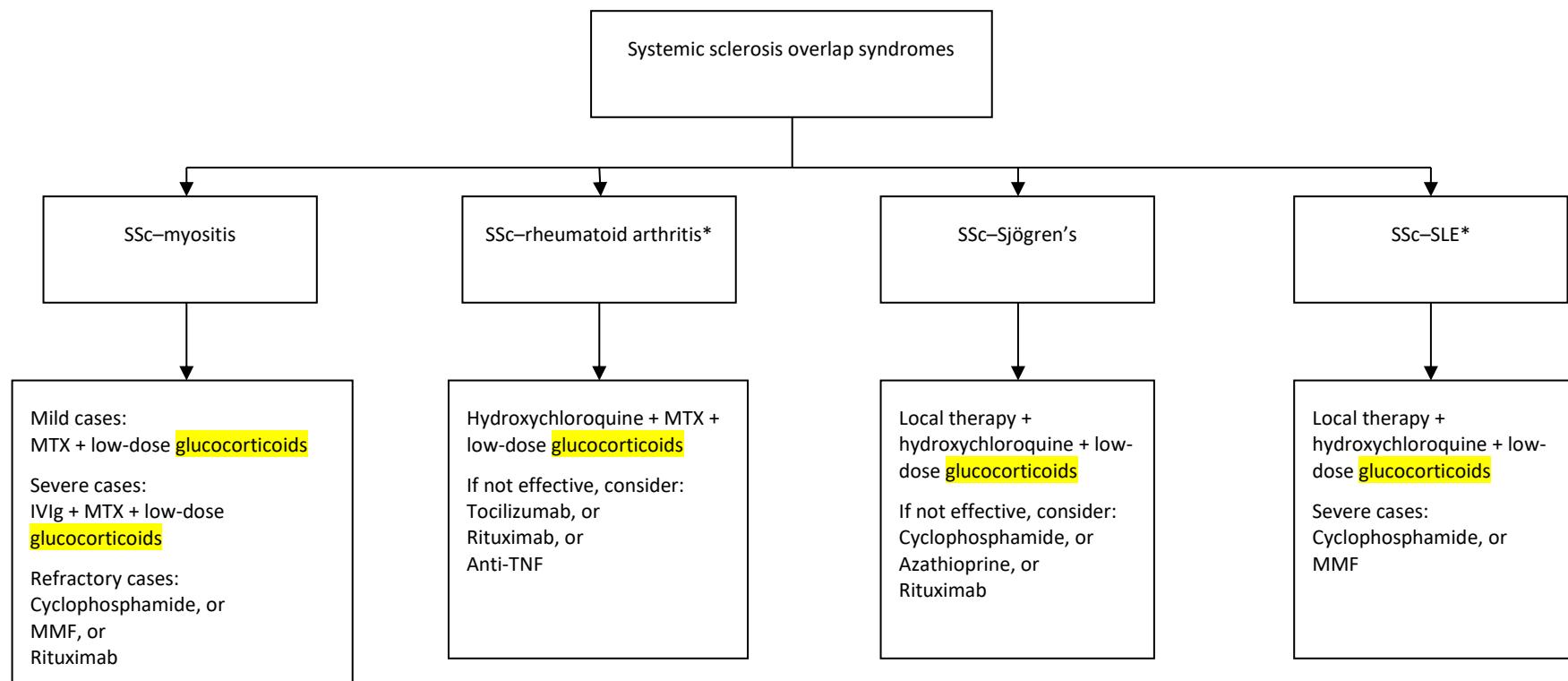
SLE, systemic lupus erythematosus; ANA, antinuclear antibodies; MRI, magnetic resonance imaging; ACPA, anti-citrullinated peptide antibodies; ENA, extractable nuclear antigen; ENT, ear, nose, throat.

*Exclude other reason for creatine kinase elevation (drugs, toxins, thyroid dysfunction).

†Some patients may be rheumatoid factor-negative and/or anti-CCP-negative.

‡Rule out hepatitis C virus positivity, vasculitis, internal organ manifestation.

Figure 2 Flow chart for therapeutic options for different systemic sclerosis overlap syndromes.



SSc, systemic sclerosis; SLE, Systemic lupus erythematosus; MTX, methotrexate; IVIg, intravenous immunoglobulin; MMF, mycophenolate mofetil; TNF, tumor necrosis factor.

*For detailed information, see the ACR/EULAR guidelines.

References

1. Balbir-Gurman A, Braun-Moscovici Y. Scleroderma overlap syndrome. *Isr Med Assoc J* 2011; **13**: 14–20.
2. Iaccarino L, Gatto M, Bettio S, *et al.* Overlap connective tissue disease syndromes. *Autoimmun Rev*. 2013; **12**: 363–373.
3. Jury EC, D'Cruz D, Morrow WJ. Autoantibodies and overlap syndromes in autoimmune rheumatic disease. *J Clin Pathol* 2001; **54**: 340–347.
4. Pakozdi A, Nihtyanova S, Moinzadeh P, Ong VH, Black CM, Denton CP. Clinical and serological hallmarks of systemic sclerosis overlap syndromes. *J Rheumatol* 2011; **38**: 2406–2409.
5. Moinzadeh P, Aberer E, Ahmadi-Simab K, *et al.* Disease progression in systemic sclerosis-overlap syndrome is significantly different from limited and diffuse cutaneous systemic sclerosis. *Ann Rheum Dis* 2015; **74**: 730–737.
6. Bohan A, Peter JB. Polymyositis and dermatomyositis (second of two parts). *New Engl J Med* 1975; **292**: 403–407.
7. Bohan A, Peter JB. Polymyositis and dermatomyositis (first of two parts). *New Engl J Med* 1975; **292**: 344–347.
8. Kay J, Upchurch KS. ACR/EULAR 2010 rheumatoid arthritis classification criteria. *Rheumatology* 2012; **51**(Suppl 6): vi5–9.
9. Shiboski SC, Shiboski CH, Criswell L, *et al.* American College of Rheumatology classification criteria for Sjogren's syndrome: a data-driven, expert consensus approach in the Sjogren's International Collaborative Clinical Alliance cohort. *Arthritis Care Res* 2012; **64**: 475–487.
10. Tan EM, Cohen AS, Fries JF, *et al.* The 1982 revised criteria for the classification of systemic lupus erythematosus. *Arthritis Rheum* 1982; **25**: 1271–1277.
11. Elhai M, Avouac J, Kahan A, Allanore Y. Systemic sclerosis at the crossroad of polyautoimmunity. *Autoimmun Rev* 2013; **12**: 1052–1057.
12. Caramaschi P, Biasi D, Volpe A, Carletto A, Cecchetto M, Bambara LM. Coexistence of systemic sclerosis with other autoimmune diseases. *Rheumatol Int* 2007; **27**: 407–410.
13. Hudson M, Rojas-Villarraga A, Coral-Alvarado P, *et al.* Polyautoimmunity and familial autoimmunity in systemic sclerosis. *J Autoimmun* 2008; **31**: 156–159.
14. Hunzelmann N, Genth E, Krieg T, *et al.* The registry of the German Network for Systemic Scleroderma: frequency of disease subsets and patterns of organ involvement. *Rheumatology* 2008; **47**: 1185–1192.

15. Koschik RW 2nd, Fertig N, Lucas MR, Domsic RT, Medsger TA Jr. Anti-PM-Scl antibody in patients with systemic sclerosis. *Clin Exp Rheumatol* 2012; **30**(2 Suppl 71): S12–16.
16. Koumakis E, Dieude P, Avouac J, Kahan A, Allanore Y. Familial autoimmunity in systemic sclerosis – results of a French-based case-control family study. *J Rheumatol* 2012; **39**: 532–538.
17. Valenzuela A, Chung L. Calcinosis: pathophysiology and management. *Curr Opin Rheumatol* 2015; **27**: 542–548.
18. Bhansing KJ, Lammens M, Knaapen HK, van Riel PL, van Engelen BG, Vonk MC. Scleroderma-polymyositis overlap syndrome versus idiopathic polymyositis and systemic sclerosis: a descriptive study on clinical features and myopathology. *Arthritis Res Ther* 2014; **16**: R111.
19. Mahler M, Raijmakers R. Novel aspects of autoantibodies to the PM/Scl complex: clinical, genetic and diagnostic insights. *Autoimmun Rev* 2007; **6**: 432–437.
20. Tani C, Carli L, Vagnani S, *et al.* The diagnosis and classification of mixed connective tissue disease. *J Autoimmun* 2014; **48–49**: 46–49.
21. Habets WJ, de Rooij DJ, Salden MH, Verhagen AP, van Eekelen CA, van de Putte LB, *et al.* Antibodies against distinct nuclear matrix proteins are characteristic for mixed connective tissue disease. *Clinical and experimental immunology*. 1983;54(1):265-76. Epub 1983/10/01.
22. Kaji K, Fertig N, Medsger TA Jr, *et al.* Autoantibodies to RuvBL1 and RuvBL2: a novel systemic sclerosis-related antibody associated with diffuse cutaneous and skeletal muscle involvement. *Arthritis Care Res* 2014; **66**: 575–584.
23. Rigolet A, Musset L, Dubourg O, *et al.* Inflammatory myopathies with anti-Ku antibodies: a prognosis dependent on associated lung disease. *Medicine* 2012; **91**: 95–102.
24. Lin HK, Wang JD, Fu LS. Juvenile diffuse systemic sclerosis/systemic lupus erythematosus overlap syndrome – a case report. *Rheumatol Int* 2012; **32**: 1809–1811.
25. Bloch KJ, Buchanan WW, Wohl MJ, Bunim JJ. Sjogren's Syndrome. A clinical, pathological, and serological study of sixty-two cases. *Medicine* 1965; **44**: 187–231.
26. Ramos-Casals M, Brito-Zeron P, Font J. The overlap of Sjogren's syndrome with other systemic autoimmune diseases. *Semin Arthritis Rheum* 2007; **36**: 246–255.
27. Avouac J, Sordet C, Depinay C, *et al.* Systemic sclerosis-associated Sjogren's syndrome and relationship to the limited cutaneous subtype: results of a prospective study of sicca syndrome in 133 consecutive patients. *Arthritis Rheum* 2006; **54**: 2243–2249.

28. Sharp GC, Irvin WS, Tan EM, Gould RG, Holman HR. Mixed connective tissue disease – an apparently distinct rheumatic disease syndrome associated with a specific antibody to an extractable nuclear antigen (ENA). *Am J Med* 1972; **52**: 148–159.
29. Ortega-Hernandez OD, Shoenfeld Y. Mixed connective tissue disease: an overview of clinical manifestations, diagnosis and treatment. *Best Pract Res Clin Rheumatol* 2012; **26**: 61–72.
30. Akesson A, Fiori G, Krieg T, van den Hoogen FH, Seibold JR. Assessment of skin, joint, tendon and muscle involvement. *Clin Exp Rheumatol* 2003; **21**(3 Suppl 29): S5–8.
31. Santiago ML, Seisdedos MR, Garcia Salinas RN, Catalan Pellet A, Villalon L, Secco A. Usefulness of antibodies and minor salivary gland biopsy in the study of sicca syndrome in daily clinical practice. *Reumatol Clin* 2015; **11**: 156–160.
32. Steen VD, Mayes MD, Merkel PA. Assessment of kidney involvement. *Clin Exp Rheumatol* 2003; **21**(3 Suppl 29): S29–31.
33. Kistler AD. Lupusnephritis. *Ther Umsch* 2015; **72**: 171–177.
34. Kowal-Bielecka O, Distler O. Use of methotrexate in patients with scleroderma and mixed connective tissue disease. *Clin Exp Rheumatol* 2010; **28**(5 Suppl 61): S160–163.
35. Fendler C, Braun J. Use of methotrexate in inflammatory myopathies. *Clin Exp Rheumatol* 2010; **28**(5 Suppl 61): S164–167.
36. Walker KM, Pope J. Expert agreement on EULAR/EUSTAR recommendations for the management of systemic sclerosis. *J Rheumatol* 2011; **38**(7): 1326–1328.
37. Levy Y, Amital H, Langevitz P, *et al.* Intravenous immunoglobulin modulates cutaneous involvement and reduces skin fibrosis in systemic sclerosis: an open-label study. *Arthritis Rheum* 2004; **50**: 1005–1007.
38. Levine TD. Rituximab in the treatment of dermatomyositis: an open-label pilot study. *Arthritis Rheum* 2005; **52**: 601–607.
39. Mok CC, Ho LY, To CH. Rituximab for refractory polymyositis: an open-label prospective study. *J Rheumatol* 2007; **34**: 1864–1868.
40. van den Hoogen F, Khanna D, Fransen J, Johnson SR, Baron M, Tyndall A, *et al.* 2013 classification criteria for systemic sclerosis: an American College of Rheumatology/ European League against Rheumatism collaborative initiative. *Ann Rheum Dis* 2013; **72**: 1747–1755.
41. Lundberg IE. The prognosis of mixed connective tissue disease. *Rheum Dis Clin North Am* 2005; **31**: 535–547, vii-viii.

42. Feltsan T, Stanko P, Mracna J. Sjogren's syndrome in present. *Bratisl Lek Listy* 2012; **113**: 514–516.
43. Carubbi F, Cipriani P, Marrelli A, *et al.* Efficacy and safety of rituximab treatment in early primary Sjogren's syndrome: a prospective, multicenter, follow-up study. *Arthritis Res Ther* 2013; **15**: R172.
44. Vitali C, Bootsma H, Bowman SJ, *et al.* Classification criteria for Sjogren's syndrome: we actually need to definitively resolve the long debate on the issue. *Ann Rheum Dis* 2013; **72**: 476–478.

VI Scleredema

Introduction

Scleredema (scleredema adultorum, scleredema of Buschke) is a rare scleromucinous connective tissue disease of unknown etiology. The disease is characterized by firm edema of the trunk, head, shoulders, and sometimes the thighs, but with hands and feet spared.¹ The disease was first described back in 1752 by Curzio.² However, in 1902 Abraham Buschke named it “scler-oedem,” when he presented the case of a patient developing skin thickening after influenza.³ Buschke also added “adultorum” to the name, suggesting the adult age of affected patients. To date, the majority of patients described in the literature have been younger than 20 years.¹ Therefore, currently, scleredema adultorum is most commonly called “scleredema” or “scleredema of Buschke.”

Three types of scleredema can be distinguished.⁴ They are associated with different preceding or underlying conditions. Type 1 usually follows a febrile episode/infection. Type 2 is associated with paraproteinemias (including multiple myeloma). Type 3 was named scleredema diabeticorum by Krakowski,⁵ because of its strict association with diabetes mellitus (type 1 and 2). The pathologic effect of skin hardening in different clinical types of scleredema is the result of excessive production of mucin (high molecular weight, heavily glycosylated proteins) and collagens by fibroblasts in the reticular dermis.¹

Epidemiology

Scleredema is a very rare condition. Its exact prevalence and incidence are unknown. Thus, many cases may be unreported. To our knowledge, there is no racial or ethnic predilection to the disease. Scleredema occurs in individuals of all ages, ranging from infancy to adulthood.

Type 1 scleredema, which constitutes 55% of the total number of cases, affects mainly children.⁶ Type 2 scleredema occurs in 25% of cases, whereas type 3 scleredema is observed in about 20% of scleredema cases.² We do not know the proportion of type 1 and 2 diabetes or multiple myeloma patients who develop scleredema. More than 50% of patients are aged under 20 years,⁷ and they mostly suffer from types 1 or 2 scleredema. In types 1 and 2 scleredema, women are affected almost twice as frequently as men. The male to female ratio in type 3 scleredema is considered to be 10:1.^{2,6,8}

Pathogenesis

The pathogenesis of scleredema remains unknown. Scleredema is a heterogeneous syndrome with different concomitant conditions and mechanisms. The excessive production of mucin and collagen may be provoked by diverse stimuli, including infections and inflammatory processes, drugs, toxins, genetic mutations, immunoglobulins and cytokines, and genetic factors.^{9,10} The pathogenesis of the diabetic type of scleredema is considered to be associated with ischemia, hyperinsulinism, or autoimmunity.¹¹ Chronic hyperglycemia is believed to stimulate fibroblast proliferation and extracellular matrix components synthesis. It was documented that scleredema is also associated with an abnormal expression of extracellular protein genes (type 1 and type 3 collagens, fibronectin) in the lesions.¹² However, non-enzymatic glycosylation progressively damages collagen in the connective tissue by altering the mechanism of collagen fiber degradation. The lack of lymphocytic infiltrates in the lesions excludes a T-cell-mediated etiology.

Clinical manifestations

The clinical symptoms of scleredema include cutaneous and extracutaneous findings, which are present especially in types 2 and 3 scleredema.

Cutaneous manifestations

In the early stages, scleredema manifests as a woody hardening of the skin of the neck, which later spreads to shoulders and the upper part of the trunk. It may affect the face and occasionally the thighs, but it rarely affects the hands and feet.^{11,13,14} The lesions are ill-defined, non-pitting, indurated plaques. The affected skin wrinkles or takes on a “peau d’orange” appearance when pinched. This induration may occasionally follow a transient erythematous eruption.^{10,15,16} In addition, a diffuse pigmentation of the skin was reported in a patient with type 2 scleredema, as melanogenesis seems to be connected with paraproteinemia.¹⁷ The skin appendages are usually preserved. However, the loss of eccrine glands, causing frequent heat attacks, was observed in one patient.¹⁸ Cellulitis and delayed wound healing have also been reported.^{11,19}

Extracutaneous manifestations

Although scleredema classically manifests as skin thickening, the extracutaneous involvement of different internal organs is possible, leading to many potentially life-threatening complications. Systemic manifestations occur more commonly in types 2 and 3; they are rare in type 1 scleredema.²⁰ Limitations in the movement of extremities, difficulties in opening the

mouth and eyes, and difficulties in breathing or even restrictive lung disease are the most common symptoms. Lesions in various locations may lead to different complications.

Lesions in the eye and periorbital region lead to blepharoptosis, exophthalmos, chemosis, conjunctivitis, corneal ulcer, keratitis, restricted eye movement, and ophthalmoplegia.^{8,10} Involvement of the tongue, the upper part of the esophagus, ocular muscles, pharynx, parotid glands, and vocal cords in the larynx is less common. Involvement of the esophagus can cause dysphagia.²⁰⁻²² These complications are known to have caused aspiration of food and aspiration pneumonia.²³

Cardiac involvement may result in congestive heart failure, myocarditis, diastolic gallop, arrhythmia, and repolarization abnormalities. Hepatomegaly and splenomegaly may be found in some patients with scleredema.² Scleredema may be associated with pleura and lung involvement, leading to pulmonary restrictive disease, which can also be the consequence of the involvement of the skin and subcutaneous structures of the trunk, or even death.^{24,25} In some patients, these abnormalities may be secondary to skin induration of the trunk.

A very strong relationship between diabetic scleredema and obstructive sleep apnea syndrome has been documented.²⁵

Musculoskeletal involvement is associated with dismotility and limitation of motion.² Some authors have reported bone marrow infiltration with calvarial sclerosis or with osteopoikilosis, as well as the infiltration of nerve tissue.^{2,10}

Associated disorders

Scleredema is a heterogeneous disorder that may be associated with various conditions. Type 1 scleredema usually follows an infection, especially streptococcal respiratory tract infection. However, other infective agents that have been reported are: influenza, measles, mumps, chicken-pox, cytomegalovirus, diphtheria, encephalitis, mycoplasma pneumonia, and dental abscesses.^{4,6,10,16,26,27}

Type 2 scleredema is often associated with paraproteinemia, which is present in 25% of scleredema patients, compared with 0.5% prevalence of paraproteins expected in the general population.²⁸ Associated conditions include monoclonal gammopathy,^{6,29-31} multiple

myeloma,^{32–36} and amyloidosis.²⁸ Multiple myeloma is commonly not present at the time of scleredema onset. Some patients with scleredema develop multiple myeloma after a few years of asymptomatic monoclonal gammopathy. Other associated diseases include primary hyperparathyroidism,^{37,38} rheumatoid arthritis,^{39,40} ankylosing spondylitis,²⁹ Sjögren's syndrome,⁴⁰ dermatomyositis,⁴¹ Waldenström's macroglobulinemia, anaphylactoid purpura, primary biliary cirrhosis,⁴² IgA deficiency,⁴³ and HIV infection.^{8,10} Cases of concomitant neoplasms have been reported, such as malignant insulinoma,⁴⁴ gall bladder carcinoma,⁴⁵ carcinoid tumor,⁴⁶ and adrenocorticotrophic hormone-producing pituitary tumor.⁴⁷

Diabetic scleredema (type 3) is associated with type 1 and type 2 diabetes mellitus. However, it is associated with insulin resistance and hyperglycemia, and therefore other endocrinopathies with insulin resistance (not only diabetes) could be present. In addition, in cases of adrenocortical tumors or pituitary adenomas, which are functional, scleredema symptoms refer to the metabolic status of hypercortisolism and diabetes/diabetic tendencies.⁴⁷

Clinical course

The clinical course of scleredema depends on the type. Type 1 scleredema, which is the classic "Buschke" scleredema type, is preceded by a febrile illness (fever over 38°C during 3–4 weeks). The onset of scleredema type 1 is abrupt but the prognosis is good and in most cases it resolves in a few months to 2 years.⁶ There have been reports of rare cases of persistent scleredema type 1 persisting for 10 years. Systemic involvement is uncommon.

Type 2 scleredema is associated with paraproteinemias with no infection in the patient's history. This type is slowly progressive with a non-resolving course.^{4,6} Systemic involvement is likely to occur with serious complications.

Type 3 scleredema (diabetic scleredema) is associated with type 1 or 2 diabetes mellitus. The risk factors for scleredema type 3 are: male sex, long course of diabetes, poor metabolic control, treatment with insulin, and presence of diabetes-specific complications (especially microangiopathy). Other risk factors of diabetic scleredema are hypertension and obesity.^{11,25,48,49} The course of disease is insidious, slowly progressing and non-resolving as in type 2, but occasionally it is self-limited. Some cases are complicated by systemic involvement.

Diagnostic procedures

Histopathology

The following histopathologic findings are characteristic for scleredema.

- The epidermis is usually not involved.
- The most characteristic finding is increased thickness of the dermis (up to four times thicker than normal). It is due to enlarged collagen bundles in deep reticular dermis and the presence of wide, clear spaces between them. These fenestrations are filled with mucin. Mucin deposits represent non-sulfated acid mucopolysaccharides, mainly hyaluronic acid.
- The subcutaneous tissue is also affected – fat is replaced by coarse collagen fibers.¹⁰
- Accumulation of mucopolysaccharides is easily found when stained with Alcian blue dye, colloidal iron or toluidine blue. However, the absence of glycosaminoglycan deposits is possible, and therefore this does not exclude the diagnosis.^{10,50,51}
- Appendages are usually preserved, unlike in scleroderma. However, some authors have reported the loss of eccrine glands.^{49,50}

The diagnosis of scleredema is made clinically, with the definitive diagnosis confirmed by histopathology.^{49,52,53}

Diagnostic criteria

The diagnosis of scleredema is based upon the recognition of the following criteria:

- typical woody thickening of the skin, which spares acral locations (hands and feet are usually not involved);
- increased thickness of the dermis in the microscopic evaluation with the accumulation of mucopolysaccharides;
- history of a preceding infection, underlying diabetes or paraproteinemia.

In type 2 scleredema no associated diseases (paraproteinemia) may be present at the time of diagnosis of scleredema. It is suggested to distinguish type 2a and 2b scleredema. Type 2a fulfills all criteria of type 2 scleredema, but with no associated lymphoproliferative disorder. Type 2b is scleredema associated with a lymphoproliferative disorder.

Patient history

The patient is asked about preceding infections. Moreover, the symptoms of malignancies or of diabetes/glucose intolerance associated with other endocrinopathies should be carefully considered. Identification of possible systemic complications requires questions about

difficulties in movement, fatigue (muscle or heart involvement), dysphagia (mainly involvement of the upper part of the esophagus), respiratory problems, and neurologic symptoms (e.g. paresthesia, pain).

Physical examination

A full skin examination is performed. The induration of the skin in characteristic locations (neck, the upper part of the trunk, shoulders, face) and spared hands and feet suggest the diagnosis of scleredema. A modified Rodnan scale (as in scleroderma or scleromyxedema) may be used to evaluate the severity of skin involvement and to document its activity. In addition, a durometer or an ultrasonography measurement of skin thickness may be performed in order to evaluate the severity and to monitor the disease.⁵⁴

Skin biopsy

A skin biopsy is required to confirm the diagnosis and to exclude other sclerosis-like disorders. A 4 or 5 mm punch biopsy is sufficient. A mucin stain will be positive. Direct immunofluorescence is negative and has little, if any, value for differential diagnosis.

Complementary investigations

At the time of diagnosis, blood tests mainly aim at identifying a lymphoproliferative disorder in patients without a recent history of infection and without a history of diabetes. However, as the disease is very rare, it is recommended that these tests are performed in all patients. Leukocyte count (lymphocytes), serum protein electrophoresis, and serum and urine immunofixation must be performed in order to screen for monoclonal gammopathy.⁴⁹ In cases of monoclonal gammopathy, or clinical evidence of enlarged lymph nodes, additional investigations should be discussed, including cytofluorometry analysis (looking for B cell lymphoproliferation), chest and abdomino-pelvic computed tomography scan ± positron emission tomography scan ± lumbar and dorsal magnetic resonance imaging ± myelogram/osteomedullar biopsy (Table 1).

<TABLE 1>

During follow-up, in patients with diabetes, fasting glycemia and HBA1c must be monitored. In patients with type 2, with or without identified lymphoproliferation, leukocyte count (lymphocytes), serum protein electrophoresis, and serum and urine immunofixation must be

performed every year, in association with a complete physical examination looking for lymph node enlargement and/or hepato-splenomegaly (Table 2).

<TABLE 2>

Other laboratory test may be needed in differential diagnosis to exclude other conditions, depending on the clinical presentation. Antinuclear antibodies (ANA), if performed, are negative. This test may facilitate differential diagnosis with systemic sclerosis (SSc).

Additional tests

High-frequency ultrasonography may be performed to monitor the activity and severity of skin involvement. In cases of systemic involvement, specific diagnostic examinations are required (e.g. pulmonary function tests, ultrasonography of internal organs, including the heart, liver or spleen, esophageal manometry, radiography/ultrasonography of bones/joints).

Differential diagnosis

Scleredema may cause diagnostic difficulties, as the differential diagnosis includes various diseases. The characteristic thickness of the dermis and the accumulation of mucopolysaccharides distinguish scleredema from other sclerotic disorders.¹⁰ Two main disorders that require a differential diagnosis are: scleroderma (SSc) and scleromyxedema.

SSc (scleroderma)

Clinical and histopathologic differences allow for the differentiation. Skin thickening in SSc typically begins with involvement of the finger tips, progressing to involve the hands and feet, which are spared in scleredema. Other typical clinical findings of SSc, such as Raynaud's phenomenon, abnormal nailfold capillaries, and ANA, are absent in scleredema. Histopathology distinguishes the two diseases, and there are no deposits of mucin in SSc.

Scleromyxedema

Clinically and histopathologically, scleromyxedema is very close to scleredema. However, the induration of the skin progresses acraly and typically forms characteristic large folds or firm papules, which are absent in scleredema. Systemic complications are common in both diseases. The association with monoclonal gammopathy or multiple myeloma is present, similarly to scleredema type 2. Mucin deposits are likely to be present.

Scleromyositis

Scleromyositis differs from scleredema by its typical clinical symptoms and common presence of ANA, especially PM/Scl. The clinical presentation of edema, which is correlated with heart or renal failure, is different from scleredema. However, sometimes there may be some problems with differentiation. Edema is usually non-solid, “pitting.” Due to hydrostatic pressure, edema is likely to occur in acral locations. The patient has symptoms of heart/renal failure. Histopathologically, edema and scleredema are different. Similar clinical presentation and differences (as found in edema) may also occur in the course of lymphedema.

Myxedema

Myxedema is associated with thyroid dysfunction, and is ruled out serologically and clinically, by exclusion of thyroid function abnormalities.

Eosinophilic fasciitis

A typical woody induration in areas corresponding to the anatomic localization of the fascia. Typically these are the trunk and extremities, usually sparing the finger tips. Carpal tunnel syndrome may coexist. Eosinophilia, if present, may facilitate differential diagnosis. Histopathology distinguishes the two disorders; however, the biopsy should be sufficiently deep to reach the fascia. Mucin deposits are not present.

Cutaneous amyloidosis

The term “amyloidosis” is used for a group of disorders with accumulation of various insoluble proteins (amyloid). Amyloidosis can be ruled out/confirmed with a microscopic examination. Histopathologically, amyloidosis manifests as characteristic amyloid deposits found in the affected tissues when stained with Congo red dye.

Lymphedema

Lymphedema refers to edema, which is usually most strongly expressed acraly, affecting the extremities. The removal or damage to lymph nodes is common in the medical history of the patient. Lymphedema differs from scleredema histopathologically. The typical findings include keratinocyte hyperproliferation, condensed dermal collagen, and mononuclear perivascular infiltrate that increases with lymphedema stage. There is no accumulation of mucopolysaccharides.

Radiotherapy-induced skin thickening

Radiotherapy-induced skin thickening can be confirmed or excluded by history of preceding radiation treatment. Lesions are usually limited to the area exposed to radiotherapy. Mucin deposits are not present. Mylona *et al.* reported scleredema after a radiation treatment.⁵⁵

Graft-versus-host disease

Graft-versus-host disease can be confirmed or excluded by history of preceding treatment. Examination of skin biopsy for mucin deposits is negative.

Treatment

The treatment will focus on the underlying condition. Thus, when a potential cause is identified, the priority will be the treatment of the cause (Table 3).

In diabetic patients, the control of diabetes is mandatory. If not already prescribed, insulin may be necessary. In addition, diabetes should be controlled. Overweight patients should be given advise on how to lose weight.

If an infection is identified it may be treated with appropriate anti-infectious agents. However, scleredema type 1 does not usually require treatment, as it is self-limited and usually resolves in few of months to 2 years.

If a lymphoproliferative disorder is identified, there is a need for discussions with the hematologist in order to treat the lymphoproliferative disease itself. Thus, it was reported that scleredema may improve after the treatment of a multiple myeloma.³²

In the absence of an etiology, if the patient has severe involvement, a treatment can be proposed. Unfortunately, the number of patients reported in the literature to benefit from a specific treatment is very small, and on that basis it is very difficult to make evidence-based medical recommendations. However, based on the available literature, the expert recommendation is to use medium-to-high dose ultraviolet light therapy (UVA1 or PUVA) as a first-line treatment.⁵⁶⁻
⁶⁰ If the condition fails to improve, or if PUVA is not available, methotrexate is recommended as a second-line treatment. If methotrexate fails, based on a risk–benefit approach, the following treatments can be proposed:

- cyclosporine A^{61–63}
- glucocorticoids (systemic or intralesional)⁶⁴
- electron-beam radiotherapy^{6,65–67}
- extracorporeal photopheresis⁶⁸
- prostaglandin E1⁶⁹
- intravenous immunoglobulin⁷⁰
- high-dose penicillin⁷¹
- hyaluronidase intralesionally⁷²
- factor XIII infusion⁷³
- radiotherapy⁷⁴
- cyclophosphamide.³⁶

A significant number of case reports indicate that the most beneficial treatment method is photochemotherapy (UVA1, PUVA or narrow-band UVB). The mechanism of the improvement remains unclear.^{49,75} Lack of randomized controlled trials in scleredema creates a difficulty in drawing conclusions about the long-term efficacy, optimum dose, and best treatment regimens.⁷⁶

In addition to different systemic treatment modalities, non-pharmacologic treatments can be proposed, such as physiotherapy, in order to increase the range of motion of joints and/or improve restrictive respiratory insufficiency (Table 3).¹¹

<TABLE 3>

Prognosis and follow-up

During follow-up, the efficacy of treatments can be assessed using the modified Rodnan skin score, Health Assessment Questionnaire, range of motion of involved joints, and the Dermatology Life Quality Index (Table 4).

Type 1 scleredema associated with a preceding infection is characterized by a good prognosis and even spontaneous resolution. The active phase lasts 2–8 weeks and is followed by a resolution in a couple of months to 2 years.⁷⁷ Scleredema type 1 lesions persisting for 10 years are uncommon.⁷⁸

Unlike type 1, type 2, which is associated with blood dyscrasia, should be carefully followed up. The prognosis is not good; the lesions are persistent with possible systemic involvement leading to life-threatening complications. If only monoclonal gammopathy of unspecified significance is present, the risk of multiple myeloma or another related malignancy is about 1% per year. Therefore, careful follow-up of patients is required.¹⁷ The treatment of underlying diseases is crucial; however, this may not be satisfactory in some type 2 scleredema cases.

Diabetic scleredema has a poor prognosis, with a chronic progressive course and systemic complications. It also requires follow-up of patients. Monitoring blood glucose and metabolic control are beneficial in some cases. Sleep apnea syndrome is common, and specific diagnostic tests are necessary to confirm the disorder. As diabetic scleredema is under-recognized, there is a need for appropriate education.⁶⁴

<TABLE 4>

Summary and recommendation

- Scleredema adutorum is a connective tissue disorder characterized by the thickening of the skin. The characteristic location of woody indurated areas is the upper part of the body. In contrast to systemic sclerosis, it never affects the acral parts of extremities.
- There are three types of the disease. Type 1 usually follows a febrile episode/infection. Type 2 is associated with paraproteinemias. Type 3 is associated with diabetes.
- There is no racial or ethnic predilection. Male to female ratio is 1:2 in type 1 and 2 scleredema, but 10:1 in type 3 scleredema.
- The pathogenesis of scleredema is unknown. Various conditions and mechanisms are related to the excessive production of mucin and collagen, causing the thickening of the dermis.
- The clinical symptoms of scleredema include cutaneous and extracutaneous findings, especially in types 2 and 3 scleredema. Decreased mobility of the affected tissues commonly causes movement limitations or even respiratory insufficiency.
- The clinical course of scleredema depends on its type. Three clinical types of scleredema are associated with different stimuli which may evoke scleredema of Buschke.
- Skin biopsy identifies mucin deposits.
- Type 1 scleredema is preceded by a febrile illness. It is self-limited with a spontaneous resolution in a few months to 2 years.

- Type 2 scleredema, associated with paraproteinemias (2a with identified paraproteinemia at the time of diagnosis, type 2b with paraproteinemia identified during follow-up), is slowly progressive with systemic involvement and a poor response to treatment.
- Type 3 scleredema (diabetic scleredema) is associated with diabetes. The course of disease is insidious, slowly progressing, and non-resolving as in type 2, but it is sometimes self-limited. Systemic complications are likely to occur.
- The diagnosis of scleredema is made clinically. A histopathologic examination is performed to confirm a definitive diagnosis. It is made in cases of woody indurations of the skin with increased thickness of the reticular dermis and the accumulation of mucopolysaccharides found when stained with Alcian blue. Patient follow-up in types 2 and 3 scleredema is needed to screen for paraproteinemias and systemic complications or to monitor the metabolic status of the patient with diabetic scleredema.
- Scleredema type 1 does not usually require treatment, as it is self-limited and usually resolves in a short period of time. In types 2 and 3 scleredema, the treatment of an underlying condition is needed. Better glucose control has been proven to be beneficial in some cases. No specific therapy of scleredema is available, although numerous methods have been proposed with variable results. The recommended first-line treatment is UV-based management in monotherapy. If this fails, methotrexate is recommended.

Table 1 Scleredema: complementary examinations for etiologic diagnosis

- Leukocyte count (lymphocytes)
- Serum protein electrophoresis (peak, hypogammaglobulinemia)
- Immunofixation (serum, urine)
- CT scan ± PET scanner ± MRI*
- Myelogram/osteomedullar biopsy*

CT, computed tomography; PET, positron emission tomography; MRI, magnetic resonance imaging.

*In the presence of enlarged lymph node upon clinical examination or a peak upon protein electrophoresis or hypogammaglobulinemia

Table 2 Scleredema: complementary exams for follow-up

Type 1

- None

Type 2

If no evidence of an etiology, and no resolution, repeat tests annually to identify lymphoproliferative disorder, in addition to physical examination

- Leukocyte count (lymphocytes)
- Serum protein electrophoresis (peak, hypogammaglobulinemia)
- Immunofixation (serum, urine)

Type 3

- Fasting glycemia, HbA1C

Table 3 Scleredema: treatment

Treat the identified cause

- Equilibrate diabetes (type 3)
- Treat multiple myeloma or other identified lymphoproliferative disorder (type 2)

Non-pharmacologic measures

- Weight loss, rehabilitation (increase range of motion of involved joints, respiratory rehabilitation)

Specific treatment if severe and no identified cause

- First line: medium-to-high dose UVA1 or PUVA*
- Second line: methotrexate (if no UVA1 or PUVA)[†]
- Other proposed treatments[‡]

*See also section I (*Localized scleroderma*)

[†]With or without glucocorticoids, except in diabetic patients.

[‡]Cyclosporine A, glucocorticoids (systemic or intralesional), electron-beam radiotherapy, extracorporeal photopheresis, prostaglandin E1, intravenous immunoglobulin, high-dose penicillin, hyaluronidase intralesionally, factor XIII infusion, radiotherapy, cyclophosphamide.

Table 4 Scleredema: evaluation of treatment efficacy

- Range of motion of involved joints (physical measurements and photos)
- Modified Rodnan skin score
- Health Assessment Questionnaire
- Dermatology Life Quality Index

References

1. Rimón D, Lurie M, Storch S, *et al.* Cardiomyopathy and multiple myeloma. Complications of scleredema adutorum. *Arch Intern Med* 1988; **148**: 551–553.
2. Beers WH, Ince A, Moore TL. Scleredema adutorum of Buschke: a case report and review of the literature. *Semin Arthritis Rheum* 2006; **35**: 355–359.
3. A. B. Uber scleroderma. *Klin Wochenschr* 1902; **39**: 955–957.
4. R. G. Scleredema adutorum. *Arch Dermatol* 1968; **98**: 319–320.
5. Krakowski A, Covo J, Berlin C. Diabetic scleredema. *Dermatologica* 1973; **146**: 193–198.
6. Angeli-Besson C, Koeppel MC, Jacquet P, Andrac L, Sayag J. Electron-beam therapy in scleredema adutorum with associated monoclonal hypergammaglobulinaemia. *Br J Dermatol* 1994; **130**: 394–397.
7. Greenberg LM, Geppert C, Worthen HG, Good RA. Scleredema "adutorum" in children. Report of three cases with histochemical study and review of world literature. *Pediatrics* 1963; **32**: 1044–1054.
8. Schmults CA. Scleroderma. *Dermatol Online J* 2003; **9**: 11.
9. Schmidt KT, Gattuso P, Messmore H, Shrit MA, Massa M, Welykyj S. Scleredema and smoldering myeloma. *J Am Acad Dermatol* 1992; **26**(2 Pt 2): 319–321.
10. Morais P, Almeida M, Santos P, Azevedo F. Scleredema of Buschke following *Mycoplasma pneumoniae* respiratory infection. *Int J Dermatol* 2011; **50**: 454–457.
11. Meguerditchian C, Jacquet P, Beliard S, *et al.* Scleredema adutorum of Buschke: an under recognized skin complication of diabetes. *Diabetes Metab* 2006; **32**(5 Pt 1): 481–484.
12. Varga J, Gotta S, Li L, Sollberg S, Di Leonardo M. Scleredema adutorum: case report and demonstration of abnormal expression of extracellular matrix genes in skin fibroblasts in vivo and in vitro. *Br J Dermatol* 1995; **132**: 992–999.
13. Farrell AM, Branfoot AC, Moss J, Papadaki L, Woodrow DF, Bunker CB. Scleredema diabeticorum of Buschke confined to the thighs. *Br J Dermatol* 1996; **134**: 1113–1115.
14. Boin F, Hummers LK. Scleroderma-like fibrosing disorders. *Rheum Dis Clin North Am* 2008; **34**: 199–220; ix.
15. Venencie PY. [Buschke's scleredema]. *Ann Dermatol Venereol* 1987; **114**: 1291–1292.
16. Venencie PY, Powell FC, Su WP, Perry HO. Scleredema: a review of thirty-three cases. *J Am Acad Dermatol* 1984; **11**: 128–134.
17. Minato H, Nishikori M, Tanioka M, Miyachi Y, Utani A. Scleredema with diffuse pigmentation. *J Eur Acad Dermatol Venereol* 2010; **24**: 100–101.

18. Lin IC, Chiu HY, Chan JY, Lin SJ. Extensive scleredema adutorum with loss of eccrine glands. *J Am Acad Dermatol* 2014; **71**: e99–e101.
19. Rees R, Moore A, Nanney L, King L. Scleredema adutorum: the surgical implications of a rare dermatologic disorder. *Plast Reconstr Surg* 1983; **72**: 90–93.
20. Mohanasundaram K, Kumarasamy S, Kumar R, Rajendran CP. Scleredema adutorum of Buschke: with unusual manifestations in a young female. *Indian J Dermatol Venereol Leprol* 2012; **78**: 503–505.
21. Ioannidou DI, Krasagakis K, Stefanidou MP, Karampekios S, Panayiotidis J, Tosca AD. Scleredema adutorum of Buschke presenting as periorbital edema: a diagnostic challenge. *J Am Acad Dermatol* 2005; **52**(2 Suppl 1): 41–44.
22. Brenner M, Herzinger T, Berking C, Plewig G, Degitz K. Phototherapy and photochemotherapy of sclerosing skin diseases. *Photodermatol Photoimmunol Photomed* 2005; **21**: 157–165.
23. Wright RA, Bernie H. Scleredema adutorum of Buschke with upper esophageal involvement. *Am J Gastroenterol* 1982; **77**: 9–11.
24. Sansom JE, Sheehan AL, Kennedy CT, Delaney TJ. A fatal case of scleredema of Buschke. *Br J Dermatol* 1994; **130**: 669–670.
25. Ray V, Boisseau-Garsaud AM, Ray P, *et al.* [Obesity persistent scleredema: study of 49 cases]. *Ann Dermatol Venereol* 2002; **129**: 281–285.
26. Venencie PY, Powell FC, Su WP. Scleredema and monoclonal gammopathy: report of two cases. *Acta Derm Venereol* 1984; **64**: 554–556.
27. Schmults C, Sidhu G, Urbanek RW. Aquagenic syringeal acrokeratoderma. *Dermatol Online J* 2003; **9**: 27.
28. Dziadzio M, Anastassiades CP, Hawkins PN, *et al.* From scleredema to AL amyloidosis: disease progression or coincidence? Review of the literature. *Clin Rheumatol* 2006; **25**: 3–15.
29. Chang HK, Kim YC, Kwon BS. Widespread scleredema accompanied with a monoclonal gammopathy in a patient with advanced ankylosing spondylitis. *J Korean Med Sci* 2004; **19**: 481–483.
30. Paz RA, Badra RE, Marti HM, Maxit MJ. [Systemic Buschke's scleredema with cardiomyopathy, monoclonal IgG kappa gammopathy and amyloidosis. Case report with autopsy]. *Medicina (B Aires)* 1998; **58**(5 Pt 1): 501–503.

31. McFadden N, Ree K, Soyland E, Larsen TE. Scleredema adultorum associated with a monoclonal gammopathy and generalized hyperpigmentation. *Arch Dermatol* 1987; **123**: 629–632.
32. Szturz P, Adam Z, Vasku V, *et al.* Complete remission of multiple myeloma associated scleredema after bortezomib-based treatment. *Leuk Lymphoma* 2013; **54**: 1324–1326.
33. Santos-Juanes J, Osuna CG, Iglesias JR, De Quiros JF, del Rio JS. Treatment with chemotherapy of scleredema associated with Ig A myeloma. *Int J Dermatol* 2001; **40**: 720–721.
34. Grudeva-Popova J, Dobrev H. Biomechanical measurement of skin distensibility in scleredema of Buschke associated with multiple myeloma. *Clin Exp Dermatol* 2000; **25**: 247–249.
35. Valente L, Velho GC, Farinha F, Bernardo A, Ribeiro P, Massa A. [Scleredema, acanthosis nigricans and IgA/Kappa multiple myeloma]. *Ann Dermatol Venereol* 1997; **124**: 537–539.
36. Salisbury JA, Shallcross H, Leigh IM. Scleredema of Buschke associated with multiple myeloma. *Clin Exp Dermatol* 1988; **13**: 269–270.
37. Jacob N, Gleichmann U, Stadler R. [Scleredema adultorum in secondary hyperparathyroidism]. *Hautarzt* 2002; **53**: 121–125.
38. Berk MA, Lorincz AL. Scleredema adultorum of Buschke and primary hyperparathyroidism. *Int J Dermatol* 1988; **27**: 647–649.
39. Ranganathan P. Infliximab-induced scleredema in a patient with rheumatoid arthritis. *J Clin Rheumatol* 2005; **11**: 319–322.
40. Miyagawa S, Dohi K, Tsuruta S, Shirai T. Scleredema of Buschke associated with rheumatoid arthritis and Sjogren's syndrome. *Br J Dermatol* 1989; **121**: 517–520.
41. Marill FG, Grould P. [Scleredema, 1st manifestation of a dermatomyositis]. *Bull Soc Fr Dermatol Syphiligr* 1968; **75**: 561–564.
42. Goss F, Krawietz W, Luderschmidt C, Pape GR. [Scleredema adultorum Buschke and primary biliary cirrhosis in a 58-year-old patient]. *Internist* 1984; **25**: 130–134.
43. Theodoridis A, Capetanakis J. Scleredema of Buschke with IgA deficiency. *Acta Derm Venereol* 1979; **59**: 182–183.
44. Matsunaga J, Hara M, Tagami H. Scleredema of Buschke associated with malignant insulinoma. *Br J Dermatol* 1992; **126**: 527–528.
45. Manchanda Y, Das S, Sharma VK, Srivastava DN. Scleredema associated with carcinoma of the gall bladder. *Br J Dermatol* 2005; **152**: 1373–1374.

46. Yu JI, Park W, Lee KK, Park W. Scleredema adultorum of Buschke associated with a carcinoid tumor. *Int J Dermatol* 2009; **48**: 784–786.
47. Oyama N, Togashi A, Kaneko F, Yamamoto T. Two cases of scleredema with pituitary-adrenocortical neoplasms: an underrecognized skin complication. *J Dermatol* 2012; **39**: 193–195.
48. Leung CS, Chong LY. Scleredema in Chinese patients: a local retrospective study and general review. *Hong Kong Med J* 1998; **4**: 31–35.
49. Martin C, Requena L, Manrique K, Manzarbeitia FD, Rovira A. Scleredema diabetorum in a patient with type 2 diabetes mellitus. *Case Rep Endocrinol* 2011; **2011**: 560273.
50. Rongioletti F, Rebora A. Cutaneous mucinoses: microscopic criteria for diagnosis. *Am J Dermatopathol* 2001; **23**: 257–267.
51. Vereecken P, Lutz R, De Dobbeleer G, Heenen M. Nonpitting induration of the back. Scleredema adultorum of Buschke type III. *Arch Dermatol* 1997; **133**: 649, 652.
52. Cole HG, Winkelmann RK. Acid mucopolysaccharide staining in scleredema. *J Cutan Pathol* 1990; **17**: 211–213.
53. Cole GW, Headley J, Skowsky R. Scleredema diabetorum: a common and distinct cutaneous manifestation of diabetes mellitus. *Diabetes Care* 1983; **6**: 189–192.
54. Cole GW, Handler SJ, Burnett K. The ultrasonic evaluation of skin thickness in scleredema. *J Clin Ultrasound* 1981; **9**: 501–503.
55. Mylona E, Golfopoulou S, Skarmea A, *et al.* Post-radiation scleredema adultorum and diffuse eosinophilic fasciitis in the same patient. *Scand J Rheumatol* 2011; **40**: 240–241.
56. Kokpol C, Rajatanavin N, Rattanakemakorn P. Successful treatment of scleredema diabetorum by combining local PUVA and colchicine: a case report. *Case Rep Dermatol* 2012; **4**: 265–268.
57. Nakajima K, Iwagaki M, Ikeda M, Kodama H. Two cases of diabetic scleredema that responded to PUVA therapy. *J Dermatol* 2006; **33**: 820–822.
58. Grundmann-Kollmann M, Ochsendorf F, Zollner TM, Spieth K, Kaufmann R, Podda M. Cream PUVA therapy for scleredema adultorum. *Br J Dermatol* 2000; **142**: 1058–1059.
59. Hager CM, Sobhi HA, Hunzelmann N, *et al.* Bath-PUVA therapy in three patients with scleredema adultorum. *J Am Acad Dermatol* 1998; **38**(2 Pt 1): 240–242.
60. Yoshimura J, Asano Y, Takahashi T, *et al.* A case of scleredema adultorum successfully treated with narrow-band ultraviolet B phototherapy. *Mod Rheumatol* 2014; doi: 10.3109/14397595.2013.875640.

61. Mattheou-Vakali G, Ioannides D, Thomas T, Lazaridou E, Tsogas P, Minas A. Cyclosporine in scleredema. *J Am Acad Dermatol* 1996; **35**: 990–991.
62. Dogramaci AC, Inan MU, Atik E, Gokce C. Scleredema diabetorum partially treated with low-dose methotrexate: a report of five cases. *Balkan Med J* 2012; **29**: 218–221.
63. Breuckmann F, Appelhans C, Harati A, Rotterdam S, Altmeyer P, Kreuter A. Failure of low-dose methotrexate in the treatment of scleredema diabetorum in seven cases. *Dermatology* 2005; **211**: 299–301.
64. Rongioletti F, Kaiser F, Cinotti E, *et al.* Scleredema. A multicentre study of characteristics, comorbidities, course and therapy in 44 patients. *J Eur Acad Dermatol Venereol* 2015; **29**: 2399–2404.
65. Lee MW, Choi JH, Sung KJ, Moon KC, Koh JK. Electron beam therapy in patients with scleredema. *Acta Derm Venereol* 2000; **80**: 307–308.
66. Tamburin LM, Pena JR, Meredith R, Soong VY. Scleredema of Buschke successfully treated with electron beam therapy. *Arch Dermatol* 1998; **134**: 419–422.
67. Pilgrim U, Vogel A, Meves C. [Connective tissue fibers in scleromyxedema and scleredema adultorum. A quantitative electron microscopic study (author's transl)]. *Dermatologica* 1973; **147**: 46–63.
68. Stables GI, Taylor PC, Hight AS. Scleredema associated with paraproteinaemia treated by extracorporeal photopheresis. *Br J Dermatol* 2000; **142**: 781–783.
69. Alsaeedi SH, Lee P. Treatment of scleredema diabetorum with tamoxifen. *J Rheumatol* 2010; **37**: 2636–2637.
70. Eastham AB, Femia AN, Velez NF, Smith HP, Vleugels RA. Paraproteinemia-associated scleredema treated successfully with intravenous immunoglobulin. *JAMA Dermatol* 2014; **150**: 788–789.
71. Krasagakis K, Hettmannsperger U, Trautmann C, Tebbe B, Garbe C. Persistent scleredema of Buschke in a diabetic: improvement with high-dose penicillin. *Br J Dermatol* 1996; **134**: 597–598.
72. Frank H. [Experience with ACTH and hyaluronidase treatment of a case of scleredema adultorum Buschke, Mayr type]. *Hautarzt* 1954; **5**: 514–515.
73. Venturi C, Zendri E, Santini M, Grignaffini E, Ricci R, De Panfilis G. Scleredema of Buschke: remission with factor XIII treatment. *Int J Tissue React* 2004; **26**: 25–28.
74. Bowen AR, Smith L, Zone JJ. Scleredema adultorum of Buschke treated with radiation. *Arch Dermatol* 2003; **139**: 780–784.

75. Kroft EB, de Jong EM. Scleredema diabetorum case series: successful treatment with UV-A1. *Arch Dermatol* 2008; **144**: 947–948.
76. Kroft EB, Berkhof NJ, van de Kerkhof PC, Gerritsen RM, de Jong EM. Ultraviolet A phototherapy for sclerotic skin diseases: a systematic review. *J Am Acad Dermatol* 2008; **59**: 1017–1030.
77. Parmar RC, Bavdekar SB, Bansal S, Doraiswamy A, Khambadkone S. Scleredema adultorum. *J Postgrad Med* 2000; **46**: 91–93.
78. Pitarch G, Torrijos A, Martinez-Aparicio A, Vilata JJ, Fortea JM. [Scleredema of Buschke associated with diabetes mellitus. Study of four cases]. *Actas Dermosifiliogr* 2005; **96**: 46–49.