

A BAFFLING CASE OF SEVERE SYSTEMIC INFLAMMATION. PUTTING THE PIECES TOGETHER: GENES, ENVIRONMENT AND TRIGGERS

Geraint A. Brown¹, Amma Kyei-Mensah², Helen J Lachmann³, Elena Nikiphorou¹,
¹Rheumatology, The Whittington Hospital, London, UNITED KINGDOM, ²Obstetric &
Gynaecology, The Whittington Hospital, London, UNITED KINGDOM, ³National Amyloidosis
Centre, UCL, London, UNITED KINGDOM.

Sir,

Autoinflammatory syndromes are caused by an exaggerated innate immune system response and can pose important diagnostic challenges. They are often diagnosed by a combination of clinical findings and genetic testing. First presentation is often in childhood, although 10% of patients develop their first symptoms after the age of 30¹.

Herein we report a complex case with heterozygosity for MEFV with atypical Adult Onset Still's Disease (AOSD) in a 39-year-old Colombian woman, in her 3rd pregnancy trimester. At 33 weeks gestation, she presented with a sore throat, polyarthralgia, myalgia and pleuritic chest pains. She had an erythematous maculopapular rash thought to be pregnancy-related pruritic eruption. Earlier in pregnancy she had developed biopsy-confirmed reactive axillary lymphadenopathy. Past surgery included breast augmentation and bariatric surgery; family history unremarkable. Clinically she was tachycardic with wrist, metacarpophalangeal and proximal interphalangeal joint synovitis. She had bilateral pitting leg oedema which gradually spread to the abdomen, associated with worsening hypoalbuminaemia.

Inflammatory markers were raised; CRP 102mg/L, ESR60 mm/hr; white cell differential, ANA, ANCA, rheumatoid factor/anti-CCP and complement levels were all normal. Chest X-ray showed unilateral consolidation. She was commenced on prednisolone for suspected reactive arthritis with broad spectrum antibiotic cover. After a brief clinical improvement, she deteriorated, continuing to remain afebrile. Emergency caesarean section was performed at 34 weeks due to concerns over maternofetal wellbeing.

On day 3 post caesarean section she became febrile with worsening chest and joint pain. Abdominopelvic and chest CT and echocardiograph were normal. Colchicine was trialed unsuccessfully. Antibiotics were withdrawn after persistently negative microbiology tests with fever settling on day 6. She continued to deteriorate clinically with myalgia, arthralgia, abdominal and pleuritic chest pains. At this point, the possibility of an autoinflammatory syndrome +/- atypical AOSD was considered due to a raised ferritin (5154 µg/L) and CRP (300mg/L). After multidisciplinary discussion, intravenous methylprednisolone 1g/d was commenced for 3 days, along with intravenous immunoglobulins for 5 days. This regimen was successful with a dramatic improvement in her inflammatory markers (Figure 1) and clinical picture. Further investigations revealed raised serum amyloid A (703mg/L) and genetic testing confirmed the presence of MEFV I591T. The patient was discharged home and remains stable at 1-year follow-up on colchicine, azathioprine, and hydroxychloroquine.

FMF is the most common autoinflammatory syndrome resulting from mutations in the MEFV gene that encodes the protein pyrin which is involved in the regulation of inflammation and apoptosis; mutations lead to inflammation characterised by excessive Interleukin (IL)-1 secretion². Initially, five mutations (V726A, M694V, M694I, M680I and E148Q) were identified which account for 74% of all cases³.

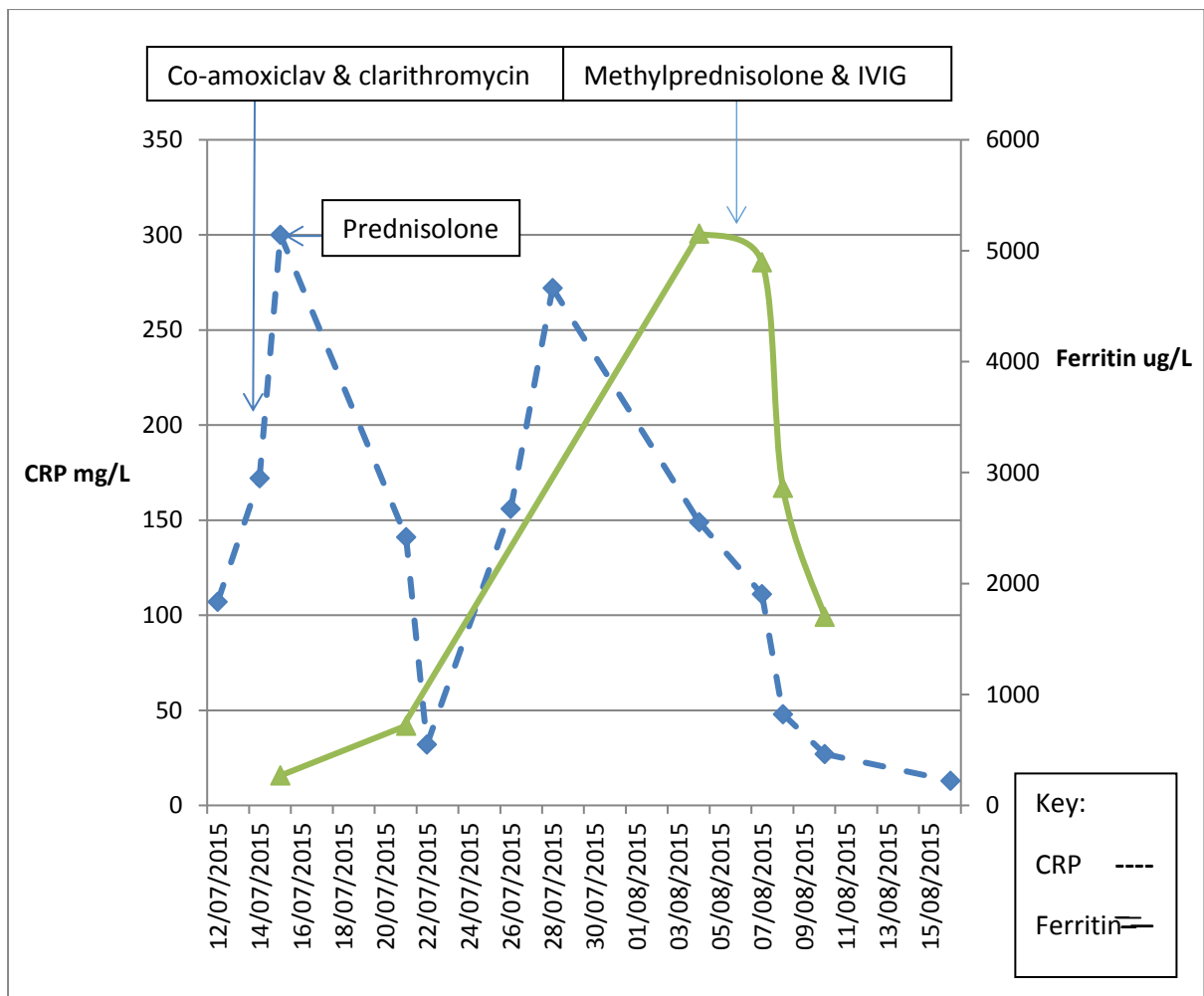
However, a number of other mutations have since been identified with their significance often unknown. Rare mutations are preferentially found in populations not normally associated with the disease. This includes I591T on exon 9, described in a patient from France³, and a Spanish family⁴ and associated with FMF both in conjunction with a second mutation and as the sole genetic abnormality. One hypothesis, for other MEFV genes being identified is that they may be involved in non-FMF conditions⁵.

Incidence is highest in populations around the Mediterranean but there are reported cases in Asia and South America. Classically, patients experience recurrent self-limiting episodes of fever and serositis. Pleural involvement occurs in 15% and is usually unilateral². The trigger to these events can be physical/emotional stress resulting in an intense acute phase reaction². Use of IL-1 receptor antagonists shows promise in patients who are intolerant to colchicine. AA amyloidosis and renal failure are serious complications if untreated.

AOSD is also considered an autoinflammatory disorder. Diagnosis is made clinically and relies on the classical triad of daily spiking fevers, polyarthritis and a salmon-pink evanescent rash. Other manifestations include a prodromal sore throat, myalgia, weight loss, serositis, lymphadenopathy, hepatomegaly and macrophage activation syndrome. Laboratory findings include raised inflammatory markers, normocytic anaemia, hypoalbuminaemia, and raised serum ferritin in 50% of cases. FMF-related MEFV variants are implicated with the disease phenotype of AOSD⁶.

This case is an example of a challenging autoinflammatory syndrome occurring in pregnancy in a patient of Hispanic ethnicity, heterozygote for an MEFV mutation and with no family history. Her clinical disease was not diagnostic of either FMF by the Tel-Hashomer criteria⁷ nor AOSD. Nonetheless some of the clinical/biochemical manifestations, particularly the high ferritin are much more consistent with AOSD than FMF. She responded well to methylprednisolone and has been well as an outpatient on broad spectrum immunosuppression and colchicine. Colchicine is very effective prophylaxis in FMF and has been reported to be beneficial in patients with disease associated with heterozygous carriage of MEFV I591T⁸. Furthermore, a Japanese study suggested that MEFV variants (excluding the very common polymorphism E148Q) are over-represented in AOSD and are associated with recurrent or severe inflammation and an increased requirement for biologics⁶. We hope that prophylactic colchicine will ameliorate any pro-inflammatory contribution from the variant pyrin. This case highlights the diagnostic dilemmas that can be associated with adult-onset autoinflammatory syndromes, as well as the importance of multi-disciplinary team input and coordinated care. Further exploration of MEFV I591T is required to evaluate its contribution to this patient's auto-inflammatory disease.

Figure 1: Relationship between inflammatory response and treatment.



Reference:

1. Toplak N, Frenkel J, Ozen S, et al. An international registry on autoinflammatory diseases: the Eurofever experience. *Ann Rheum Dis* 2012;71:1177–82.
2. Berkun Y, Eisenstein E M. Diagnostic criteria of familial Mediterranean fever. *Autoimmunity reviews* 13 (2014) 388-390.
3. Touitou I. The spectrum of Familial Mediterranean Fever (FMF) mutations. *Eur J Hum Genet.* 2001 Jul;9(7):473-83.
4. Aldea A, Casademont J, Aróstegui J I, Rius J et al. I591T MEFV mutation in a Spanish kindred: Is it a mild mutation, a benign polymorphism, or a variant influenced by another modifier? *Human mutation* 2002; 20:148-150.
5. Ozdogan H, Sayhan N, Melikoglu M et al: MEFV gene mutations in Turkish patients with FMF amyloidosis versus other secondary amyloidosis. Abstracts of the familial Mediterranean fever II international conference, 3 ± 7 May 2000, Antalya, Turkey. *Clin Exp Rheumatol* 2000; 18: E-5.

6. Nonaka F, Migita K, Jiuchi Y, Shimizu T, et al. Increased prevalence of MEFV exon 10 variants in Japanese patients with adult-onset Still's disease. *Clin Exp Immunol*. 2015 Mar; 179(3): 392-397.
7. Livneh A, Langevitz P, Zemer D, Zaks N, et al. Criteria for the diagnosis of familial Mediterranean fever. *Arthritis Rheum* 1997; 40: 1879-85.
8. Fisher BA, Lachmann HJ, Rowczenio D, Goodman HJ, Bhalara S, Hawkins PN. Colchicine responsive periodic fever syndrome associated with pyrin I591T. *Ann Rheum Dis*. 2005 Sep;64(9):1384-5.