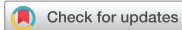

Review Article



OPEN ACCESS

Received: Mar 2, 2017

Revised: Apr 17, 2017

Accepted: Apr 18, 2017

Correspondence to

Nozomu Yanaihara

Department of Obstetrics and Gynecology,
 The Jikei University School of Medicine, 3-25-8
 Nishi-Shinbashi, Minato-ku, Tokyo 105-8461,
 Japan.

E-mail: yanazou@jikei.ac.jp

Copyright © 2017. Asian Society of
 Gynecologic Oncology, Korean Society of
 Gynecologic Oncology

This is an Open Access article distributed
 under the terms of the Creative Commons
 Attribution Non-Commercial License (<https://creativecommons.org/licenses/by-nc/4.0/>)
 which permits unrestricted non-commercial
 use, distribution, and reproduction in any
 medium, provided the original work is properly
 cited.

ORCID iDs

Nozomu Yanaihara 

<https://orcid.org/0000-0003-0160-7085>

Byoung-Gie Kim 


<https://orcid.org/0000-0002-0572-8450>

Takafumi Kuroda 

<https://orcid.org/0000-0002-2659-1449>

Ayako Kawabata 

<https://orcid.org/0000-0001-5220-4409>

Jae-Weon Kim 

<https://orcid.org/0000-0003-1835-9436>

Aikou Okamoto 

<https://orcid.org/0000-0002-5079-0464>

Conflict of Interest

No potential conflict of interest relevant to this
 article was reported.

<https://ejgo.org>

Update on rare epithelial ovarian cancers: based on the Rare Ovarian Tumors Young Investigator Conference

Ji Yon Agnes Jang,¹ Nozomu Yanaihara ,¹ Eric Pujade-Lauraine,² Yoshiki Mikami,³ Katsutoshi Oda,⁴ Michael Bookman,⁵ Jonathan Ledermann,⁶ Muneaki Shimada,⁷ Takako Kiyokawa,⁸ Byoung-Gie Kim ,⁹ Noriomi Matsumura,¹⁰ Tsunehisa Kaku,¹¹ Takafumi Kuroda ,¹ Yoko Nagayoshi,¹ Ayako Kawabata ,¹ Yasushi Iida,¹ Jae-Weon Kim ,¹² Michael Quinn,¹³ Aikou Okamoto 

¹Department of Obstetrics and Gynecology, The Jikei University School of Medicine, Tokyo, Japan

²Unité Cancer de la Femme et Recherche Clinique, Hôpitaux Universitaires Paris Centre, site Hôtel-Dieu, Université Paris Descartes, Paris, France

³Department of Diagnostic Pathology, Kumamoto University Hospital, Kumamoto, Japan

⁴Department of Obstetrics and Gynecology, Graduate School of Medicine, University of Tokyo, Tokyo, Japan

⁵US Oncology Research and Arizona Oncology, Tucson, AZ, USA

⁶UCL Cancer Institute, University College London, London, UK

⁷Department of Obstetrics and Gynecology, Tottori University School of Medicine, Yonago, Japan

⁸Department of Pathology, The Jikei University School of Medicine, Tokyo, Japan

⁹Gynecologic Cancer Center, Department of Obstetrics and Gynecology, Samsung Medical Center, Sungkyunkwan University School of Medicine, Seoul, Korea

¹⁰Department of Obstetrics and Gynecology, Kyoto University, Kyoto, Japan

¹¹Department of Health Sciences, Graduate School of Medical Science, Kyushu University, Fukuoka, Japan

¹²Department of Obstetrics and Gynecology, Seoul National University, Seoul, Korea

¹³Women's Cancer Research Center, Royal Women's Hospital, Melbourne, Australia

ABSTRACT

There has been significant progress in the understanding of the pathology and molecular biology of rare ovarian cancers, which has helped both diagnosis and treatment. This paper provides an update on recent advances in the knowledge and treatment of rare ovarian cancers and identifies gaps that need to be addressed by further clinical research. The topics covered include: low-grade serous, mucinous, and clear cell carcinomas of the ovary. Given the molecular heterogeneity and the histopathological rarity of these ovarian cancers, the importance of designing adequately powered trials or finding statistically innovative ways to approach the treatment of these rare tumors has been emphasized. This paper is based on the Rare Ovarian Tumors Conference for Young Investigators which was presented in Tokyo 2015 prior to the 5th Ovarian Cancer Consensus Conference of the Gynecologic Cancer InterGroup (GCIG).

Keywords: Rare Diseases; Ovarian Neoplasms

INTRODUCTION

At the Rare Ovarian Tumors Conference held in Tokyo 2015 prior to the 5th Ovarian Cancer Consensus Conference of the Gynecologic Cancer InterGroup (GCIG), young investigators addressed an update on recent advances in the knowledge and treatment of rare ovarian cancers, including low-grade serous, mucinous, and clear cell carcinomas of the ovary.

Author Contributions

Conceptualization: J.J.Y.A., Y.N., O.A.; Formal analysis: J.J.Y.A., Y.N., P.L.E., M.Y., O.K., B.M., L.J., S.M., K.T., K.B.G., M.N., K.T.; Funding acquisition: O.A.; Investigation: J.J.Y.A., Y.N., P.L.E., M.Y., O.K., B.M., L.J., S.M., K.T., K.B.G., M.N., K.T.; Methodology: P.L.E., M.Y., O.K., B.M., L.J., S.M., K.T., K.B.G., M.N., K.T.; Supervision: K.J.W., Q.M., O.A.; Validation: Y.N., K.T., N.Y., K.A., I.Y., K.J.W., Q.M., O.A.; Writing - original draft: J.J.Y.A., Y.N., P.L.E., M.Y., O.K., B.M., L.J., S.M., K.T., K.B.G., M.N., K.T.; Writing - review & editing: K.J.W., Q.M., O.A.

The contents of this article were presented in the Rare Ovarian Tumors Young Investigator Conference at The Jikei University School of Medicine, Tokyo, Japan on 6th November 2015.

LOW-GRADE SEROUS CARCINOMA (LGSC)

1. Background

Recent studies have identified low-grade and high-grade serous carcinomas (HGSC) as 2 distinct entities and the new edition of the World Health Organization (WHO) classification, published in 2014, has adopted this binary classification. Traditional 3-tiered grading of serous carcinoma had limited significance in terms of prognosis, management strategies, and biology, whereas the 2-tier system well reflects the molecular pathogenesis, clinicopathologic features, and epidemiology. These criteria for grading, established by Malpica et al. [1], have now been widely accepted. LGSC defined as serous carcinoma composed of uniform cells showing mild to moderate nuclear atypia and fewer mitotic figures (12 or less, and in general, mostly 2 to 3 per 10 high power fields [HPFs]), is a rare neoplasm accounting for 5%–10% of all ovarian serous carcinomas. Very rarely, LGSC may give rise to HGSC or undifferentiated carcinoma [2].

2. Understanding the difference between LGSC and HGSC

LGSC and HGSC differ distinctly in presentation, histogenesis, treatment strategies, and outcome (Table 1). The former is characterised by younger age, and paradoxically, poor response to conventional chemotherapy [3-7]. It is mitotically less active, and immunohistochemically shows a low Ki-67 labelling index. Since *TP53* is typically intact, *TP53* immunostaining shows wild-type pattern, aiding distinction of LGSC from HGSC. *KRAS*, *BRAF*, or *ERBB2* mutations are common in contrast to HGSC, which is characterised nearly uniform loss of *TP53* function due to mutation or deletion, associated with significant chromosomal instability and decreased overall survival (OS) [8].

HGSC is considered to rise de novo in association with serous tubal intraepithelial carcinoma (STIC). On the other hand, LGSC appears to have a close phenotypic relationship to serous borderline tumors (SBT), particularly of the micropapillary type, because of similar cytomorphology, occasional co-existence of both borderline and low-grade components, and overexpression of *CDKN1A* and other *TP53* modulated genes [9] indicating the existence of adenoma-carcinoma sequence [10]. Therefore, the revised WHO classification (2014) specifically defines micropapillary SBT as non-invasive LGSC.

Table 1. Differentiating low- and high-grade serous carcinoma

Feature	LGSC	HGSC	Source
Nuclear atypia	Uniform	Pleomorphic	[1]
Form	Oval/round	Variable	[1]
Size and shape	Uniform	Variable (>3:1) in size	[1]
Nucleoli	May exist	Present	[1]
Mitotic index/10 HPFs	≤12	>12	[1]
Precursor	SBT	STIC	[7]
Incidence	4%–10%	>85%	[6]
Median age	Younger, <50 yr	Older, >50 yr	[6]
Stage at presentation	Early in about 40%	Advanced in 70%–80%	[6]
Clinical course	Indolent	Aggressive	[6]
Response to chemotherapy	Usually poor	Good but with high recurrence rate	[3–5]
Chromosomal instability	Low	High	[13]
Gene mutation	<i>KRAS</i> , <i>BRAF</i> , and <i>ERBB2</i>	<i>TP53</i>	[8]
5-yr survival	50%–60%	30%–40%	[4,6,7,15]

HGSC, high-grade serous carcinoma; HPF, high power field; LGSC, low-grade serous carcinoma; SBT, serous borderline tumor; STIC, serous tubal intraepithelial carcinoma.

SBT shares a common high *KRAS* mutation rate with LGSC (20%–40% of cases), and much more frequently shows *BRAF* mutations compared with LGSC (30%–50% vs. 0%–30%) especially in advanced stages [8-11]. Deletion of tumor-suppressor function of *miR-34a* and *CDKN2A/B* has been suggested to be implicated in the progression of SBT to LGSC, although this finding remains to be confirmed by further evaluation [12]. The distinction between SBT and LGSC is critical for deciding on conservative or radical surgical management, since fertility is often a major concern in younger patients especially with bilateral disease [13]. A recent study has demonstrated that women below the age of 35 years with persistent disease at completion of initial therapy have a poorer outcome [14]. There has been a suggested association between an increased risk for developing LGSC in women who have a history of endometriosis [15].

3. Treatment targets

Traditional platinum-taxane combination chemotherapy has shown to have lower activity in LGSC compared to HGSC [5]. Commonly, primary cytoreductive surgery followed by adjuvant platinum based chemotherapy for advanced disease has been the standard practice in many countries despite limited evidence of benefit from chemotherapy [16-19]. Targeted therapies have, however, shown considerable promise, mainly in small non-randomized trials. Bevacizumab; Grisham et al. [20] performed a retrospective review of 17 patients who were treated with bevacizumab, 15 of whom were treated with combinations and 2 with bevacizumab alone. A partial response was obtained in 40% of the patient group (95% confidence interval [CI]=16.3%–67.7%). Similar results were obtained in a retrospective review performed by Schmeler et al. [21], with a response rate of 41% in a group of 21 patients. The value of bevacizumab in first-line treatment of serous ovarian cancers has been demonstrated in 2 phase III randomised studies; the GCIIG International Collaboration on Ovarian Neoplasms 7 (ICON7) trial and the complementary Gynecologic Oncology Group study 0218 (GOG-0218) with promising results, however there were limited data in lower grade cancers (**Table 2**) [22,23]. For recurrent disease, surgery remains the most effective intervention, and should be performed whenever possible. Hormonal therapy; LGSC express higher levels of estrogen receptor (ER), progesterone receptor (PR), and E-cadherin than HGSC, suggesting the possibility of these receptors as potential targets of therapy [24] and treatment with tamoxifen and letrozole has been shown to provide clinical benefit in epithelial ovarian cancers overall [25,26]. A retrospective review of hormonal intervention suggested moderate anti-tumor activity in cases of recurrent LGSC with the median time to progression (TTP) being 7.4 months (95% CI=6.0–8.9 months), and that patients with both ER and PR double positive tumors had longer TTP than those who were PR negative. The study concluded that the stability of ER and PR in LGSC in the long term however was questionable and hence further studies are required [27]. Vemurafenib; the presence of V600E *BRAF* mutations, although low in incidence, is associated with an improved prognosis and is more frequently seen in early stage disease [28]. Treatment with vemurafenib, a

Table 2. Bevacizumab in low- and high-grade serous carcinoma

Trial	No. of patients	HR
GOG-0218 [22]		
Low-grade	235	0.59
High-grade	842	0.70
ICON7 [23]		
Grade 1	97	0.76
Grade 2	317	0.77
Grade 3	1,094	0.81

GOG, Gynecologic Oncology Group; HR, hazard ratio; ICON7, International Collaboration on Ovarian Neoplasms 7.

BRAF inhibitor specific for V600E mutations has shown long term partial responses with improvement in both CA125 levels and in symptom control [29]. Mitogen-activated protein kinase kinase (MEK) inhibitors; Selumetinib (AZD6244, ARRY-142886) an orally available small molecule inhibitor of the MEK pathway was tested in a phase II clinical trial of 52 patients with LGSC. The median progression-free survival (PFS) was 11 months with a response rate of 15% (90% CI=7.9%–26.1%). The response to selumetinib did not appear to be related to *RAS/RAF* mutation status owing to significant tumor heterogeneity, and other factors that may contribute to pathway activation [30]. A randomized phase II/III trial is currently underway for trametinib, a MEK inhibitor, in recurrent or progressive low-grade serous ovarian cancer (GOG281), comparing the effectiveness of trametinib to chemotherapy chosen by the physician [31]. The MEK inhibitor in low-grade serous ovarian cancer (MILO) trial, an international, randomized phase III study of binimetinib or a chemotherapy chosen by a physician in patients with recurrent or persistent LGSC, was closed earlier after a planned interim analysis which showed that the hazard ratio for PFS crossed the predefined futility boundary [32]. Insulin-like growth factor 1 (IGF-1) pathway; IGF-1 is overexpressed in LGSC compared to SBT and HGSC and IGF-1 and Akt activation may be a potential drug target in the future [33]. Phase II trials are currently underway with the anti-IGF-1R monoclonal antibodies figitumumab (CP-751871) and ganitumab (AMG479) in epithelial ovarian cancer.

4. Take home message

As LGSC demonstrates distinct clinicopathologic and molecular features, it should be distinguished from HGSC in future clinical trials with translational components incorporated into their design. International cooperation will be required to establish strategies employing targeted agents as well as defining effective prognostic and predictive biomarkers. Finally, gynaecologic oncologists should be aware of the rare coexistence or progression to HGSC in cases of LGSC or SBT which can be a pitfall in management.

MUCINOUS CARCINOMA

1. Background

Ovarian mucinous carcinoma (OMC) is defined as an epithelial tumor with frank invasion (the largest invasive area equal to or greater than 5 mm) composed of gastrointestinal-type cells containing intracytoplasmic mucin. Recent studies have revealed that primary OMCs are much less common than previously reported (2%–3% of primary ovarian carcinomas), and that those reported as primary OMCs in the past likely included some metastatic tumors as well as mucinous borderline tumors [34,35]. There are 2 types of invasion in OMCs, expansile (or confluent glandular) and infiltrative, which may coexist in a single tumor (**Table 3**). The pathological distinction of pattern of invasion is important, as there is significant difference in prognosis between those with confluent and infiltrative type of invasion. Majority of OMCs are with expansile invasion, almost always stage I, and are usually associated with a favourable prognosis [36–38]. In contrast, about 80% of OMCs with infiltrative invasion are stage I, 20% of which recur. Recurrences tend to occur within 3 years of diagnosis and do not respond to chemotherapy or radiotherapy.

Distinction between primary OMCs and metastatic tumors may be pathologically challenging, although careful gross examination and thorough sampling of the tumor with assistance of immunohistochemistry in certain situation could lead to a correct diagnosis in many of the

Table 3. Classification of mucinous tumors of the ovary

Type	Subtype
Benign	Cystadenoma Cystadenofibroma
Borderline	Borderline with intraepithelial atypia Borderline with microinvasion <5 mm Borderline with microinvasive carcinoma
Carcinoma (frank invasion \geq 5 mm)	Confluent type Infiltrative type

cases. Those with bilaterality, small size (<10 cm in diameter), high-stage, and an infiltrative invasion should raise suspicion for metastatic tumors [34, 39-41]. The pathological features that favour primary mucinous tumors include: size >10 cm in diameter, multilocular cystic and/or solid tumor without multiple nodules, smooth external surface, expansile pattern of invasion, complex papillary pattern, coexistence of borderline or benign components, an association with a teratoma, endometriosis, adenofibroma, Brenner tumor, or mural nodule. Because OMCs typically form large cystic masses with or without solid component and are frequently admixed with benign and borderline components, sampling is crucial for accurate pathological diagnosis of OMCs. The number of the sections recommended is at least one per centimetre of maximum tumor dimension for tumor smaller than 10 cm, and 2 sections per centimetre for larger tumors [41].

2. Dilemmas in diagnosis and management

A small portion of advanced-stage mucinous tumors of the ovary are primary in origin (20%) and most are metastatic tumors from the gastrointestinal tract (45%), pancreas (20%), cervix (13%), breast (8%), uterus (5%), or unknown (10%) [35]. Clinicians face great challenge in pathologically distinguishing a primary mucinous tumor of ovarian origin from a metastatic tumor. In this case, molecular and clinical features may aid in distinguishing the two (**Table 4**) [40-45]. A retrospective analysis of GOG182/ICON5 on independent review of 44 stage III/IV mucinous carcinomas of the ovary by 3 different pathologists, showed that median survival did not differ greatly between primary or metastatic groups. However, many of those mucinous carcinomas that were initially diagnosed as primary OMC appeared to be metastatic in origin [46].

Table 4. Differentiating mucinous carcinomas of primary vs. metastatic origin

Feature	Primary	Metastatic
Pathological pattern	Intracellular mucin (>50%), in at least 90% of tumor cells Complex papillary pattern	Abundant extracellular mucin, in 50% or greater tumor volume Nodular pattern
Involvement	Coexistence of borderline/benign mucinous component Expansile pattern of invasion	Ovarian surface involvement Hilar involvement Vascular invasion Extensive infiltrative pattern of invasion
Size and distribution	Unilateral Size >10 cm	Bilateral Size <10 cm
Markers	CA125 CEA >25	Elevation may be present, although less than in colorectal primary cancers
Molecular alterations	<i>KRAS</i> mutations: 43% <i>BRAF</i> mutations: 0% <i>HER2</i> amplification: 18%	<i>KRAS</i> mutations: 30% <i>BRAF</i> mutations: 20% <i>HER2</i> amplification: <1%

CEA, carcinoembryonic antigen; *HER2*, human epidermal growth factor receptor 2.

Table 5. Comparison of OS and PFS in OMC compared to serous ovarian carcinoma

Study	Median OS (mon)	Median PFS (mon)
Winter et al. [47]		
Serous	45.1	16.9
Mucinous	14.8	10.5
Alexandre et al. [48]		
Serous	47.2	17.5
Mucinous	21.6	11.4
Tian et al. [49]		
Serous	40.5	16.7
Mucinous	11.3	9.7
Mackay et al. [50]		
Serous	40.8	16.1
Mucinous	14.6	7.6

OMC, ovarian mucinous carcinoma; OS, overall survival; PFS, progression-free survival.

As most OMCs present with localized disease (more than 80% of OMCs are stage I at the time of diagnosis), the standard treatment for patients with early mucinous carcinomas is cytoreductive surgery with pathological evaluation accompanied by surgical staging and special attention to possible gastrointestinal sites of primary disease. Nodal staging is not required in stage IA/IB due to the almost absence of nodal involvement. In younger patients with unilateral early stage disease it is reasonable to consider fertility sparing surgery. Furthermore, there is no clear evidence to suggest that adjuvant chemotherapy is beneficial in the setting of early stage disease. There is limited evidence for the effectiveness of systemic therapy in late stage OMCs. Most notably, only 2%–7% of patients in large randomized controlled trials had mucinous carcinomas. A retrospective review by Winter et al. [47] which investigated the effects of platinum/paclitaxel post debulking surgery in the mucinous cancer group, showed a median OS of 14.8 months comparable to 45.1 months in the serous group. Mimicking Winter's study, results produced by the Groupe d'Investigateurs Nationaux Pour les Etudes des Cancers de l'Ovaire (GINECO), GOG, and GCIG group have yielded similar results (**Table 5**) [48-50].

Disappointing results with first line platinum-based chemotherapy in OMCs have prompted research into specific targeted therapy such as agents that act on the human epidermal growth factor receptor 2 (*HER2*)/*neu*, *KRAS*, or angiogenesis pathways. A phase III study of carboplatin/paclitaxel vs. oxaliplatin/capecitabine with or without bevacizumab showed hope that bevacizumab may delay progression; however, the study was stopped early due to poor accrual of patients [51]. Molecular characterisation of mucinous ovarian tumors has shown overexpression of *HER2* in 19% of cases with perfect agreement on immunohistochemistry, fluorescence in situ hybridization (FISH), and chromogenic in situ hybridization (CISH) [52]. A higher incidence of *HER2* overexpression in the Asian population has been postulated by Chay et al. [53], and whilst the impact of *HER2* status on OS is yet to be clearly established, anti-*HER2* therapy in combination with other agents may have a role in management [54,55].

3. Take home message

It is unfortunate that large trials for mucinous carcinomas in the international setting have been largely unsuccessful, and the best treatment is still unknown. As mucinous carcinomas have been shown to harbour a variety of molecular changes, the efficacy of single agent targeted therapy may be limited. Moreover, it is difficult to design adequately powered randomized controlled trials in cancers of such rare histological subtype. It will be important to use innovative trial designs to overcome this difficulty.

CLEAR CELL CARCINOMA

1. Background

Ovarian clear cell carcinoma (OCCC) is a subtype of epithelial ovarian carcinoma which is distinct from HGSC, associated with poor prognosis in advanced stages and has been shown to be resistant to conventional platinum-based chemotherapy [56]. It accounts for 5%–25% of epithelial ovarian cancers with a higher incidence seen in Eastern-Asian women. Women with OCCC usually present early with 57%–81% presentations in stage I or II, and are younger (median age 55 years) and the disease is commonly associated with endometriosis. Hypercalcaemia and an increased incidence of venous thrombotic events may occur [57].

Histological features of OCCC include a variety of growth patterns (micropapillary, tubulocystic, solid, and adenofibromatous), cell types (hobnail, clear cell, and oxyphilic), stromal changes (hyalinized, necrotic, hemorrhagic, and psammomatous calcification), and the presence of endometriosis, atypical endometriosis, and atypical proliferative clear cell tumors [58–60]. These histological features often co-exist in the one tumor. Serous or endometrioid carcinoma frequently demonstrates cytoplasmic clearing (clear cell change), which leads to difficulty in accurate diagnoses of OCCC. A mitotic count greater than 5 per 10 HPFs is almost never encountered, with most tumors having mitotic counts between 0 and 2 per 10 HPFs [59]. The tumor arises from endometriosis in 50%–70% of cases [58]. An adenofibromatous pattern is present in 20%–25% of cases, and stromal hyalinization is one of the characteristic features [58,59].

2. Molecular changes in OCCC and translational possibilities

The molecular pathogenesis of OCCC is less well characterised than HGSC, however many studies show that it harbors unique molecular features including the AT-rich interactive domain 1A (*ARID1A*) gene mutation, hepatocyte nuclear factor-1 β (HNF-1 β) overexpression, and the phosphatidylinositol-4,5-bisphosphate 3-kinase (*PIK3CA*) mutation (**Table 6**) [61,62]. *ARID1A* encodes a key component of the switch/sucrose nonfermentable (SWI/SNF) chromatin remodelling complex that regulates gene expression targeting multiple pathways that lead to tumorigenesis. It acts as a tumor-suppressor gene in OCCC and is seen in pre-neoplastic lesions leading to the speculation that this gene is implicated in the early transformation of endometriotic cells into cancer. It has been identified in up to 57% of cases of OCCC however no distinct phenotypical property has been identified that may contribute to increased survival [63–66]. HNF-1 β is a transcription factor with predominant expression in liver, pancreas, and kidney and is known as a hallmark of OCCC. HNF-1 β plays multiple roles in tumorigenesis and

Table 6. Summary of mutated genes in OCCC [61–75]

Type	Gene	Frequency of mutation (%)
Oncogene	<i>PIK3CA</i>	54
	<i>KRAS</i>	10
	<i>PPP2R1A</i>	10
Tumor suppressor	<i>ARID1A</i>	62
	<i>MLL3</i>	15
	<i>ARID1B</i>	8
	<i>ASXL1</i>	8
	<i>CHD8</i>	8
	<i>PIK3R1</i>	8

ARID1A, AT-rich interactive domain 1A; *ARID1B*, AT-rich interactive domain 1B; *ASXL1*, additional sex combs-like 1; *CHD8*, chromodomain helicase DNA binding protein 8; *MLL3*, mixed-lineage leukemia protein 3; OCCC, ovarian clear cell carcinoma; *PIK3CA*, phosphatidylinositol-4,5-bisphosphate 3-kinase; *PPP2R1A*, protein phosphatase 2 regulatory subunit A alpha.

chemoresistance by alteration of glycolytic processes in OCCC cells, and by reducing oxidative phosphorylation and thus intracellular reactive oxygen species. Anti-stress properties that allow the survival of endometrial cells induce HNF-1 β in the microenvironment and this is maintained throughout its cell life into malignant proliferation. This conferred stress resistance may contribute to the chemoresistance of OCCC [67,68]. *PIK3CA* mutations play an important role in the pathogenesis of OCCC with mutations seen in up to 42% of cases. *PIK3CA* activation results in abnormal cellular growth, proliferation, survival, and angiogenesis via complex intracellular networks in the regulation of tumor stem cells. *PIK3CA* mutations have been associated with favourable OS in OCCC in a mutational analysis of 56 primary OCCC cases in Japanese women [69-72]. Vascular endothelial growth factor (VEGF) overexpression is commonly seen in advanced stage epithelial ovarian cancer and is often associated with a poorer prognosis [73,74]. With its critical role in angiogenesis, this overexpression may be a therapeutic target and in vitro studies have been promising, showing inhibition of OCCC cell growth especially in cisplatin-refractory cases, highlighting its potential role in recurrent disease [75].

3. Controversies in the clinical management of OCCC

Women with OCCC present in early stages, and at a younger age, raising the question of the role of cytoreductive vs. fertility sparing surgery. Evidence to support complete surgical staging in early stage OCCC is lacking; however, the goal of primary surgical treatment in advanced disease should be complete cytoreduction. In the GOG study by Hoskins in 1994, mucinous and clear cell subtypes demonstrated a poor outcome despite small residual tumor size even after primary cytoreductive surgery [76]. A retrospective analysis of 254 patients showed that only primary cytoreduction which was complete contributed to a better in advanced cases [77]. On a similar note, the role of lymphadenectomy from a therapeutic perspective is unclear. It is acknowledged that the presence of lymph node metastases is an independent prognostic factor however it is not associated with OS on multivariate analysis [78-82]. Importantly, women undergoing fertility sparing surgery in OCCC did not show poorer survival than their non-OCCC counterparts [83-87].

OCCC demonstrates a lower response rate to platinum based chemotherapy compared to HGSC, with response rates of 11%–56% compared to 73%–81% in serous subtypes [77]. The Japanese Gynecologic Oncology Group (JGOG) undertook a randomized phase III trial (JGOG3017) of paclitaxel/carboplatin versus irinotecan/cisplatin as first-line chemotherapy in patients with stage IC–IV OCCC which showed no significant difference in 2-year PFS or OS [88], suggesting the need for an alternative approach such as targeted therapy.

4. Take home message

There are still significant gaps in our understanding of OCCC. The effect of hormonal status on malignant transformation is incompletely understood and the risks of subsequent malignancy in women with endometriosis remains unclear. A number of international trials have been designed with the aim of identifying molecular targets; however, it is acknowledged that the presence of such targets may not translate into the effectiveness of agents used to target them. Adequately powered trials with novel designs will be necessary to provide improved clinical outcomes for patients with these rare tumors.

CONCLUSION

Designing adequately powered studies to perform large scale randomized trials is the single largest barrier in improving understanding of rare epithelial ovarian cancers. International

collaboration with multidisciplinary and translational components through groups such as the GCIG is required. Multiple smaller trials which screen agents for activity should be considered in the first instance, with expansion into larger randomized trials for agents that show promising activity. Additionally, the poor prognosis associated with many of these rare cancers at advanced stages signify the need for further research in developing novel methods for screening.

ACKNOWLEDGMENTS

The authors acknowledge that all delegates to this conference, including all the staff members of the Obstetrics and Gynecology Department of The Jikei University School of Medicine.

REFERENCES

1. Malpica A, Deavers MT, Lu K, Bodurka DC, Atkinson EN, Gershenson DM, et al. Grading ovarian serous carcinoma using a two-tier system. *Am J Surg Pathol* 2004;28:496-504.
[PUBMED](#) | [CROSSREF](#)
2. Boyd C, McCluggage WG. Low-grade ovarian serous neoplasms (low-grade serous carcinoma and serous borderline tumor) associated with high-grade serous carcinoma or undifferentiated carcinoma: report of a series of cases of an unusual phenomenon. *Am J Surg Pathol* 2012;36:368-75.
[PUBMED](#) | [CROSSREF](#)
3. Gershenson DM, Sun CC, Bodurka D, Coleman RL, Lu KH, Sood AK, et al. Recurrent low-grade serous ovarian carcinoma is relatively chemoresistant. *Gynecol Oncol* 2009;114:48-52.
[PUBMED](#) | [CROSSREF](#)
4. Gershenson DM, Sun CC, Lu KH, Coleman RL, Sood AK, Malpica A, et al. Clinical behavior of stage II-IV low-grade serous carcinoma of the ovary. *Obstet Gynecol* 2006;108:361-8.
[PUBMED](#) | [CROSSREF](#)
5. Schmeler KM, Sun CC, Bodurka DC, Deavers MT, Malpica A, Coleman RL, et al. Neoadjuvant chemotherapy for low-grade serous carcinoma of the ovary or peritoneum. *Gynecol Oncol* 2008;108:510-4.
[PUBMED](#) | [CROSSREF](#)
6. Plaxe SC. Epidemiology of low-grade serous ovarian cancer. *Am J Obstet Gynecol* 2008;198:459.e1-8.
[PUBMED](#) | [CROSSREF](#)
7. Kindelberger DW, Lee Y, Miron A, Hirsch MS, Feltmate C, Medeiros F, et al. Intraepithelial carcinoma of the fimbria and pelvic serous carcinoma: evidence for a causal relationship. *Am J Surg Pathol* 2007;31:161-9.
[PUBMED](#) | [CROSSREF](#)
8. Vang R, Shih IeM, Kurman RJ. Ovarian low-grade and high-grade serous carcinoma: pathogenesis, clinicopathologic and molecular biologic features, and diagnostic problems. *Adv Anat Pathol* 2009;16:267-82.
[PUBMED](#) | [CROSSREF](#)
9. Bonome T, Lee JY, Park DC, Radonovich M, Pise-Masison C, Brady J, et al. Expression profiling of serous low malignant potential, low-grade, and high-grade tumors of the ovary. *Cancer Res* 2005;65:10602-12.
[PUBMED](#) | [CROSSREF](#)
10. Kurman RJ, Shih IeM. Molecular pathogenesis and extraovarian origin of epithelial ovarian cancer--shifting the paradigm. *Hum Pathol* 2011;42:918-31.
[PUBMED](#) | [CROSSREF](#)
11. Shih IeM, Kurman RJ. Ovarian tumorigenesis: a proposed model based on morphological and molecular genetic analysis. *Am J Pathol* 2004;164:1511-8.
[PUBMED](#) | [CROSSREF](#)
12. Kuo KT, Guan B, Feng Y, Mao TL, Chen X, Jinawath N, et al. Analysis of DNA copy number alterations in ovarian serous tumors identifies new molecular genetic changes in low-grade and high-grade carcinomas. *Cancer Res* 2009;69:4036-42.
[PUBMED](#) | [CROSSREF](#)
13. Della Pepa C, Tonini G, Santini D, Losito S, Pisano C, Di Napoli M, et al. Low grade serous ovarian carcinoma: from the molecular characterization to the best therapeutic strategy. *Cancer Treat Rev* 2015;41:136-43.
[PUBMED](#) | [CROSSREF](#)

14. Gershenson DM, Bodurka DC, Lu KH, Nathan LC, Milojevic L, Wong KK, et al. Impact of age and primary disease site on outcome in women with low-grade serous carcinoma of the ovary or peritoneum: results of a large single-institution registry of a rare tumor. *J Clin Oncol* 2015;33:2675-82.
[PUBMED](#) | [CROSSREF](#)
15. Pearce CL, Templeman C, Rossing MA, Lee A, Near AM, Webb PM, et al. Association between endometriosis and risk of histological subtypes of ovarian cancer: a pooled analysis of case-control studies. *Lancet Oncol* 2012;13:385-94.
[PUBMED](#) | [CROSSREF](#)
16. Bookman MA, Brady MF, McGuire WP, Harper PG, Alberts DS, Friedlander M, et al. Evaluation of new platinum-based treatment regimens in advanced-stage ovarian cancer: a Phase III Trial of the Gynecologic Cancer Intergroup. *J Clin Oncol* 2009;27:1419-25.
[PUBMED](#) | [CROSSREF](#)
17. du Bois A, Weber B, Rochon J, Meier W, Goupil A, Olbricht S, et al. Addition of epirubicin as a third drug to carboplatin-paclitaxel in first-line treatment of advanced ovarian cancer: a prospectively randomized gynecologic cancer intergroup trial by the Arbeitsgemeinschaft Gynaekologische Onkologie Ovarian Cancer Study Group and the Groupe d'Investigateurs Nationaux pour l'Etude des Cancers Ovariens. *J Clin Oncol* 2006;24:1127-35.
[PUBMED](#) | [CROSSREF](#)
18. Hoskins P, Vergote I, Cervantes A, Tu D, Stuart G, Zola P, et al. Advanced ovarian cancer: phase III randomized study of sequential cisplatin-topotecan and carboplatin-paclitaxel vs carboplatin-paclitaxel. *J Natl Cancer Inst* 2010;102:1547-56.
[PUBMED](#) | [CROSSREF](#)
19. Pfisterer J, Weber B, Reuss A, Kimmig R, du Bois A, Wagner U, et al. Randomized phase III trial of topotecan following carboplatin and paclitaxel in first-line treatment of advanced ovarian cancer: a gynecologic cancer intergroup trial of the AGO-OVAR and GINECO. *J Natl Cancer Inst* 2006;98:1036-45.
[PUBMED](#) | [CROSSREF](#)
20. Grisham RN, Iyer G, Sala E, Zhou Q, Iasonos A, DeLair D, et al. Bevacizumab shows activity in patients with low-grade serous ovarian and primary peritoneal cancer. *Int J Gynecol Cancer* 2014;24:1010-4.
[PUBMED](#) | [CROSSREF](#)
21. Schmeler KM, Tao X, Sun CC, Malpica A, Deavers M, Sood A, et al. Encouraging responses with bevacizumab in recurrent low-grade serous ovarian cancer. *J Clin Oncol* 2010;28:abstr e15503.
22. Burger RA, Brady MF, Bookman MA, Fleming GF, Monk BJ, Huang H, et al. Incorporation of bevacizumab in the primary treatment of ovarian cancer. *N Engl J Med* 2011;365:2473-83.
[PUBMED](#) | [CROSSREF](#)
23. Perren TJ, Swart AM, Pfisterer J, Ledermann JA, Pujade-Lauraine E, Kristensen G, et al. A phase 3 trial of bevacizumab in ovarian cancer. *N Engl J Med* 2011;365:2484-96.
[PUBMED](#) | [CROSSREF](#)
24. Wong KK, Lu KH, Malpica A, Bodurka DC, Shvartsman HS, Schmandt RE, et al. Significantly greater expression of ER, PR, and ECAD in advanced-stage low-grade ovarian serous carcinoma as revealed by immunohistochemical analysis. *Int J Gynecol Pathol* 2007;26:404-9.
[PUBMED](#) | [CROSSREF](#)
25. Shirey DR, Kavanagh JJ Jr, Gershenson DM, Freedman RS, Copeland LJ, Jones LA. Tamoxifen therapy of epithelial ovarian cancer. *Obstet Gynecol* 1985;66:575-8.
[PUBMED](#)
26. Ramirez PT, Schmeler KM, Milam MR, Slomovitz BM, Smith JA, Kavanagh JJ, et al. Efficacy of letrozole in the treatment of recurrent platinum- and taxane-resistant high-grade cancer of the ovary or peritoneum. *Gynecol Oncol* 2008;110:56-9.
[PUBMED](#) | [CROSSREF](#)
27. Gershenson DM, Sun CC, Iyer RB, Malpica AL, Kavanagh JJ, Bodurka DC, et al. Hormonal therapy for recurrent low-grade serous carcinoma of the ovary or peritoneum. *Gynecol Oncol* 2012;125:661-6.
[PUBMED](#) | [CROSSREF](#)
28. Grisham RN, Iyer G, Garg K, DeLair D, Hyman DM, Zhou Q, et al. BRAF mutation is associated with early stage disease and improved outcome in patients with low-grade serous ovarian cancer. *Cancer* 2013;119:548-54.
[PUBMED](#) | [CROSSREF](#)
29. Combe P, Chauvenet L, Lefrère-Belda MA, Blons H, Rousseau C, Oudard S, et al. Sustained response to vemurafenib in a low grade serous ovarian cancer with a BRAF V600E mutation. *Invest New Drugs* 2015;33:1267-70.
[PUBMED](#) | [CROSSREF](#)

30. Farley J, Brady WE, Vathipadiekal V, Lankes HA, Coleman R, Morgan MA, et al. Selumetinib in women with recurrent low-grade serous carcinoma of the ovary or peritoneum: an open-label, single-arm, phase 2 study. *Lancet Oncol* 2013;14:134-40.
[PUBMED](#) | [CROSSREF](#)
31. ClinicalTrials.gov (US). Trametinib in treating patients with recurrent or progressive low-grade ovarian cancer or peritoneal cavity cancer [Internet]. Bethesda (MD): ClinicalTrials.gov; 2014 [cited 2014 Mar 28]. Available from: <https://clinicaltrials.gov/ct2/show/NCT02101788>.
32. ClinicalTrials.gov (US). A study of MEK162 vs. Physician's choice chemotherapy in patients with low-grade serous ovarian, fallopian tube or peritoneal cancer [Internet]. Bethesda (MD): ClinicalTrials.gov; 2013 [cited 2015 May 6]. Available from: <https://clinicaltrials.gov/ct2/show/NCT01849874>.
33. King ER, Zu Z, Tsang YT, Deavers MT, Malpica A, Mok SC, et al. The insulin-like growth factor 1 pathway is a potential therapeutic target for low-grade serous ovarian carcinoma. *Gynecol Oncol* 2011;123:13-8.
[PUBMED](#) | [CROSSREF](#)
34. Seidman JD, Kurman RJ, Ronnett BM. Primary and metastatic mucinous adenocarcinomas in the ovaries: incidence in routine practice with a new approach to improve intraoperative diagnosis. *Am J Surg Pathol* 2003;27:985-93.
[PUBMED](#) | [CROSSREF](#)
35. Shimada M, Kigawa J, Ohishi Y, Yasuda M, Suzuki M, Hiura M, et al. Clinicopathological characteristics of mucinous adenocarcinoma of the ovary. *Gynecol Oncol* 2009;113:331-4.
[PUBMED](#) | [CROSSREF](#)
36. Lee KR, Scully RE. Mucinous tumors of the ovary: a clinicopathologic study of 196 borderline tumors (of intestinal type) and carcinomas, including an evaluation of 11 cases with 'pseudomyxoma peritonei'. *Am J Surg Pathol* 2000;24:1447-64.
[PUBMED](#) | [CROSSREF](#)
37. Rodríguez IM, Prat J. Mucinous tumors of the ovary: a clinicopathologic analysis of 75 borderline tumors (of intestinal type) and carcinomas. *Am J Surg Pathol* 2002;26:139-52.
[PUBMED](#) | [CROSSREF](#)
38. Riopel MA, Ronnett BM, Kurman RJ. Evaluation of diagnostic criteria and behavior of ovarian intestinal-type mucinous tumors: atypical proliferative (borderline) tumors and intraepithelial, microinvasive, invasive, and metastatic carcinomas. *Am J Surg Pathol* 1999;23:617-35.
[PUBMED](#) | [CROSSREF](#)
39. Khunamornpong S, Suprasert P, Pojchamarnwiputh S, Na Chiangmai W, Settakorn J, Siriaunkgul S. Primary and metastatic mucinous adenocarcinomas of the ovary: evaluation of the diagnostic approach using tumor size and laterality. *Gynecol Oncol* 2006;101:152-7.
[PUBMED](#) | [CROSSREF](#)
40. Lee KR, Young RH. The distinction between primary and metastatic mucinous carcinomas of the ovary: gross and histologic findings in 50 cases. *Am J Surg Pathol* 2003;27:281-92.
[PUBMED](#) | [CROSSREF](#)
41. Frumovitz M, Schmeler KM, Malpica A, Sood AK, Gershenson DM. Unmasking the complexities of mucinous ovarian carcinoma. *Gynecol Oncol* 2010;117:491-6.
[PUBMED](#) | [CROSSREF](#)
42. Jung ES, Bae JH, Lee A, Choi YJ, Park JS, Lee KY. Mucinous adenocarcinoma involving the ovary: comparative evaluation of the classification algorithms using tumor size and laterality. *J Korean Med Sci* 2010;25:220-5.
[PUBMED](#) | [CROSSREF](#)
43. Maeda-Taniguchi M, Ueda Y, Miyake T, Miyatake T, Kimura T, Yoshino K, et al. Metastatic mucinous adenocarcinoma of the ovary is characterized by advanced patient age, small tumor size, and elevated serum CA125. *Gynecol Obstet Invest* 2011;72:196-202.
[PUBMED](#) | [CROSSREF](#)
44. Cao D, Ji H, Ronnett BM. Expression of mesothelin, fascin, and prostate stem cell antigen in primary ovarian mucinous tumors and their utility in differentiating primary ovarian mucinous tumors from metastatic pancreatic mucinous carcinomas in the ovary. *Int J Gynecol Pathol* 2005;24:67-72.
[PUBMED](#)
45. Pinto PB, Derchain SF, Andrade LA. Metastatic mucinous carcinomas in the ovary: a practical approach to diagnosis related to gross aspects and to immunohistochemical evaluation. *Int J Gynecol Pathol* 2012;31:313-8.
[PUBMED](#) | [CROSSREF](#)
46. Zaino RJ, Brady MF, Lele SM, Michael H, Greer B, Bookman MA. Advanced stage mucinous adenocarcinoma of the ovary is both rare and highly lethal: a Gynecologic Oncology Group study. *Cancer* 2011;117:554-62.
[PUBMED](#) | [CROSSREF](#)

47. Winter WE 3rd, Maxwell GL, Tian C, Carlson JW, Ozols RF, Rose PG, et al. Prognostic factors for stage III epithelial ovarian cancer: a Gynecologic Oncology Group Study. *J Clin Oncol* 2007;25:3621-7.
[PUBMED](#) | [CROSSREF](#)
48. Alexandre J, Ray-Coquard I, Selle F, Floquet A, Cottu P, Weber B, et al. Mucinous advanced epithelial ovarian carcinoma: clinical presentation and sensitivity to platinum-paclitaxel-based chemotherapy, the GINECO experience. *Ann Oncol* 2010;21:2377-81.
[PUBMED](#) | [CROSSREF](#)
49. Tian C, Markman M, Zaino R, Ozols RF, McGuire WP, Muggia FM, et al. CA-125 change after chemotherapy in prediction of treatment outcome among advanced mucinous and clear cell epithelial ovarian cancers: a Gynecologic Oncology Group study. *Cancer* 2009;115:1395-403.
[PUBMED](#) | [CROSSREF](#)
50. Mackay HJ, Brady MF, Oza AM, Reuss A, Pujade-Lauraine E, Swart AM, et al. Prognostic relevance of uncommon ovarian histology in women with stage III/IV epithelial ovarian cancer. *Int J Gynecol Cancer* 2010;20:945-52.
[PUBMED](#) | [CROSSREF](#)
51. Gore ME, Hackshaw A, Brady WE, Penson RT, Zaino RJ, McCluggage WG, et al. Multicentre trial of carboplatin/paclitaxel versus oxaliplatin/capecitabine, each with/without bevacizumab, as first line chemotherapy for patients with mucinous epithelial ovarian cancer (mEOC). *J Clin Oncol* 2015;33:abstr 5528.
52. Anglesio MS, Kommoss S, Tolcher MC, Clarke B, Galletta L, Porter H, et al. Molecular characterization of mucinous ovarian tumours supports a stratified treatment approach with HER2 targeting in 19% of carcinomas. *J Pathol* 2013;229:111-20.
[PUBMED](#) | [CROSSREF](#)
53. Chay WY, Chew SH, Ong WS, Busmanis I, Li X, Thung S, et al. HER2 amplification and clinicopathological characteristics in a large Asian cohort of rare mucinous ovarian cancer. *PLoS One* 2013;8:e61565.
[PUBMED](#) | [CROSSREF](#)
54. McAlpine JN, Wiegand KC, Vang R, Ronnett BM, Adamiak A, Köbel M, et al. HER2 overexpression and amplification is present in a subset of ovarian mucinous carcinomas and can be targeted with trastuzumab therapy. *BMC Cancer* 2009;9:433.
[PUBMED](#) | [CROSSREF](#)
55. Lin WL, Kuo WH, Chen FL, Lee MY, Ruan A, Tyan YS, et al. Identification of the coexisting HER2 gene amplification and novel mutations in the HER2 protein-overexpressed mucinous epithelial ovarian cancer. *Ann Surg Oncol* 2011;18:2388-94.
[PUBMED](#) | [CROSSREF](#)
56. Anglesio MS, Carey MS, Köbel M, Mackay H, Huntsman DG Vancouver Ovarian Clear Cell Symposium Speakers. Clear cell carcinoma of the ovary: a report from the first Ovarian Clear Cell Symposium, June 24th, 2010. *Gynecol Oncol* 2011;121:407-15.
[PUBMED](#) | [CROSSREF](#)
57. del Carmen MG, Birrer M, Schorge JO. Clear cell carcinoma of the ovary: a review of the literature. *Gynecol Oncol* 2012;126:481-90.
[PUBMED](#) | [CROSSREF](#)
58. Ogawa S, Kaku T, Amada S, Kobayashi H, Hirakawa T, Ariyoshi K, et al. Ovarian endometriosis associated with ovarian carcinoma: a clinicopathological and immunohistochemical study. *Gynecol Oncol* 2000;77:298-304.
[PUBMED](#) | [CROSSREF](#)
59. Kigawa J, Kaku T, Sugiyama T, Silverberg SG. Atlas of clear cell carcinoma of the ovary: a pathological guide. Tokyo: Springer; 2015.
60. Sugiyama T, Kamura T, Kigawa J, Terakawa N, Kikuchi Y, Kita T, et al. Clinical characteristics of clear cell carcinoma of the ovary: a distinct histologic type with poor prognosis and resistance to platinum-based chemotherapy. *Cancer* 2000;88:2584-9.
[PUBMED](#) | [CROSSREF](#)
61. Gounaris I, Brenton JD. Molecular pathogenesis of ovarian clear cell carcinoma. *Future Oncol* 2015;11:1389-405.
[PUBMED](#) | [CROSSREF](#)
62. Yamamoto S, Tsuda H, Takano M, Iwaya K, Tamai S, Matsubara O. PIK3CA mutation is an early event in the development of endometriosis-associated ovarian clear cell adenocarcinoma. *J Pathol* 2011;225:189-94.
[PUBMED](#) | [CROSSREF](#)
63. Wilson BG, Roberts CW. SWI/SNF nucleosome remodellers and cancer. *Nat Rev Cancer* 2011;11:481-92.
[PUBMED](#) | [CROSSREF](#)

64. Shigetomi H, Tsunemi T, Haruta S, Kajihara H, Yoshizawa Y, Tanase Y, et al. Molecular mechanisms linking endometriosis under oxidative stress with ovarian tumorigenesis and therapeutic modalities. *Cancer Invest* 2012;30:473-80.
[PUBMED](#) | [CROSSREF](#)
65. Jones S, Wang TL, Shih IeM, Mao TL, Nakayama K, Roden R, et al. Frequent mutations of chromatin remodeling gene ARID1A in ovarian clear cell carcinoma. *Science* 2010;330:228-31.
[PUBMED](#) | [CROSSREF](#)
66. Samartzis EP, Noske A, Dedes KJ, Fink D, Imesch P. ARID1A mutations and PI3K/AKT pathway alterations in endometriosis and endometriosis-associated ovarian carcinomas. *Int J Mol Sci* 2013;14:18824-49.
[PUBMED](#) | [CROSSREF](#)
67. Okamoto T, Mandai M, Matsumura N, Yamaguchi K, Kondoh H, Amano Y, et al. Hepatocyte nuclear factor-1 β (HNF-1 β) promotes glucose uptake and glycolytic activity in ovarian clear cell carcinoma. *Mol Carcinog* 2015;54:35-49.
[PUBMED](#) | [CROSSREF](#)
68. Mandai M, Amano Y, Yamaguchi K, Matsumura N, Baba T, Konishi I. Ovarian clear cell carcinoma meets metabolism; HNF-1 β confers survival benefits through the Warburg effect and ROS reduction. *Oncotarget* 2015;6:30704-14.
[PUBMED](#)
69. Xia P, Xu XY. PI3K/Akt/mTOR signaling pathway in cancer stem cells: from basic research to clinical application. *Am J Cancer Res* 2015;5:1602-9.
[PUBMED](#)
70. Li H, Zeng J, Shen K. PI3K/AKT/mTOR signaling pathway as a therapeutic target for ovarian cancer. *Arch Gynecol Obstet* 2014;290:1067-78.
[PUBMED](#) | [CROSSREF](#)
71. Mabuchi S, Kuroda H, Takahashi R, Sasano T. The PI3K/AKT/mTOR pathway as a therapeutic target in ovarian cancer. *Gynecol Oncol* 2015;137:173-9.
[PUBMED](#) | [CROSSREF](#)
72. Rahman M, Nakayama K, Rahman MT, Nakayama N, Ishikawa M, Katagiri A, et al. Clinicopathologic and biological analysis of PIK3CA mutation in ovarian clear cell carcinoma. *Hum Pathol* 2012;43:2197-206.
[PUBMED](#) | [CROSSREF](#)
73. Wong C, Wellman TL, Lounsbury KM. VEGF and HIF-1 α expression are increased in advanced stages of epithelial ovarian cancer. *Gynecol Oncol* 2003;91:513-7.
[PUBMED](#) | [CROSSREF](#)
74. Siddiqui GK, Maclean AB, Elmasry K, Wong te Fong A, Morris RW, Rashid M, et al. Immunohistochemical expression of VEGF predicts response to platinum based chemotherapy in patients with epithelial ovarian cancer. *Angiogenesis* 2011;14:155-61.
[PUBMED](#) | [CROSSREF](#)
75. Mabuchi S, Kawase C, Altomare DA, Morishige K, Hayashi M, Sawada K, et al. Vascular endothelial growth factor is a promising therapeutic target for the treatment of clear cell carcinoma of the ovary. *Mol Cancer Ther* 2010;9:2411-22.
[PUBMED](#) | [CROSSREF](#)
76. Hoskins WJ, McGuire WP, Brady MF, Homesley HD, Creasman WT, Berman M, et al. The effect of diameter of largest residual disease on survival after primary cytoreductive surgery in patients with suboptimal residual epithelial ovarian carcinoma. *Am J Obstet Gynecol* 1994;170:974-9.
[PUBMED](#) | [CROSSREF](#)
77. Takano M, Tsuda H, Sugiyama T. Clear cell carcinoma of the ovary: is there a role of histology-specific treatment? *J Exp Clin Cancer Res* 2012;31:53.
[PUBMED](#) | [CROSSREF](#)
78. Sakuragi N, Yamada H, Oikawa M, Okuyama K, Fujino T, Sagawa T, et al. Prognostic significance of lymph node metastasis and clear cell histology in ovarian carcinoma limited to the pelvis (pT1M0 and pT2M0). *Gynecol Oncol* 2000;79:251-5.
[PUBMED](#) | [CROSSREF](#)
79. Negishi H, Takeda M, Fujimoto T, Todo Y, Ebina Y, Watari H, et al. Lymphatic mapping and sentinel node identification as related to the primary sites of lymph node metastasis in early stage ovarian cancer. *Gynecol Oncol* 2004;94:161-6.
[PUBMED](#) | [CROSSREF](#)
80. Magazzino F, Katsaros D, Ottaiano A, Gadducci A, Pisano C, Sorio R, et al. Surgical and medical treatment of clear cell ovarian cancer: results from the multicenter Italian Trials in Ovarian Cancer (MITO) 9 retrospective study. *Int J Gynecol Cancer* 2011;21:1063-70.
[PUBMED](#) | [CROSSREF](#)

81. Chan JK, Munro EG, Cheung MK, Husain A, Teng NN, Berek JS, et al. Association of lymphadenectomy and survival in stage I ovarian cancer patients. *Obstet Gynecol* 2007;109:12-9.
[PUBMED](#) | [CROSSREF](#)
82. Suzuki S, Kajiyama H, Shibata K, Ino K, Nawa A, Sakakibara K, et al. Is there any association between retroperitoneal lymphadenectomy and survival benefit in ovarian clear cell carcinoma patients? *Ann Oncol* 2008;19:1284-7.
[PUBMED](#) | [CROSSREF](#)
83. Kajiyama H, Shibata K, Mizuno M, Hosono S, Kawai M, Nagasaka T, et al. Fertility-sparing surgery in patients with clear-cell carcinoma of the ovary: is it possible? *Hum Reprod* 2011;26:3297-302.
[PUBMED](#) | [CROSSREF](#)
84. Zanetta G, Chiari S, Rota S, Bratina G, Maneo A, Torri V, et al. Conservative surgery for stage I ovarian carcinoma in women of childbearing age. *Br J Obstet Gynaecol* 1997;104:1030-5.
[PUBMED](#) | [CROSSREF](#)
85. Schilder JM, Thompson AM, DePriest PD, Ueland FR, Cibull ML, Kryscio RJ, et al. Outcome of reproductive age women with stage IA or IC invasive epithelial ovarian cancer treated with fertility-sparing therapy. *Gynecol Oncol* 2002;87:1-7.
[PUBMED](#) | [CROSSREF](#)
86. Morice P, Leblanc E, Rey A, Baron M, Querleu D, Blanchot J, et al. Conservative treatment in epithelial ovarian cancer: results of a multicentre study of the GCCLCC (Groupe des Chirurgiens de Centre de Lutte Contre le Cancer) and SFOG (Société Française d'Oncologie Gynécologique). *Hum Reprod* 2005;20:1379-85.
[PUBMED](#) | [CROSSREF](#)
87. Satoh T, Hatae M, Watanabe Y, Yaegashi N, Ishiko O, Kodama S, et al. Outcomes of fertility-sparing surgery for stage I epithelial ovarian cancer: a proposal for patient selection. *J Clin Oncol* 2010;28:1727-32.
[PUBMED](#) | [CROSSREF](#)
88. Sugiyama T, Okamoto A, Enomoto T, Hamano T, Aotani E, Terao Y, et al. Randomized phase III trial of irinotecan plus cisplatin compared with paclitaxel plus carboplatin as first-line chemotherapy for ovarian clear cell carcinoma: JGOG3017/GCIG Trial. *J Clin Oncol* 2016;34:2881-7.
[PUBMED](#) | [CROSSREF](#)