



Retrieval evidence of impingement at the third articulation in contemporary dual mobility cups for total hip arthroplasty

Anna Di Laura^{1,2} · Harry S. Hothi^{1,2} · Johann Henckel^{1,2} · Arianna Cerquiglini^{1,2} · Ming Han Lincoln Liow³ · Young-Min Kwon³ · John A. Skinner^{1,2} · Alister J. Hart^{1,2}

Received: 15 February 2017 / Accepted: 16 May 2017
© The Author(s) 2017. This article is an open access publication

Abstract

Purpose We aimed to assess polyethylene liners of retrieved hips of one design of a dual mobility (DM) cup liner and two designs of femoral stems to better understand the role of femoral stem design on polyethylene impingement.

Methods This was a case-control study involving 70 retrieved highly cross-linked polyethylene (X3) liners used with ABGII ($n = 35$) and Rejuvenate ($n = 35$) stems (Stryker). All polyethylene liners were assessed for evidence of rim deformation and the damage quantified using metrology methods.

Results A total of 80% of polyethylene liners paired with ABGII necks had macroscopic evidence of neck impingement resulting in a raised lip whilst 23% of liners paired with Rejuvenate necks had evidence of a raised lip ($p < 0.0001$). The height of the raised rims of the DM cups paired with ABGII necks had a median (range) of 139 μm (72–255). The height of the raised rims of the DM cups paired with Rejuvenate necks had a median (range) of 52 μm (45–90) ($p < 0.0001$).

Conclusion Our new findings from retrieved dual mobility bearings showed that polyethylene liner rim deformation resulting from impingement with the femoral neck occurs in early in-human function, is circumferential in distribution, and is affected by the stem neck design. We recommend the use of highly polished and non-edged neck designs when used in conjunction with DM cups.

Keywords Total hip arthroplasty · Dual mobility cups · Retrievals · Polyethylene impingement · Intraoperative dislocation

Introduction

Joint instability continues to pose challenges to total hip arthroplasty. The incidence of dislocation is reported as 0.2% to 3% in the first year following the primary procedure, up to 7% after 25 years, and as high as 25% after revision arthroplasty [1, 2]. Dual mobility (DM) bearings have been

✉ Anna Di Laura
anna.laura.14@ucl.ac.uk

Harry S. Hothi
h.hothi@ucl.ac.uk

Johann Henckel
j.henckel@ucl.ac.uk

Arianna Cerquiglini
arianna.cerquiglini.15@ucl.ac.uk

Ming Han Lincoln Liow
MLIOW@mgh.harvard.edu

Young-Min Kwon
YMKWON@mgh.harvard.edu

John A. Skinner
john.skinner@ucl.ac.uk

Alister J. Hart
a.hart@ucl.ac.uk

¹ Institute of Orthopaedics and Musculoskeletal Science, University College London, London, UK

² The Royal National Orthopaedic Hospital, Brockley Hill, Stanmore, Middlesex HA7 4LP, UK

³ Massachusetts General Hospital/ Harvard Medical School, Boston, USA

extensively used in Europe as an alternative to constrained liners together with large heads to solve instability; they were only recently approved by the U.S. Food and Drug Administration for sale in the United States in 2009 and their use is expected to increase due to their promising results [3, 4].

DM cups have a large diameter femoral head, increasing the head-neck ratio and the 'jump distance' needed to dislocate the ball from the acetabulum [5] resulting in improved stability [6–8]. However, DM cups are vulnerable to impingement between the femoral neck and the polyethylene liner rim, the so-called third articulation, which can cause intraprosthetic dislocation (IPD) [6, 9], defined as the dissociation of the small-diameter head retained within the liner due to loss of the retentive power of the rim, leading to surgical treatment.

Clinical studies have shown that the design of the femoral neck influences the stability of DM cups [10–13] but the mechanism is not known. This study explores the hypothesis that femoral stems with necks designed with smooth surfaces have less polyethylene rim deformation than necks designed with rough surfaces. The objectives were to compare the polyethylene liners of two femoral stem designs for (1) visual assessment of damage and (2) quantification of deformation by means of metrology methods.

Materials and methods

This was a case-control study involving 70 retrieved DM cups received at our laboratory. The cups analysed were Restoration Anatomic Dual Mobility X3 liner (ADM) and Modular Dual Mobility X3 liner (MDM), (Stryker Orthopaedics, Mahwah, NJ). The ADM is a monoblock shell with a cobalt alloy bearing surface and a titanium plasma spray fixation surface that is coated with hydroxyapatite. The shape incorporates a psoas cutout to help provide relief between the acetabular shell rim and the iliopsoas tendon. The MDM design has a modular cobalt alloy liner engaging into a more standard acetabular component that has screw holes, to enhance cup fixation. Both constructs feature the same type of liner made of highly crosslinked polyethylene (X3). The ABGII femoral stems have two opposing scalloped regions on the neck, whilst the Rejuvenate design has a uniform curved geometry (Fig. 1).

The implants for the ABGII group were retrieved from 14 male and 21 female patients with a median age of 62 years (34–82) at primary surgery, whilst the Rejuvenate group consisted of 18 male and 17 female patients with a median age of 69 years (41–92). All patients were revised for symptoms related to corrosion due to neck-stem modularity, none of them for IPD; Table 1 summarises patient and implant demographic data for the two stem designs considered. Mann-Whitney tests confirmed that the two groups were

statistically matched with respect to: gender, age, time to revision, body mass index and head offset. The diameter of poly resulted significantly larger for the Rejuvenate group in comparison with the ABGII ($p < 0.0001$). Fifty-one of the retrievals had ceramic femoral heads, and 19 had cobalt-chromium alloy heads.

An a-priori sample size calculation was performed and revealed that 35 samples per group was sufficient to detect a difference (power, 80%). In order to describe the variability of the data in each group, an estimate of the standard deviation was required as there is currently no published or other material which provides this information. The study design of the present work is summarised in Fig. 2.

Visual assessment of polyethylene rim damage

Macroscopic and microscopic examinations of the polyethylene surfaces of all 70 liners were performed by two examiners (AD, AC) experienced in retrieval analysis, to score for visual evidence of surface degradation, in particular deformation (or creep). The examiners assessed the cups independently twice and were blind to stem type and patient characteristics. The rim edge on all retrieved mobile inserts were scored as either 1 (if evidence of contact from the femoral neck existed, resulting in a raised lip) or 0 (if no evidence of contact from the femoral neck existed, resulting in no raised lip) [14].


Femoral neck surface analysis The ABGII and Rejuvenate necks were analysed using a Contour GT-K 3D optical profilometer (Bruker, UK) to determine parameters of roughness: (1) the arithmetical mean height (S_a) defined as the difference in height of each point compared to the arithmetical mean of the surface, and (2) the maximum height of the profile (R_t). An objective lens of X0.55 was used to scan the surface with a backscan of 30 μm and length of 50 μm .

Measurement of rim deformation A Talyrond 365 (Taylor Hobson, Leicester, UK) machine was used to measure the peaks of deformation (raised lip) resulting from the contact with the neck. The femoral head was positioned on a spindle and a series of three equally spaced (at 120 degrees) vertical traces were taken axially along the poly surface with a 5- μm diamond stylus. The vertical traces from each taper surface were studied and the peaks of deformation recorded for each trace, in other words, the deviation from the flatness of the rim was used as a measure of deformation. The three traces were then averaged and divided by the time in situ for comparative purposes between the two groups.

MicroComputer tomography (CT) of the polyethylene rim

We selected one liner from each group which had the greatest macroscopic surface damage upon visual inspection. We quantified the deformation of the rim using computed tomography at 50- μm resolution using a micro-CT scanner (XTH

Fig. 1 Example of ABGII (a) and Rejuvenate (b) stems paired with an X3 liner showing the point where the neck impinges the polyethylene rim. The scallops on the ABGII implants, facing anteriorly and posteriorly with respect to the coronal plane of the stem, can be seen



225, Nikon Metrology NV). Scans included 3,177 views in 0.11° increments, with one frame per view and a frame exposure of 1000 ms. The X-ray tube voltage was set to 122 kV with a current of 72 mA. Scans were reconstructed at the full 50- μm isotropic resolution. The reconstructed scans of the liners were analysed with 3D micro-CT analysis software (Simpleware ScanIP, software version 7.0, Exeter, UK).

Statistical analysis Statistical analyses were performed using SPSS® Statistics Version 23 (IBM, Armonk, NY, USA). Cohen's weighted Kappa statistic (κ) was used to measure the strength of both the single-observer repeatability (for both examiners) and the inter-observer reproducibility of the deformation scores. Kappa values were assessed using the criteria described by Landis and Koch where $\kappa \leq 0$ = poor, 0.01 to 0.20 = slight, 0.21 to 0.40 = fair, 0.41 to 0.60 = moderate, 0.61 to 0.80 = substantial, and 0.81 to 1 = almost perfect [15]. Mann-Whitney U test was used to determine if there was a difference between the deformation scores, roughness parameter and quantification of rim deformation in the two groups. We also investigated associations between the severity of damage and clinical variables. The level of significance for all statistical analyses was $p < 0.05$.

Table 1 Implant and patient data showing median (range) values with p -values indicating the significance of differences between the parameters

Parameter	DM with ABGII	DM with Rejuvenate	p -value
Gender (male: female)	14: 21	18: 17	0.631
Age at primary surgery (years)	62 (34–82)	69 (41–92)	0.072
Time to revision (months)	29 (13–51)	30 (14–54)	0.580
Body mass index (kg/m^2)	26.3 (21–31)	29 (21.2–69)	0.130
Polyethylene diameter (mm)	44 (40–50)	48 (40–56)	<0.0001
Head offset (mm)	0 (–4;+4)	0 (–4;0)	0.408

DM dual mobility

Results

Polyethylene rim deformation was more common in the retrieved ABGII hips (80%) when compared to the Rejuvenate hips (23%) and was statistically significant ($p < 0.0001$). The degree of deformation was a median (range) of 139 μm (72–255) for the ABGII hips and 52 μm (45–90) ($p < 0.0001$) for the Rejuvenate hips.

Visual assessment of polyethylene damage

A total of 28 of the 35 (80%) DM liners paired with ABGII necks had macroscopic evidence of neck impingement resulting in a raised lip. Eight out of 35 (23%) liners paired with Rejuvenate necks had evidence of a raised lip; the difference between the two groups was statistically significant ($p < 0.0001$). Figure 3 presents the differences that were observed macroscopically between the two designs. When a raised lip was visible, it was generally along the entire circumference of the poly rim, suggesting no impediments to the movement of the liner such as fibrosis. The repeatability of both examiners was substantial ($\kappa = 0.78$; $\kappa = 0.70$). The inter-observer reproducibility of the deformation scores determined by the two examiners was also found to be substantial ($\kappa = 0.80$).

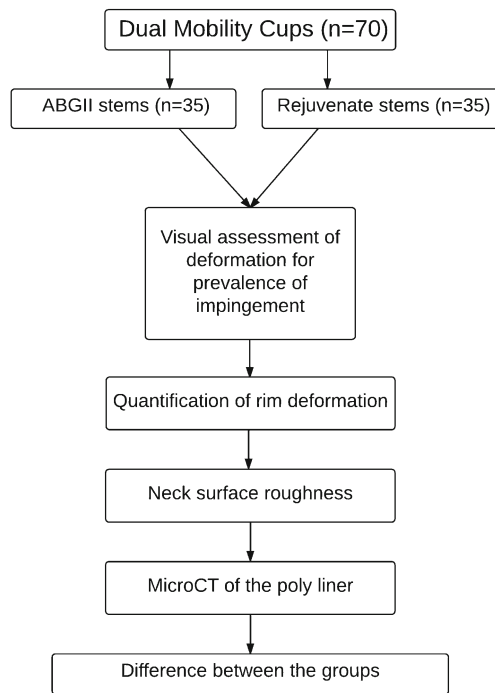


Fig. 2 Flow chart of the study design used in the present work


Femoral neck surface analysis

Figure 4 presents the surfaces of the ABGII and Rejuvenate necks as viewed under the optical microscope. The median (range) Sa value for the ABGII necks was $0.497 \mu\text{m}$ ($0.479\text{--}0.597$) whilst for Rejuvenate necks it was $0.073 \mu\text{m}$ ($0.05\text{--}0.116$); this difference was significant ($p = 0.0079$). The median (range) Rt value for the ABGII necks was $8.981 \mu\text{m}$ ($6.446\text{--}9.516$) whilst for Rejuvenate necks it was $3.796 \mu\text{m}$ ($1.183\text{--}4.297$), the difference was significant ($p = 0.0079$). The ABGII necks had a distinctly rougher surface topography than Rejuvenate necks.

Measurement of rim deformation

The height of the raised rims of the DM cups paired with ABGII necks had a median (range) of $139 \mu\text{m}$ ($72\text{--}255$), and the height of the raised rims of the DM cups paired with Rejuvenate necks had a median (range) of $52 \mu\text{m}$ ($45\text{--}90$).

Fig. 3 Digital optical photograph showing the deformation on the rim of the chamfer (arrows) resulting in a raised lip from the contact with an ABGII neck (a) and a rim paired with a Rejuvenate neck where the deformation did not leave a visible raised lip (b)



The three peaks of deformation per cup were averaged then normalised with respect to time in situ. The difference between the groups was found to be significant ($p < 0.0001$), and damage was found to be correlated with time of implantation in the ABGII group (Spearman $r = 0.98$, $p = 0.0056$).

MicroCT of the polyethylene rim

Cross sectional views of the two scanned liners confirmed the presence of a raised lip. The values of deviation from the flatness of the rim matched what measured with the Talyrond 365 (Fig. 5).

Discussion

We conducted the largest retrieval study of contemporary DM cups to better understand their function in humans. We aimed to assess the polyethylene liners of retrieved hips with one design of DM bearing and two designs of femoral stems to better understand the role of femoral stem design on polyethylene impingement. We found that 80% of polyethylene liners paired with ABGII necks had macroscopic evidence of neck impingement resulting in a raised lip compared to 23% for the liners paired with Rejuvenate necks. This was circumferential in distribution. The ABGII stems had necks with rougher surfaces and sharper, scalloped edges when compared to the Rejuvenate stems.

There was a statistically significant difference between the two groups investigated; however, the minimum clinically significant difference, or in other words, the amount of impingement that causes clinical symptoms, cannot be estimated from this study. It may be that the assessed damage accumulates over time culminating at a certain point in IPD, however this is not clear. It may also be that the loss of retentive power of the rim occurs for reasons not directly associated with rim deformation. This study does clearly demonstrate however, that visual and quantifiable damage of the polyethylene component occurs during early in-vivo function and accumulates over time.

The contact between the metal neck and the rim of the polyethylene insert constitutes the so-called third articulation.




Fig. 4 Image generated via the optical profilometer of the (a) rough ABGII neck and (b) smooth Rejuvenate neck

Clinical studies have highlighted that neck thickness and surface topography are important factors associated with poly wear of DM cups and play a role in the weakening of the retentive power of the poly liners ultimately leading to IPD of these bearing systems [7, 8, 16–19]. Data on small numbers of retrievals is available [10, 11, 14, 20], but there have been no attempts at quantifying the damage at the rim and at reporting when it is likely to occur in-vivo. In fact, as the majority of the studies addressing the issue of IPD report on gross deformation of the retentive rim only after dislocation, it is unknown whether it constitutes a gradual phenomenon that accumulates over time and finally results in the IPD episode or it is the result of an adverse event such as fibrosis or varus tilting of the liner culminating in the dislodgement of the head.

Beside neck diameter and topography, a number of implant-design features have been attributed to an increased risk of IPD. Concentrically arranged mobile liners that tend to tilt into a varus position, create the conditions to increase neck impingement usually localised on one side of the rim, resulting in an asymmetric degradation of it [21]. It is

recommended that the Morse taper is fully engaged into the femoral head in order to avoid rim fatigue as well as avoiding the use of skirted heads [21, 22]. Second-generation HXLPEs have also been suggested in conjunction with DM cups over first-generation HXLPEs, such as annealed, which is known to oxidise, and the melted type with reduced mechanical properties [23].

We focussed on the assessment of the polyethylene rim, or third articulation, because this is the site of a known clinical problem: impingement which can be severe enough to cause IPD. Clinical and retrieval studies so far have given an estimation of the incidence and association with implant and patient variables of the IPD but its aetiology is not fully understood. The present study was a matched case study involving 70 explants with two types of femoral components used with irradiated and annealed HXLPE (X3) liners and implanted at a mean of three years. The two neck types studied differed in terms of diameter; for a 0-mm head offset, the diameter of a Rejuvenate neck was found to be 2 mm larger than an ABGII neck at the point of contact

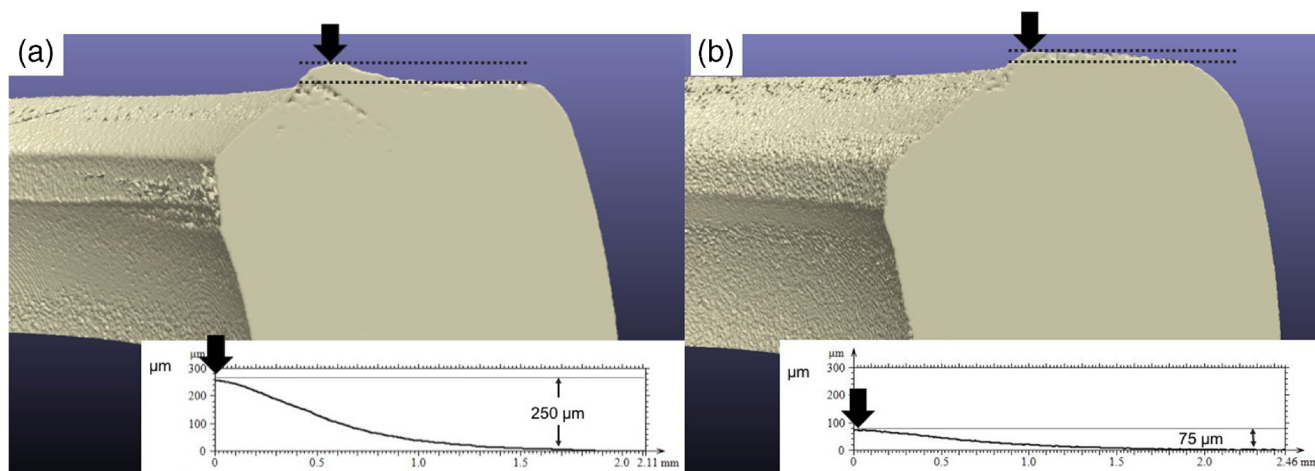


Fig. 5 Cross sectional cuts of the polyethylene cup associated with an ABGII neck (a) and a Rejuvenate neck (b). Agreement between the values of the raised lips computed with Simpleware software and the profiles obtained with the Talyrond 365 probe was found

with the liner. The caput-collum-diaphyseal or CCD angle of an ABGII stem varies between 125° and 135° and the Rejuvenate stem between 127° and 132°. In addition, the groups of explants examined belonged to groups of patients with comparable age, gender, time of implantation and body mass index. The main differences resided in the surface roughness of the necks; the presence of cuts or scallops in the ABGII group, and the size of the polyethylene liners. The ABGII group had a rougher surface which is known to increase the friction when the load is transmitted from the neck to the liner. The scallops present anteriorly and posteriorly in the ABGII necks may come into contact with the poly rim during specific activities (Fig. 1) and enhance the formation of a visible lip due to the smaller area of contact between neck and liner, thus a reduced area where the load is transmitted. Finally, the poly size was found to be greater in the ABGII group which may only partially account for increased damage due to the thinner rim diameters. Although the type of polyethylene analysed was irradiated and annealed and known to oxidise, the damage found appeared to be of mechanical nature thus not related to the oxidation.

A recent study has shown presence of rim deformation on 15 retrieved new-generation DM cups with highly cross-linked polyethylene liners [14]. Although stating that the retrieved cups were paired with recalled dual-taper prosthesis, the authors did not report the design. They found evidence of deformation in all the cups analysed (100%) and speculated that the presence of a raised lip is indicative of a mechanism inhibiting mobility of the liner, and motion could be impeded because of its impingement with the iliopsoas. In the present study, we saw a raised lip in 80% of liners mating ABGII necks, 23% in association with Rejuvenate stems and when a raised lip was present, it was generally all along the poly rim, suggesting no impediments to the movement of the liner. Loss of the retentive rim has been related to fibrosis [21, 24], but also seen without evidence of fibrosis [13, 22, 24], suggesting that other factors may be involved.

There is clinical evidence suggesting that the design of the stem plays a role in the performance of DM cups. Decreased occurrence of IPD has been reported when small-diameter and smooth necks were used [25–27] as opposed to rougher and larger femoral designs [8, 28, 29], but until now, the mechanism was unknown. Philippot et al. [24] found no difference in time of onset of IPD between two types of necks used in conjunction with DM cups, with one 3 mm larger and smoother than the other. They postulated that the rough surface (which increases the friction at the interface between polyethylene and metal neck) in one group compensated the effect of the thick neck (frequent impingement) in the other, resulting in no clinical difference. We were able to separate these two variables, and although

the necks of Rejuvenate designs exhibited a slightly larger diameter (+2 mm), the rougher ABGII design showed higher incidence of rim deformation suggesting that the topography could be the major influencing variable contributing to rim damage, evidenced by the fact that the severity of it was found to increase over time.

The use of DM cups is expected to increase due to their proven efficacy at reducing instability [3, 4, 30, 31]. Impingement between the neck and the liner indicates a wide range of motion. Comparison of retrievals with different neck types is key in providing new insights into the modes and mechanism of loss of retentive power of the polyethylene rim. Evidence of impingement in contemporary DM cups has only recently been reported [14] and elucidations regarding the mechanism are necessary to identify the implant-specific features that may increase the risk of long-term IP dislocation.

Conclusion

This was a case-control study involving 70 implants of a single dual mobility bearing design paired with two distinctly different stem types from the same manufacturer. We now better understand the function of dual mobility bearings in humans. First, we found evidence of circumferential impingement indicating that the polyethylene bearing rotates freely within the cup, which explains the stability with low wear rate of dual mobility bearings. Second, we found differences in the rate of impingement, depending on femoral stem design, with 80% and 23% with ABGII and Rejuvenate stems, respectively. The lower severity of impingement was found with a smooth neck stem design. We recommend the use of dual mobility bearings paired with stems that have a smooth neck.

Compliance with ethical standards

Conflict of interest The authors declare that they have no conflict of interest.

Funding There is no funding source.

Ethical approval The Riverside Research Ethics Committee approved the study (date of issue: 2007, IRAS REC number: 07/Q0401/25).

Informed consent Informed consent was obtained from all individual participants included in the study.

Open Access This article is distributed under the terms of the Creative Commons Attribution 4.0 International License (<http://creativecommons.org/licenses/by/4.0/>), which permits unrestricted use, distribution, and reproduction in any medium, provided you give appropriate credit to the original author(s) and the source, provide a link to the Creative Commons license, and indicate if changes were made.

References

- Woo RY, Morrey BF (1982) Dislocations after total hip arthroplasty. *J Bone Joint Surg Am* 64(9):1295–1306
- Berry DJ, von Knoch M, Schleck CD, Harmsen WS (2004) The cumulative long-term risk of dislocation after primary Charnley total hip arthroplasty. *J Bone Joint Surg Am* 86(1):9–14
- Epinette JA (2015) Clinical outcomes, survivorship and adverse events with mobile-bearings versus fixed-bearings in hip arthroplasty—A prospective comparative cohort study of 143 ADM versus 130 trident cups at 2 to 6-year follow-up. *J Arthroplast* 30(2):241–248
- Philippot R, Adam P, Farizon F, Fessy MH, Bousquet G (2006) Survival of cementless dual mobility sockets: Ten-year follow-up. *Revue de chirurgie orthopedique et reparatrice de l'appareil moteur* 92(4):326–331
- Morlock MM, Bishop N, Huber G (2011) Biomechanics of hip arthroplasty. In: *Tribology in Total Hip Arthroplasty*, Springer, Berlin, Heidelberg, pp 11–24
- Boyer B, Philippot R, Geringer J, Farizon F (2012) Primary total hip arthroplasty with dual mobility socket to prevent dislocation: A 22-year follow-up of 240 hips. *Int Orthop* 36(3):511–518
- Caton JH, Prudhon JL, Ferreira A, Aslanian T, Verdier R (2014) A comparative and retrospective study of three hundred and twenty primary Charnley type hip replacements with a minimum follow up of ten years to assess whether a dual mobility cup has a decreased dislocation risk. *Int Orthop* 38(6):1125–1129
- Prudhon JL, Ferreira A, Verdier R (2013) Dual mobility cup: dislocation rate and survivorship at ten years of follow-up. *Int Orthop* 37(12):2345–2350
- Usrey MM, Noble PC, Rudner LJ, Conditt MA, Birman MV, Santore RF, Mathis KB (2006) Does neck/liner impingement increase wear of ultrahigh-molecular-weight polyethylene liners? *J Arthroplast* 21(6):65–71
- Banzhof JA, Robbins CE, van der Ven A, Talmo CT, Bono JV (2013) Femoral head dislodgement complicating use of a dual mobility prosthesis for recurrent instability. *J Arthroplast* 28(3):543–5e1
- Schirmers J, Horazdovsky R, Marston S (2014) Early Intra-prosthetic dislocation of dual-mobility Total hip arthroplasty implant following attempted closed reduction: A case report. *Reconstruct Rev* 5(2)
- Ward JP, McCardell BR, Hallstrom BR (2013) Complete dissociation of the polyethylene component in a newly available dual-mobility bearing used in total hip arthroplasty. *JBJS Case Connect* 3(3):e94
- Odland AN, Sierra RJ (2014) Intra-prosthetic dislocation of a contemporary dual-mobility design used during conversion THA. *Orthopedics* 37(12):e1124–e1128
- Nebergall AK, Freiberg AA, Greene ME, Malchau H, Muratoglu O, Rowell S, Zumbunn T, Varadarajan KM (2015) Analysis of dual mobility liner rim damage using retrieved components and cadaver models. *J Arthroplast* 31(7):1595–1602
- Landis JR, Koch GG (1977) The measurement of observer agreement for categorical data. *Biometrics* 33(1):159–174
- Saragaglia D, Ruatti S, Refaie R (2013) Relevance of a press-fit dual mobility cup to deal with recurrent dislocation of conventional total hip arthroplasty: A 29-case series. *Europ J Orthopaed Surg Traumatol* 23(4):431–436
- Vielpeau C, Lebel B, Ardouin L, Burdin G, Lautridou C (2011) The dual mobility socket concept: experience with 668 cases. *Int Orthop* 35(2):225–230
- Guyen O, Pibarot V, Vaz G, Chevillotte C, Béjui-Hugues J (2009) Use of a dual mobility socket to manage total hip arthroplasty instability. *Clin Orthop Relat Res* 467(2):465–472
- Fabry C, Langlois J, Hamadouche M, Bader R (2016) Intra-prosthetic dislocation of dual-mobility cups after total hip arthroplasty: Potential causes from a clinical and biomechanical perspective. *Int Orthop* 40(5):901–906
- Banka TR, Ast MP, Parks ML (2014) Early intra-prosthetic dislocation in a revision dual-mobility hip prosthesis. *Orthopedics* 37(4):e395–e397
- Fabry C, Kaehler M, Herrmann S, Woernle C, Bader R (2014) Dynamic behavior of tripolar hip endoprostheses under physiological conditions and their effect on stability. *Med Eng Phys* 36(1):65–71
- Hamadouche M, Arnould H, Bouxin B (2012) Is a cementless dual mobility socket in primary THA a reasonable option? *Clin Orthop Relat Res* 470(11):3048–3053
- Engh CA, Stepniewski AS, Ginn SD, Beykirch SE, Sychterz-Terefenko CJ, Hopper RH, Engh CA (2006) A randomized prospective evaluation of outcomes after total hip arthroplasty using cross-linked Marathon and non-cross-linked Enduron polyethylene liners. *J Arthroplast* 21(6):17–25
- Philippot R, Boyer B, Farizon F (2013) Intra-prosthetic dislocation: A specific complication of the dual-mobility system. *Clin Orthop Relat Res* 471(3):965–970
- Massin P, Orain V, Philippot R, Farizon F, Fessy MH (2012) Fixation failures of dual mobility cups: A mid-term study of 2601 hip replacements. *Clin Orthop Relat Res* 470(7):1932–1940
- Lautridou C, Lebel B, Burdin G, Vielpeau C (2008) Survival of the cementless Bousquet dual mobility cup: minimum 15-year follow-up of 437 total hip arthroplasties. *Rev Chir Orthop Reparatrice Appar Mot* 94(8):731–739
- Vielpeau C, Lebel B, Ardouin L, Burdin G, Lautridou C (2011) The dual mobility socket concept: Experience with 668 cases. *Int Orthop* 35(2):225–230
- Philippot R, Farizon F, Camilleri JP, Boyer B, Derhi G, Bonnan J, Lecuire F (2008) Survival of dual mobility socket with a mean 17 years follow-up. *Revue de chirurgie orthopedique et reparatrice de l'appareil moteur* 94(1):43–48
- Philippot R, Camilleri JP, Boyer B, Adam P, Farizon F (2009) The use of a dual-articulation acetabular cup system to prevent dislocation after primary total hip arthroplasty: Analysis of 384 cases at a mean follow-up of 15 years. *Int Orthop* 33(4):927–932
- Langlais FL, Ropars M, Gaucher F, Musset T, Chaix O (2008) Dual mobility cemented cups have low dislocation rates in THA revisions. *Clin Orthop Relat Res* 466(2):389–395
- Leiber-Wackenheim F, Brunschweiler B, Ehlinger M, Gabrion A, Mertl P (2011) Treatment of recurrent THR dislocation using of a cementless dual-mobility cup: A 59 cases series with a mean 8 years' follow-up. *Orthop Traumatol: Surg Res* 97(1):8–13