

## **Primary vs. Staged closure of exomphalos major – cardiac anomalies do not affect outcome.**

CM Rees<sup>1</sup>, LGC Tullie<sup>1</sup>, A Pierro<sup>1</sup>, EM Kiely<sup>1</sup>, JI Curry<sup>1</sup>, KMK Cross<sup>1</sup>, RW Yates<sup>2</sup>, S Eaton<sup>3</sup>, P De Coppi<sup>1,3</sup>

<sup>1</sup>Department of Paediatric Surgery, Great Ormond Street Hospital, London, WC1N 3JH

<sup>2</sup>Department of Paediatric Cardiology, Great Ormond Street Hospital, London, WC1N 3JH

<sup>3</sup> Stem Cells and Regenerative Medicine Section, DBC, Institute of Child Health, University College London, 30 Guilford Street, London WC1N 1EH

### **INTRODUCTION:**

Exomphalos is an anterior abdominal wall defect affecting 1 in 5000 neonates[1]. Up to 74% have other congenital anomalies including heart defects, chromosomal anomalies (especially Trisomy 13 and 18), Beckwith Wiedemann syndrome, and rarely midline syndromes (such as Pentalogy of Cantrell, OEIS (omphalocele, exstrophy, imperforate anus and spinal) syndrome and lower midline syndrome)[2-4].

If the abdominal wall defect is  $\geq 5$ cm or contains liver, it is defined as exomphalos major; an important clinical distinction, as surgical management differs from exomphalos minor, which can usually be closed primarily. In exomphalos major there is significant abdomino-visceral disproportion which may make reduction of sac contents into the abdomen challenging or impossible. Traditionally management has been non-operative, leaving the sac to epithelialise to enable later surgical closure. Current surgical options include primary closure, (with or without a patch) and staged silo repair, which involves suturing a prosthetic silo to the defect edge, with or without sac excision. The silo is serially reduced over weeks, in theatre or at bedside. When the abdominal viscera are reduced, the silo is removed and abdominal wall closed. Some authors advocate an aggressive surgical approach[5], but this institution has published a series managed with staged repair between 1997 and 2004[6] who had good outcomes. We sought to update this series and investigate whether congenital heart disease impacts on the surgical and other outcomes. Moreover, while some patient characteristics clearly influence outcome, such as respiratory failure at birth which is

a significant predictor of mortality[7], it remains unclear whether infants with significant cardiac anomalies have worse outcomes.

## **METHODS:**

A retrospective review of infants with exomphalos major (defined as an abdominal wall defect of  $\geq 5$ cm diameter with or without liver herniation) treated at Great Ormond Street Hospital was performed. Infants were included who presented from December 2004 to December 2014 inclusive (from the end of the previous study [6]). Infants were excluded if they had primary treatment elsewhere. The study was approved as an audit.

Demographic data and details of comorbidities were obtained from notes and information about cardiac anomalies from echocardiogram reports. Cardiac anomalies were considered major if the patient required cardiac surgery or long term cardiology follow-up. The protocol for management was to offer primary closure if possible, and staged silo repair (as previously, leaving the sac intact[6]) if abdomino-visceral disproportion did not allow primary closure. Patients with severe comorbidities preventing surgical intervention were managed conservatively and excluded from further analysis. Details of operative closure were obtained and outcomes compared between infants who had primary closure and staged repair with a silo and between those with and without significant cardiac anomalies.

As exomphalos is associated with abnormal intestinal rotation, infants were investigated and offered Ladd's procedure if necessary. Laparoscopic Ladd's procedure is the institutional preference as it allows assessment of the rotational anomaly and the small bowel mesentery, with correction if necessary but reduced risk of adhesional bowel obstruction[8-10].

Data are presented as median [range] and compared with two tailed Mann Whitney-U test, t test and Fishers exact test as appropriate using GraphPad Prism v5 (GraphPad Software, Inc., 2007).

## **RESULTS:**

### **Demographics and Patient Characteristics:**

Twenty two patients presented with exomphalos major. Liver was herniated in 20 and one had Pentalogy of Cantrell. Gestational age was 38 [30-40] weeks, birth weight 2.7 [1.4-4.6] kg; 13 (60%) were male. Eighteen patients (82%) were delivered by caesarean section, 12 electively and 6 as an emergency.

Cardiac anomalies were present in 20 (91%) infants, 8 had minor and 12 had major anomalies, some infants had more than one anomaly. Minor anomalies included small PDA (patent ductus arteriosus, (PDA; 6), patent foramen ovale (PFO, 2) and small inter-atrial connection (2), none of which required surgical intervention or long-term follow-up. Major defects included PDA requiring intervention (7), ASD (atrial septal defect, 5), VSD (ventricular septal defect, 4), PFO requiring intervention (2), aortic arch abnormalities (3), DORV (double outlet right ventricle, 2), coarctation (1), tetralogy of Fallot (1), dilated left ventricle (1), right ventricular hypoplasia (1) and mitral valve anomaly (1). Twelve (55%) had other significant anomalies, including pulmonary hypoplasia with pulmonary hypertension (3) and congenital diaphragmatic hernia (2).

Twelve (55%) had other anomalies, including pulmonary hypoplasia with pulmonary hypertension (3), congenital diaphragmatic hernia (1 Bochdalek, 1 Morgagni), undescended testes (3), renal abnormalities (1 duplex kidney, 1 pelvic kidney), talipes equinovarus (1) and hypothyroidism (1). Two infants had a chromosomal anomaly, x-linked ichthyosis (1) and Beckwith Wiedemann syndrome (1). Eight infants had inguinal herniae (5 bilateral and 3 unilateral).

### **Management:**

Two (9%) patients were managed conservatively due to overwhelming comorbidities, one had a left congenital diaphragmatic hernia and died on day two of life, the other had

pulmonary hypoplasia and pulmonary hypertension, the sac was painted with betadine and saline and epithelialized. The patient died of respiratory distress syndrome precipitated by adenovirus infection 6 months later.

All other infants (20/22; 81%) were managed surgically. Five (23%) infants underwent primary closure at 2 [1-7] days, the defect was 6cm [5-7cm] and all had liver herniation. In 4, full fascial closure was performed and in 1 only skin closure was possible. Four of these patients had major cardiac anomalies. [Figure 1]

A staged approach was used in 15 (68%) infants – 7 with major cardiac anomalies and 8 without, with silo application on day 1 [0-8]. Infants had a 6 [3-10] procedures to tuck the silo before definitive closure. 40% of tucks were at the bedside without anaesthetic (30/75). Age at definitive closure was 37 [9-112] days; 13 (87%) achieved full fascial closure, 2 were closed with a patch (Gore-tex® or permacol™). One patch became infected, requiring removal. One infant required silo refashioning 2 days after formation. Nine days later the sac ruptured; tissue expanders were used to increase the abdominal domain, but were replaced because of infection. Ultimately the abdominal wall was closed with a Strattice™ patch and plastic surgical reconstruction. One infant had an ileal perforation (presumed necrotizing enterocolitis) while the silo was in place and underwent laparotomy with oversewing of the perforation at day 28. Another two had exploration of bowel in the silo at day 5 and 9 due to suspected perforation. One infant had abdominal closure at day 20 but required silo refashioning at 30 days, the abdomen was subsequently closed at 70 days.

The position of the duodeno-jejunal flexure was assessed in all infants, either at primary repair (5) or by contrast study after abdominal wall closure (15). Six infants (30%) had malrotation, none were symptomatic. Five had laparoscopic Ladd's procedure at 5.5 [2.2-32] months, and one was assessed operatively, the mesentery was broad based, so Ladd's procedure was unnecessary.

Eleven (73%) patients in the staged closure group developed ventral herniae, compared to 1 (20%) in the primary repair group ( $p=1$ ).

### **Primary outcomes:**

Infants who survived were followed up for 38 [2-71] months and no infants were lost to follow-up. Five (23%) patients died at 7 [0-17] months, including the two managed conservatively (described above), none primarily of the exomphalos. One infant in the primary closure group with coarctation of the aorta died at 27 days of sepsis and renal failure. Two who had delayed closure died from pulmonary hypertension with chronic lung disease (1 in the cardiac anomaly group, 1 not). Figure 1 shows outcome for all patients.

Primary closure infants had fewer episodes of sepsis (1[0-1] vs. 2[1-4],  $p=0.009$ ) but in staged infants there was no difference between those with and without cardiac anomalies (2[1-4] vs. 2[1-3],  $p=1$ ).

As expected, infants in the primary closure group had a shorter time to full closure (2 [1-7] vs. 37 [9-112] days,  $p<0.05$ ) and a shorter hospital stay (13 [6-21] vs. 85 [19-159] days,  $p<0.05$ ) but other outcomes were not different [Table 1, Figure 2].

### **Effect of cardiac anomalies:**

To examine the effect of major cardiac anomalies on outcome, we grouped the 20 surgically managed patients into those with major cardiac anomalies ( $n=11$ ) and those with either a minor anomaly or no cardiac defect ( $n=9$ ). There was no significant difference in gestation (38 [30-40] vs. 37 [35-38] weeks),  $p=0.1$ ) or birth weight (2.7 [1.4-2.3] vs. 2.8 [2.3-4.6] kg,  $p=0.5$ ) between infants with major cardiac anomalies and those without. Infants with cardiac anomalies had a shorter time to defect closure (13 [1-60] vs. 57 [1-112] days,  $p=0.01$ ) but no significant difference in hospital stay (35 [6-139] vs. 84 [14-159] days,  $p=0.3$ ), [Table 2, Figure 2].

Staged closure patients with cardiac anomalies were closed earlier than those without at 28 [9-60] compared to 62 [17-112] days,  $p=0.03$ , [Table 2, Figure 2].

Patients with major cardiac anomalies had fewer procedures to achieve full closure (4 [1-9] vs. 9 [1-10],  $p=0.04$ ) but if the primary closure group are excluded this apparent difference is not significant (5 [4-9] vs. 9 [3-10],  $p=0.09$ ).

There were no differences in ventilation duration, intensive care days, or time to full feeds between those with and without cardiac anomalies [Table 2], whether or not they had staged closure. There was also no difference in mortality between the two groups (2/11 with cardiac anomalies vs. 1/9 without,  $p=1$ ).

### **Discussion:**

Our results indicate that infants who underwent primary closure had a shorter time to closure and length of stay than those who had staged closure, as might be expected. However, there was no difference in duration of ventilation, intensive care stay or time to full enteral feeds. Obviously the decision of whether to opt for primary versus staged closure depends on factors including size of defect and stability of the patient, and is made at the time of the first surgery. We had hypothesised that infants with major cardiac anomalies would have worse outcomes than those without, but found this was not the case. Furthermore infants with major cardiac anomalies achieved abdominal wall closure earlier than those without. Major cardiac anomaly did not preclude primary closure, and was not associated with increased mortality. This is a retrospective review and the finding of shorter time to full closure may reflect a bias and is unlikely to be of clinical significance. We think that the importance of these data is not that cardiac infants are closed more quickly, but that they do not require a longer time for closure.

Management of exomphalos major continues to present a problem, with no consensus on optimal treatment and each method having challenges[11]. The paucity of good quality evidence is partly due to low incidence, with the majority of publications documenting case reports or small case series. Outcomes have improved in recent years regardless of technique, presumably as neonatal intensive care has improved.

The definitive goal is to achieve both skin and fascial coverage of abdominal contents. Current approaches include surgery in the neonatal period or later. Initial non-operative management with sac epithelialisation and application of topical agents is favoured by many[12-16]. This may prevent respiratory complications and increased abdominal compartment pressure. However, it has disadvantages, including morbidity due to infection and wound complications, systemic absorption and toxicity of agents applied to the sac, and the requirement for later operative intervention[12-15,17].

Many prefer neonatal repair[18]. Advocates of primary surgical closure highlight the benefits of reduced ventilation duration, shorter time to enteral feeds and reduced hospital stay when compared with staged closure [5]. However, the defect size, degree of viscerο-abdominal disproportion and presence of associated anomalies, as in this study, may preclude reduction of abdominal viscera and immediate closure.

A variety of methods of staged closure have been reported since Gross first described advancing skin flaps to cover the defect[19]. Staged silo reduction, as described in this, and other large series[5,6], is one such method, a modification of the technique described by Schuster[20]. Our practise is that patients with a silo remain in hospital. Closing with a silo allows earlier closure and aims for a fascial closure rather than a potentially more challenging procedure in childhood to close a large ventral hernia. Centres that opt for conservative management and later closure still usually keep the child in hospital until the sac has epithelialized which may also result in a prolonged hospital stay.

This study is the first to assess if significant cardiac anomalies affect outcome in staged



management of exomphalos major and is one of the largest series reviewing neonatal primary and staged closure.

Our findings differ from those of a 2005 paper which demonstrated shorter duration of ventilation, intensive care stay and time to enteral feeds in primary closure compared with staged closure[5]. The observed differences in gestation and weight between the two groups in that study, unlike ours, may explain this difference. Interestingly, in our study, earlier gestation did not preclude primary closure. Ours is a centre for management of congenital cardiac anomalies, which may explain the higher incidence of significant cardiac anomalies (86%) than rates of 30-50% documented in the literature[5,21]. This may also have contributed to the similar outcomes we observed in the primary and staged closure groups; with a lower threshold for staged closure rather than pursuing a more aggressive strategy of primary closure.

Infants with concomitant congenital anomalies, including cardiac, provide additional challenges when considering management of exomphalos major. Complications of staged reduction, such as respiratory insufficiency, haemodynamic compromise, prosthesis infection and inability to close the abdomen, lead many to adopt a more conservative approach. Furthermore, the severity of some anomalies may preclude neonatal operative intervention, as we found in two patients. Respiratory insufficiency at birth, in particular, has been shown to be an independent predictor of mortality in infants with giant exomphalos[7]. A study observed pulmonary hypertension in over a third of patients, associated with increased duration of ventilation and length of stay, but no difference between staged and delayed closure[22]. Another large series described infants managed with the Gross technique, either neonatally or after a conservative management, and found that major anomalies (including cardiac) had a greater effect on outcome than the surgical technique used, with a much higher mortality than found in our cohort (41% with major anomalies). This technique was however, associated with lower incidence of ventral hernia than our staged silo technique [23].

Staged reduction has been reported in several series including a study demonstrating comparable survival outcomes to series documenting delayed closure[24]. However, due to the diverse nature of the anomalies, it is impossible to extrapolate any guidance as to which techniques should be applied to which populations.

Interestingly this cohort of patients had more associated anomalies, including cardiac anomalies than the previous series reported from our centre, only 16% of whom had significant cardiac anomalies[6]. It is not clear whether this represents a change in referral patterns or obstetric practice, as studies of antenatally diagnosed exomphalos in recent years demonstrate a high termination rate [25,26]. One limitation of this study is that it was retrospective in nature and therefore some data, for instance accurate measurement of defect size, was inconsistently recorded.

Our results demonstrate that patients with exomphalos major continue to present a challenge to paediatric surgeons and may have prolonged hospital stays if the defect cannot be closed primarily. Infants with significant cardiac anomalies can be managed with primary or staged closure, but do no worse than infants without major anomalies. These findings could be related to the early cardiologist involvement, but have the limitation related to any retrospective study. Prospective, studies such as the British Association of Paediatric Surgeons Congenital Anomalies Surveillance System (BAPS-CASS) national study, are necessary (<https://www.npeu.ox.ac.uk/baps-cass/surveillance/exo>). Nevertheless we believe this message is relevant for antenatal counselling, as parents can be informed that the cardiac anomaly does not affect the prognosis of the exomphalos, and does not need to dictate the surgical management.

**FIGURE LEGENDS:**

**Figure 1 Treatment and outcome of all patients**

**Figure 2 Time to full closure of exomphalos**

**TABLE LEGENDS:**

**Table 1 Primary Outcomes comparing Primary vs. Staged Closure**

**Table 2 Outcomes in Infants with Cardiac vs. No Cardiac anomalies**

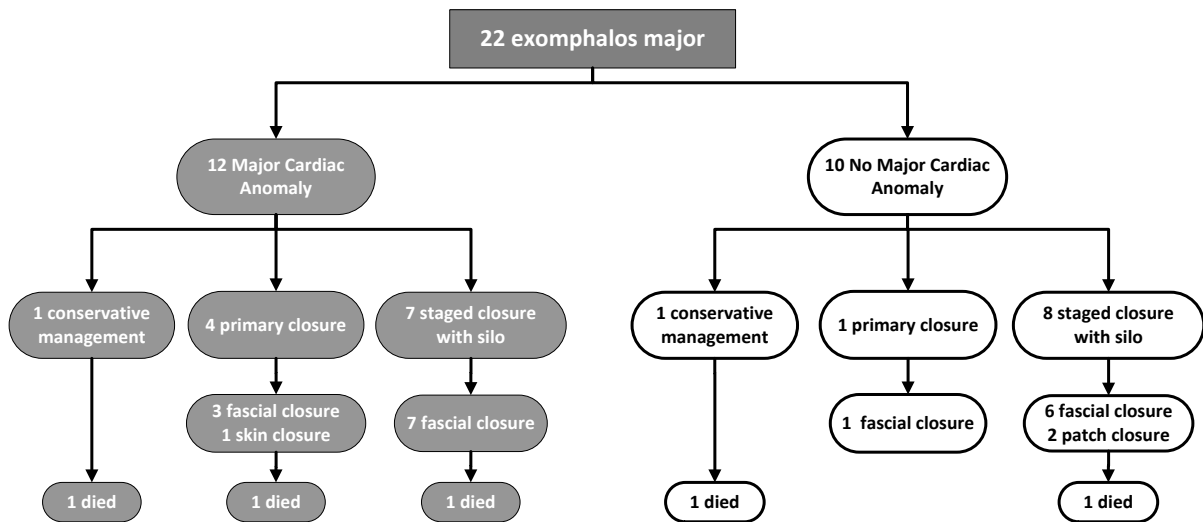
## REFERENCES

1. Springett A, Draper ES, Rankin J et al. Birth prevalence and survival of exomphalos in England and Wales: 2005 to 2011. *Birth Defects Research Part A: Clinical and Molecular Teratology* 2014; 100: 721-725
2. Christison-Lagay ER, Kelleher CM, Langer JC. Neonatal abdominal wall defects. *Seminars in fetal & neonatal medicine* 2011; 16: 164-172
3. Gilbert WM, Nicolaides KH. Fetal omphalocele: associated malformations and chromosomal defects. *Obstetrics and gynecology* 1987; 70: 633-635
4. Yazbeck S, Ndoye M, Khan AH. Omphalocele: a 25-year experience. *Journal of pediatric surgery* 1986; 21: 761-763
5. Rijhwani A, Davenport M, Dawrant M et al. Definitive surgical management of antenatally diagnosed exomphalos. *Journal of pediatric surgery* 2005; 40: 516-522
6. Pacilli M, Spitz L, Kiely EM et al. Staged repair of giant omphalocele in the neonatal period. *Journal of pediatric surgery* 2005; 40: 785-788
7. Tsakayannis DE, Zurakowski D, Lillehei CW. Respiratory insufficiency at birth: A predictor of mortality for infants with omphalocele. *Journal of Pediatric Surgery* 1996; 31: 1088-1091
8. Ooms N, Matthyssens LEM, Draaisma JM et al. Laparoscopic Treatment of Intestinal Malrotation in Children. *European journal of pediatric surgery : official journal of Austrian Association of Pediatric Surgery [et al] = Zeitschrift fur Kinderchirurgie* 2015, DOI: 10.1055/s-0035-1554914:
9. Draus JM, Jr., Foley DS, Bond SJ. Laparoscopic Ladd procedure: a minimally invasive approach to malrotation without midgut volvulus. *The American surgeon* 2007; 73: 693-696
10. Graziano K, Islam S, Dasgupta R et al. Asymptomatic malrotation: Diagnosis and surgical management: An American Pediatric Surgical Association outcomes and evidence based practice committee systematic review. *Journal of Pediatric Surgery* 2015; 50: 1783-1790
11. van Eijck FC, Aronson DA, Hoogeveen YL et al. Past and current surgical treatment of giant omphalocele: outcome of a questionnaire sent to authors. *Journal of pediatric surgery* 2011; 46: 482-488
12. Ein SH, Langer JC. Delayed management of giant omphalocele using silver sulfadiazine cream: An 18-year experience. *Journal of Pediatric Surgery* 2012; 47: 494-500
13. Lee SL, Beyer TD, Kim SS et al. Initial nonoperative management and delayed closure for treatment of giant omphaloceles. *Journal of pediatric surgery* 2006; 41: 1846-1849
14. Whitehouse JS, Gourlay DM, Masonbrink AR et al. Conservative management of giant omphalocele with topical povidone-iodine and its effect on thyroid function. *Journal of Pediatric Surgery* 2010; 45: 1192-1197
15. Pereira RM, Tatsuo ES, Simões e Silva AC et al. New method of surgical delayed closure of giant omphaloceles: Lazaro da Silva's technique. *Journal of Pediatric Surgery* 2004; 39: 1111-1115

16. Charlesworth P, Ervine E, McCullagh M. Exomphalos major: the Northern Ireland experience. *Pediatric Surgery International* 2009; 25: 77-81
17. Jackson HJ, Sutherland RM. Effect of povidone-iodine on neonatal thyroid function. *The Lancet* 1981; 318: 992-992
18. Kothari M, Pease PWB. Closure of the ventral hernia in the management of giant exomphalos: A word of caution. *Pediatric Surgery International* 2005; 21: 106-109
19. Gross RE. A new method for surgical treatment of large omphaloceles. *Surgery* 1948; 24: 277-292
20. Schuster SR. A new method for the staged repair of large omphaloceles. *Surgery, gynecology & obstetrics* 1967; 125: 837-850
21. Kumar HR, Jester AL, Ladd AP. Impact of omphalocele size on associated conditions. *Journal of pediatric surgery* 2008; 43: 2216-2219
22. Partridge EA, Hanna BD, Panitch HB et al. Pulmonary hypertension in giant omphalocele infants. *Journal of Pediatric Surgery* 2015; 49: 1767-1770
23. Akinkuotu AC, Sheikh F, Olutoye OO et al. Giant omphaloceles: surgical management and perinatal outcomes. *J Surg Res* 2015; 198: 388-392
24. Mitanchez D, Walter-Nicolet E, Humblot A et al. Neonatal care in patients with giant omphalocele: arduous management but favorable outcomes. *Journal of Pediatric Surgery* 2015; 45: 1727-1733
25. Khalil A, Arnaoutoglou C, Pacilli M et al. Outcome of fetal exomphalos diagnosed at 11–14 weeks of gestation. *Ultrasound in Obstetrics & Gynecology* 2012; 39: 401-406
26. Lakasing L, Cicero S, Davenport M et al. Current outcome of antenatally diagnosed exomphalos: an 11 year review. *Journal of pediatric surgery* 2006; 41: 1403-1406

**TABLES/FIGURES:**

**Figure 1 Treatment and outcome of all patients**



**Table 1 Primary Outcomes comparing Primary vs. Staged Closure**

	<b>Primary Closure</b>	<b>Staged Closure</b>	
N (%)	5 (23%)	15 (28%)	
Gestational age (weeks)	37 [30-39]	38 [35-40]	<i>p=0.03</i>
Birth weight (kg)	2.8 [1.4-4.5]	2.7 [2.3-4.6]	<i>NS</i>
Mortality	1 (20%)	2 (13%)	<i>NS</i>
Number of procedures to close defect	1	6 [3-10]	<i>p&lt;0.0001</i>
Time to closure (days)	2 [1-7]	37 [9-112]	<i>p=0.007</i>
Time ventilated (days)	3 [1-25]	13 [1-48]	<i>NS</i>
Intensive care (days)	6 [4-25]	13 [3-139]	<i>NS</i>
Age at full feeds (days)	25 [6-44]	40 [13-141]	<i>NS</i>
Length of stay (days)	13 [6-21]	85 [19-159]	<i>p=0.02</i>

**Table 2 Outcomes in Infants with Cardiac vs. No Cardiac anomalies**

	<b>Major cardiac anomaly</b>	<b>No major cardiac anomaly</b>	
N (%)	11(55%)	9(45%)	
Gestational age (weeks)	38 [30-40]	37 [35-38]	<i>NS</i>
Birth weight (kg)	2.7 [1.4-4.3]	2.8 [2.3-4.6]	<i>NS</i>
Mortality	2 (18%)	1 (11%)	<i>NS</i>
Number of procedures to close defect	4 [1-9]	9 [1-10]	<i>p=0.04</i>
Time to closure (days)	13 [1-60]	57 [1-112]	<i>p=0.01</i>
Time to closure (days) in staged patients	28 [9-60]	62 [17-112]	<i>p=0.03</i>
Time ventilated (days)	9 [1-48]	11 [1-21]	<i>NS</i>
Intensive care (days)	9 [5-139]	19 [3-37]	<i>NS</i>
Age at full feeds (days)	32 [13-140]	53 [6-141]	<i>NS</i>
Length of stay (days)	35 [6-139]	84 [14-159]	<i>NS</i>



Figure 2 Time to full closure of exomphalos

