



University
of Glasgow

Puetz, V., Khomenko, A., Hill, M.D., Dzialowski, I., Michel, P., Weimar, C., Wijman, C.A.C., Mattle, H.P., Engelter, S.T., Muir, K.W. , Pfefferkorn, T., Tanne, D., Szabo, K., Kappelle, L.J., Algra, A., von Kummer, R., Demchuk, A.M., and Schonewille, W.J. (2011) *Extent of hypoattenuation on CT angiography source images in Basilar Artery occlusion: prognostic value in the Basilar Artery International Cooperation Study*. Stroke, 42 (12). pp. 3454-3459. ISSN 0039-2499

<http://eprints.gla.ac.uk/59009/>

Deposited on: 17 January 2012



Extent of Hypoattenuation on CT Angiography Source Images in Basilar Artery Occlusion : Prognostic Value in the Basilar Artery International Cooperation Study

Volker Puetz, Andrei Khomenko, Michael D. Hill, Imanuel Dzialowski, Patrik Michel, Christian Weimar, Christine A.C. Wijman, Heinrich P. Mattle, Stefan T. Engelter, Keith W. Muir, Thomas Pfefferkorn, David Tanne, Kristina Szabo, L. Jaap Kappelle, Ale Algra, Ruediger von Kummer, Andrew M. Demchuk and Wouter J. Schonewille

Stroke 2011, 42:3454-3459: originally published online September 29, 2011
doi: 10.1161/STROKEAHA.111.622175

Stroke is published by the American Heart Association, 7272 Greenville Avenue, Dallas, TX 75214
Copyright © 2011 American Heart Association. All rights reserved. Print ISSN: 0039-2499. Online
ISSN: 1524-4628

The online version of this article, along with updated information and services, is located on the World Wide Web at:
<http://stroke.ahajournals.org/content/42/12/3454>

Subscriptions: Information about subscribing to Stroke is online at
<http://stroke.ahajournals.org/subscriptions/>

Permissions: Permissions & Rights Desk, Lippincott Williams & Wilkins, a division of Wolters Kluwer Health, 351 West Camden Street, Baltimore, MD 21202-2436. Phone: 410-528-4050. Fax: 410-528-8550. E-mail:
journalpermissions@lww.com

Reprints: Information about reprints can be found online at
<http://www.lww.com/reprints>

Extent of Hypoattenuation on CT Angiography Source Images in Basilar Artery Occlusion

Prognostic Value in the Basilar Artery International Cooperation Study

Volker Puetz, MD; Andrei Khomenko, MD; Michael D. Hill, MD; Imanuel Dzialowski, MD; Patrik Michel, MD; Christian Weimar, MD; Christine A.C. Wijman, MD; Heinrich P. Mattle, MD; Stefan T. Engelter, MD; Keith W. Muir, MD; Thomas Pfefferkorn, MD; David Tanne, MD; Kristina Szabo, MD; L. Jaap Kappelle, MD; Ale Algra, MD; Ruediger von Kummer, MD; Andrew M. Demchuk, MD; Wouter J. Schonewille, MD; on behalf of the Basilar Artery International Cooperation Study (BASICS) Group

Background and Purpose—The posterior circulation Acute Stroke Prognosis Early CT Score (pc-ASPECTS) quantifies the extent of early ischemic changes in the posterior circulation with a 10-point grading system. We hypothesized that pc-ASPECTS applied to CT angiography source images predicts functional outcome of patients in the Basilar Artery International Cooperation Study (BASICS).

Methods—BASICS was a prospective, observational registry of consecutive patients with acute symptomatic basilar artery occlusion. Functional outcome was assessed at 1 month. We applied pc-ASPECTS to CT angiography source images of patients with CT angiography for confirmation of basilar artery occlusion. We calculated unadjusted and adjusted risk ratios (RRs) of pc-ASPECTS dichotomized at ≥ 8 versus < 8 . Primary outcome measure was favorable outcome (modified Rankin Scale scores 0–3). Secondary outcome measures were mortality and functional independence (modified Rankin Scale scores 0–2).

Results—Of 158 patients included, 78 patients had a CT angiography source images pc-ASPECTS ≥ 8 . Patients with a pc-ASPECTS ≥ 8 more often had a favorable outcome than patients with a pc-ASPECTS < 8 (crude RR, 1.7; 95% CI, 0.98–3.0). After adjustment for age, baseline National Institutes of Health Stroke Scale score, and thrombolysis, pc-ASPECTS ≥ 8 was not related to favorable outcome (RR, 1.3; 95% CI, 0.8–2.2), but it was related to reduced mortality (RR, 0.7; 95% CI, 0.5–0.98) and functional independence (RR, 2.0; 95% CI, 1.1–3.8). In post hoc analysis, pc-ASPECTS dichotomized at ≥ 6 versus < 6 predicted a favorable outcome (adjusted RR, 3.1; 95% CI, 1.2–7.5).

Conclusions—pc-ASPECTS on CT angiography source images independently predicted death and functional independence at 1 month in the CT angiography subgroup of patients in the BASICS registry. (*Stroke*. 2011;42:3454-3459.)

Key Words: acute ■ basilar artery ■ CT angiography ■ prognosis ■ stroke

Despite recent advances in the treatment of patients with acute ischemic stroke, the rate of death or disability associated with basilar artery occlusion (BAO) remains high.¹ If treated conventionally, nearly 80% of patients die or survive with severe disability.² Because of this poor prognosis, treating physicians are tempted to use the most aggressive treatment approach available. Intravenous (IV) thrombolysis, IV

thrombolysis followed by intra-arterial (IA) therapy, or IA therapy alone are the most frequently used recanalization strategies. However, predicting a treatment benefit from such therapies is difficult. Up to 75% of patients with BAO have a poor functional outcome despite the use of recanalization therapies.^{1,3}

In patients with an acute ischemic stroke in the anterior circulation, the extent of early ischemic changes on pretreat-

Received April 1, 2011; final revision received April 28, 2011; accepted May 16, 2011.

Jeffrey L. Saver, MD was the Guest Editor for this paper.

From St Antonius Hospital Nieuwegein (W.J.S., E.v.d.H.), Nieuwegein, The Netherlands; the Utrecht Stroke Center (L.J.K., A.A.), Utrecht, The Netherlands; the Julius Center for Health Sciences and Primary Care (A.A.), Utrecht, The Netherlands; the University of Bern (H.P.M., M.A.), Bern, Switzerland; University Hospital Basel (S.T.E., S.W.), Basel, Switzerland; Centre Hospitalier Universitaire Vaudois Lausanne (P.M.), Lausanne, Switzerland; Dresden University Stroke Center (V.P., A.K., I.D., R.v.K.), Dresden, Germany; the University of Duisburg-Essen (C.W.), Essen, Germany; the University of Leipzig (D.M.), Leipzig, Germany; Medizinische Hochschule Hannover (K.W.), Hannover, Germany; University Clinics Freiburg (C.H.), Freiburg, Germany; the University of Munich, Klinikum Grosshadern (T.P.), Munich, Germany; Universitätsklinikum Mannheim (K.S., C.G.), Mannheim, Germany; Stanford University (C.A.C.W.), Stanford, CA; Calgary Stroke Program (M.D.H., A.M.D.), University of Calgary, Calgary, Alberta, Canada; the Department of Clinical Neurosciences (A.M.D., M.D.H.), Hotchkiss Brain Institute, University of Calgary, Calgary, Alberta, Canada; the University of Glasgow (K.M., N.M.), Glasgow, UK; and Sheba Medical Center and Tel Aviv University (D.T., D.O.), Tel Aviv, Israel.

Correspondence to Volker Puetz, MD, University of Technology Dresden, Dresden University Stroke Center, Department of Neurology, Fetscherstr. 74, 01307 Dresden, Germany. E-mail volker.puetz@neuro.med.tu-dresden.de

© 2011 American Heart Association, Inc.

Stroke is available at <http://stroke.ahajournals.org>

DOI: 10.1161/STROKEAHA.111.622175

ment noncontrast CT or diffusion-weighted MRI predicts functional outcome and treatment response to IV and IA thrombolysis.^{4–7} Compared with noncontrast CT, CT angiography (CTA) source images (CTA-SI) are more accurate in predicting the final extent of infarction and clinical outcome.^{8–11} Recent studies have suggested that the extent of hypoattenuation on CTA-SI, quantified with the posterior circulation Acute Stroke Prognosis Early CT Score (pc-ASPECTS) or the Pons–midbrain-index, predicts functional outcome of patients with BAO.^{12,13} Patients with extensive CTA-SI hypoattenuation (pc-ASPECTS <8 or Pons–midbrain-index ≥ 3) were unlikely to achieve a favorable outcome despite IA thrombolysis or recanalization of the basilar artery, respectively.

The Basilar Artery International Cooperative Study (BASICS) was a prospective international observational registry of consecutive patients with radiologically confirmed acute symptomatic BAO.¹ We hypothesized that the extent of hypoattenuation on CTA-SI predicts functional outcome of patients in the BASICS registry.

Methods

Patients

The BASICS registry opened in November 2002 and closed in October 2007. Patients were eligible if they presented with symptoms or signs attributable to posterior circulation ischemia and had BAO confirmed by CTA, MR angiography, or conventional digital subtraction angiography. Treatments were allocated at the discretion of the treating physician. Details of the registry protocol have been described previously.^{1,14}

Inclusion criterion for the present study was confirmation of BAO by CTA. To ensure CTA experience, we limited participation to BASICS centers who used CTA in ≥ 10 patients in the registry. Patients who had been treated with IV thrombolysis in peripheral hospitals in a “drip and ship” approach were included if they had persistent BAO on CTA on arrival at the BASICS center.¹⁵ We excluded patients in whom CTA images were not available electronically, were of inadequate technical quality, or if additional imaging findings (eg, tumor, hemorrhage) with influence on functional outcome were present.

For the BASICS registry, detailed data were recorded with a web-based data entry form that included information on baseline characteristics, stroke risk factors, estimated time of BAO, prodromal minor stroke, location of occlusion, type and timing of treatment, neurological deficits at the time of treatment as assessed with the National Institutes of Health Stroke Scale (NIHSS) score, and functional outcome at 1 month as assessed with the modified Rankin Scale (mRS) score.¹

The BASICS protocol was approved by the ethics committee of the University Medical Center Utrecht, Utrecht, The Netherlands. The requirement for additional local ethical approval differed between participating countries and was obtained if required. Verbal or written informed consent was obtained from the patient or patient’s representative as required by national and local guidelines.

Image Collection

We requested all available CTA images of patients who fulfilled the inclusion criteria from the BASICS sites. Digital Imaging and Communications in Medicine format images were transferred to Dresden University Stroke Center for central interpretation. CTAs were performed according to the local protocols of the participating BASICS sites.

Image Analysis

We reviewed axial Digital Imaging and Communications in Medicine format CTA images with 0.8-mm to 6.0-mm slice thickness on a high-resolution monitor. We adjusted window and level individually to allow maximum contrast differentiation on CTA-SI. Regions of relatively diminished contrast enhancement were scored as abnormal. Images were analyzed in a 3-readers consensus setting by stroke neurologists experienced in the interpretation of CTA-SI in acute ischemic stroke (A.M.D., I.D., V.P.).^{12,16} Readers were blinded to clinical information. We graded hypoattenuating areas in posterior circulation territories with the pc-ASPECTS score and the Pons–midbrain-index as described before (Figure 1).^{12,13}

pc-ASPECTS allots the posterior circulation 10 points. One point each is subtracted for hypoattenuation on CTA-SI in the left or right thalamus, cerebellum, or posterior cerebral artery territory, respectively, and 2 points each are subtracted for hypoattenuation on CTA-SI in any part of the midbrain or pons. A pc-ASPECTS of 10 indicates absence of visible posterior circulation ischemia, and a score of 0 indicates hypoattenuation in all pc-ASPECTS territories.

For the Pons–midbrain-index, CTA-SIs were analyzed for hypoattenuation bilaterally in the pons and midbrain. Each side was graded as: 0, no hypoattenuation; 1, $\leq 50\%$ hypoattenuation; or 2, $>50\%$ hypoattenuation. A Pons–midbrain-index of 0 indicates absence of CTA-SI hypoattenuation in the midbrain and pons, and a score of 8 indicates $>50\%$ hypoattenuation bilaterally in these brain stem territories.

Outcome Measures

The primary outcome measure was favorable outcome, defined as an mRS score of 0 to 3, at 1 month. Secondary outcome measures were functional independence (mRS score of 0–2) and death.

Hypothesis

Our primary hypothesis was that the CTA-SI pc-ASPECTS score, dichotomized at ≥ 8 versus < 8 , predicted primary and secondary outcome measures of patients in the BASICS registry.¹² As a secondary hypothesis we assessed whether the Pons–midbrain-index dichotomized at < 3 versus ≥ 3 predicted these outcome measures.¹³

Statistical Analysis

Data are reported using standard descriptive statistics. We calculated unadjusted and adjusted risk ratios (RRs) of the imaging variables (pc-ASPECTS and Pons–midbrain-index) for primary and secondary outcome measures. Adjusted models were initially derived to account for age, gender, baseline NIHSS score, prodromal minor stroke, diabetes mellitus, onset-to-CTA time, location of occlusion, and thrombolytic treatment as reported in the primary analysis of the BASICS registry.¹ However, due to the smaller numbers of outcomes in this subset of the BASICS cohort, we could adjust for a maximum of 3 variables simultaneously only. The variables that had the strongest influence on crude RR in univariable adjustment were selected for adjustment.

For the analysis, we combined the IV, IA and IV–IA treatment groups to a thrombolysis group and used thrombolysis as a binary variable. We considered main effects only. Because we were specifically interested in the role that imaging played in predicting outcome, imaging variables (pc-ASPECTS or Pons–midbrain-index) were considered forced variables in these models. We used a generalized linear modeling approach with log link to directly derive RRs.

To assess differences in the relation between pc-ASPECTS and outcome between patients who received thrombolysis and those who did not, we did an interaction test using a Wald test within a multivariable model. In some cases, we were missing potential predictor variables (eg, NIHSS score) for a small number of patients ($n=11$). Where this occurred, we imputed the median NIHSS score for these patients to allow us to derive adjusted models for the entire data set.

Results

Patients

Of 619 patients who were registered in the BASICS registry, 27 patients were excluded from the analysis because they did

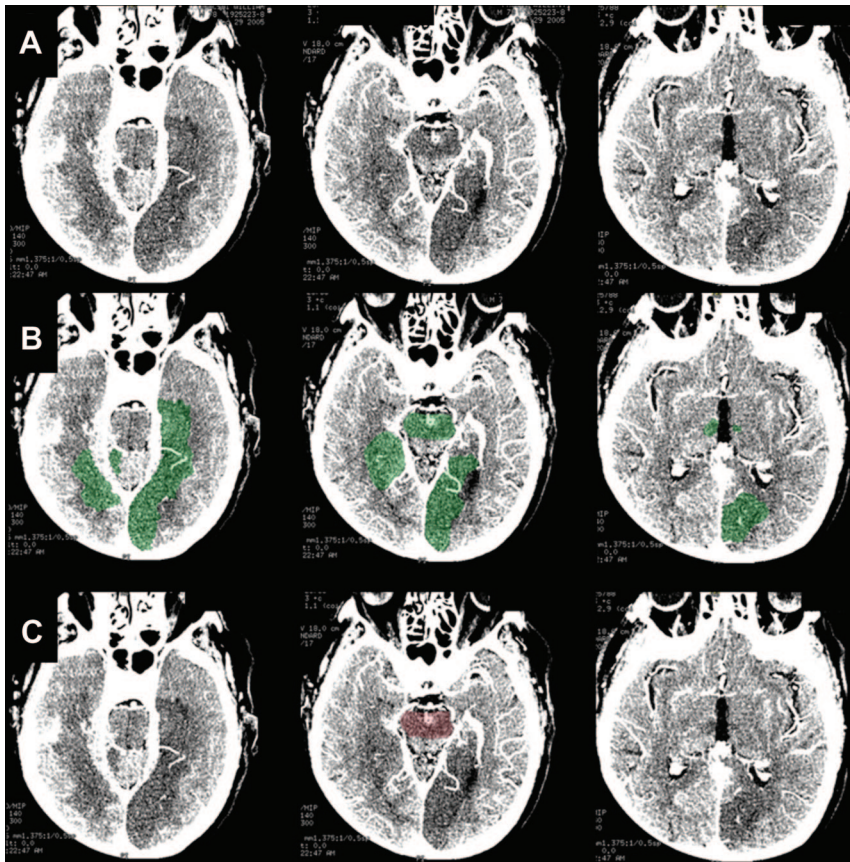


Figure 1. Example of a patient from the BASICS registry. CT angiography source images (A) demonstrate hypoattenuation in the posterior circulation. For pc-ASPECTS (B), hypoattenuation (marked green) in both posterior cerebral artery territories (1 point each), the right cerebellum (1 point), both thalami (1 point each), and the midbrain (2 points) resulted in a pc-ASPECTS score of 3. For the Pons-midbrain-index (C), >50% hypoattenuation (marked red) bilaterally in the midbrain (2 points each) resulted in a Pons-midbrain-index of 4. (Note that pc-ASPECTS ranges from 0 to 10 in which 10 is best and the Pons-midbrain-index ranges from 0 to 8 in which 0 is best.) BASICS indicates Basilar Artery International Cooperation Study; pc-ASPECTS, posterior circulation Acute Stroke Prognosis Early CT Score.

not receive any antithrombotic or thrombolytic therapy. Of the remaining 592 patients who were analyzed in the BASICS registry, 259 patients were registered by centers with ≥ 10 patients in the registry and had CTA confirmation of BAO (Figure 2). Of these, Digital Imaging and Communications in Medicine format CTA images were available from 161 patients. Three further patients were excluded because CTA images did not cover sufficient brain structures to determine pc-ASPECTS (n=2) or showed subdural hematoma (n=1).

The final analysis included 158 patients from 12 BASICS centers. The mean age was 65 ± 15 years, 64% were men, and

the median baseline NIHSS score was 25 (interquartile range, 24). CTAs were performed after a median time of 234 minutes (interquartile range, 349) since the estimated time of BAO. Overall, 62 patients (39%) were treated with anti-thrombotic therapies, 15 patients (9%) with IV thrombolysis, 53 patients (34%) with chemical or mechanical IA thrombolysis, and 28 patients (18%) with combined IV-IA treatment regimens. Three patients had been treated with IV thrombolysis before confirmation of BAO.

At 1 month, 40 patients (25%) had a favorable outcome (mRS scores 0–3), 49 patients (31%) survived with an unfavorable outcome (mRS scores 4–5), and 69 patients (44%) had died. The overall median pc-ASPECTS on CTA-SI was 7 (interquartile range, 4) and the median Pons-midbrain-index on CTA-SI was 2 (interquartile range, 4).

Association of Imaging Findings With Functional Outcome

Primary Hypothesis: pc-ASPECTS Dichotomized at ≥ 8 Versus < 8

Seventy-eight patients had a CTA-SI pc-ASPECTS ≥ 8 . Baseline clinical data according to categorized CTA-SI pc-ASPECTS groups are summarized in Table 1. Compared with patients with a CTA-SI pc-ASPECTS ≥ 8 , patients with a score < 8 were less likely to receive IV or IA thrombolysis.

Compared with patients with a CTA-SI pc-ASPECTS < 8 , patients with a CTA-SI pc-ASPECTS ≥ 8 tended to have more often a favorable outcome (RR, 1.7; 95% CI, 0.98–3.0), were more likely to be functionally independent (RR, 2.1;

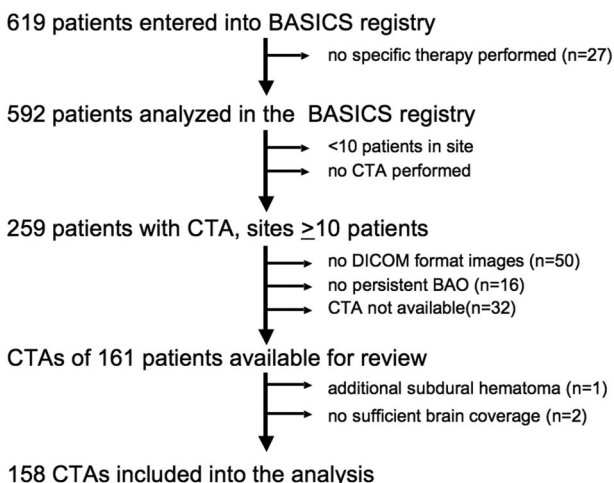


Figure 2. Patient selection. Inclusion and exclusion criteria are specified in the text. CTA indicates CT angiography.

Table 1. Baseline Characteristics According to Categorized CTA-SI pc-ASPECTS Groups

Parameter	pc-ASPECTS	
	8–10	0–7
No., no.	78	80
Age, y, median (IQR)	66.5 (20)	64.5 (21)
Male sex, n (%)	49 (63)	52 (65)
Baseline NIHSS score, median (IQR)	25 (18)	26.5 (16)
Onset-to-CTA time (min), median (IQR)	232 (314)	234 (432)
Prodromal minor stroke, no. (%)	13 (17)	12 (15)
Treatment category, no. (%)		
Antithrombotics	23 (29)	39 (49)
IV thrombolysis	9 (12)	6 (8)
IA therapy	31 (40)	22 (28)
IV–IA	15 (19)	13 (16)
Any thrombolysis, no. (%)	55 (71)	41 (51)
Time to thrombolysis (min), median (IQR)	290 (240)	300 (360)
Vascular risk factors, no. (%)		
Diabetes mellitus	16 (21%)	15 (19%)
Arterial hypertension	49 (63%)	47 (59%)
Atrial fibrillation	17 (22%)	11 (14%)
Coronary artery disease	11 (14%)	11 (14%)
Current smoking	19 (24%)	12 (15%)
Hypercholesterolemia	22 (28%)	21 (26%)
Peripheral vascular disease	8 (10%)	2 (3%)

CTA-SI indicates CT angiography source image; pc-ASPECTS, posterior circulation Acute Stroke Prognosis Early CT Score; IQR, interquartile range; NIHSS, National Institutes of Health Stroke Scale; CTA, CT angiography; IV, intravenous; IA, intra-arterial.

95% CI, 0.98–4.3), and less likely to die (RR, 0.6; 95% CI, 0.4–0.9; Table 2; Figure 3). After adjustment for age, baseline NIHSS score, and thrombolysis, pc-ASPECTS ≥8 was not related to favorable outcome (RR, 1.3; 95% CI, 0.8–2.2), but it was related to functional independence (RR, 2.0; 95% CI, 1.1–3.8) and reduced risk of death (RR, 0.7;

Table 2. Relation of pc-ASPECTS on CTA-SI (≥8 Versus <8) With Functional Outcome

Outcome	pc-ASPECTS		Risk Ratio (95% CI)	
	8–10	0–7	Unadjusted	Adjusted*
No., no.	78	80
Primary outcome measure				
mRS ≤3, % (no.)	32 (25)	19 (15)	1.7 (0.98–3.0)	1.3 (0.8–2.2)
Secondary outcome measures				
mRS ≤2, % (no.)	23 (18)	11 (9)	2.1 (0.98–4.3)	2 (1.1–3.8)
Death, % (no.)	32 (25)	55 (44)	0.6 (0.4–0.9)	0.7 (0.5–0.98)

pc-ASPECTS indicates posterior circulation Acute Stroke Prognosis Early CT Score; CTA-SI, CT angiography source image; mRS, modified Rankin Scale; CI, confidence interval.

*Models were adjusted for baseline National Institutes of Health Stroke Scale score, age, and thrombolytic therapy.

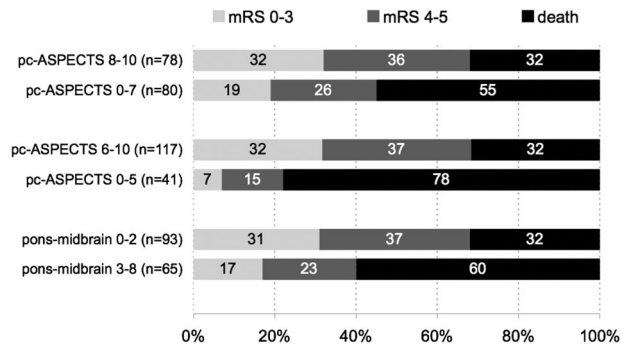


Figure 3. Distribution of functional outcomes according to dichotomized pc-ASPECTS and Pons-midbrain-index, respectively. pc-ASPECTS indicates posterior circulation Acute Stroke Prognosis Early CT Score; mRS, modified Rankin Scale.

95% CI, 0.5–0.98; Table 2). The relationship of pc-ASPECTS (≥8 and <8) and the primary and secondary outcome measures was not different between patients who did or did not receive thrombolysis (*P* interaction >0.05, Wald test).

Secondary Hypothesis: Pons-Midbrain-Index Dichotomized at <3 Versus ≥3

The Pons-midbrain-index, dichotomized at <3 versus ≥3, was associated with a favorable outcome (RR, 1.8; 95% CI, 0.99–3.4; Table 3), functional independence (RR, 2.0; 95% CI, 0.9–4.4), and a reduced risk of death (RR, 0.5; 95% CI, 0.3–0.8; Figure 3). After adjustment for age, baseline NIHSS score, and thrombolysis, the magnitude of the effect was slightly attenuated for death (RR, 0.6; 95% CI, 0.4–0.8) and not statistically significant for favorable outcome (RR, 1.5; 95% CI, 0.8–2.6) or functional independence (RR, 1.7; 95% CI, 0.9–3.4).

Post Hoc Analysis: pc-ASPECTS Dichotomized at ≥6 Versus <6

A review of the distribution of the mRS scores according to the CTA-SI pc-ASPECTS scores in the present study suggested that pc-ASPECTS values in 2 categories (≥6 and <6) best discriminated a favorable outcome from an unfavorable outcome and death. We performed a post hoc analysis to assess whether the CTA-SI pc-ASPECTS score dichotomized at ≥6 versus <6 predicted favorable outcome.

Thirty-seven of 117 patients (32%) with a CTA-SI pc-ASPECTS ≥6 compared with 3 of 41 patients (7%) with a CTA-SI pc-ASPECTS <6 had a favorable outcome (RR, 4.3; 95% CI, 1.4–13.3; Table 3; Figure 3). After adjustment for age, baseline NIHSS score, and thrombolysis, pc-ASPECTS dichotomized at ≥6 versus <6 was an independent predictor of favorable outcome (RR, 3.1; 95% CI, 1.2–7.5).

Discussion

Our study demonstrates that pc-ASPECTS on CTA-SI, dichotomized at ≥8 versus <8, predicts functional independence (mRS scores 0–2) and death at 1 month in the CTA subgroup of the BASICS registry population. Furthermore, pc-ASPECTS dichotomized at ≥6 versus <6 was an independent predictor of favorable outcome (mRS scores 0–3) in this population.

Table 3. Relation of Pons-Midbrain-Index (<3 Versus \geq 3) and pc-ASPECTS (\geq 6 Versus <6) on CTA-SI With a Favorable Outcome

Outcome	Pons-Midbrain-Index		Risk Ratio (95% CI)		pc-ASPECTS		Risk Ratio (95% CI)	
	0–2	3–8	Unadjusted	Adjusted*	6–10	0–5	Unadjusted	Adjusted*
No., no.	93	65	117	41
mRS \leq 3, % (no.)	31 (29)	17 (11)	1.8 (0.99–3.4)	1.5 (0.8–2.6)	32 (37)	7 (3)	4.3 (1.4–13.3)	3.1 (1.2–7.5)

pc-ASPECTS indicates posterior circulation Acute Stroke Prognosis Early CT Score; CTA-SI, CT angiography source image; mRS, modified Rankin Scale; CI, confidence interval.

*Models were adjusted for baseline National Institutes of Health Stroke Scale score, age, and thrombolytic therapy.

In BASICS, nearly 70% of patients had a poor functional outcome despite the initiation of IV or IA recanalization therapies.¹ The present study confirms that the extent of hypoattenuation on CTA-SI is independently related to the functional outcome of patients with BAO. Whereas dichotomization of the pc-ASPECTS score at \geq 8 versus <8 predicted a favorable outcome (mRS scores 0–3) in the pc-ASPECTS study, dichotomization at lower pc-ASPECTS scores (\geq 6 versus <6) predicted favorable outcome in the present study.¹² Potential explanations for the lower pc-ASPECTS threshold in the BASICS registry are the absence of time window exclusion criteria and the inclusion of patients with prodromal minor stroke.

MRI with diffusion-weighted imaging sequences is the diagnostic “gold standard” in patients with posterior circulation stroke.¹⁷ A recent study has confirmed the prognostic value of pc-ASPECTS if applied to diffusion-weighted imaging of patients with posterior circulation stroke.¹⁸ However, the feasibility of MRI acquisition is limited in these frequently unstable patients.^{19,20} We have recently demonstrated that CTA-SIs increase the sensitivity for early ischemic changes in the posterior circulation compared with noncontrast CT.^{12,16} Compared with CTA-SI, perfusion CT techniques may provide additional diagnostic and prognostic information in patients with acute posterior circulation stroke.^{21,22} The comparison of CTA, perfusion CT, and multimodal MRI to predict functional outcome and treatment response in patients with BAO could be the subject of future studies.

We have applied 2 semiquantitative scores to assess the extent of CTA-SI hypoattenuation: the pc-ASPECTS score and the Pons-midbrain-index.^{12,13} Both scores were related with functional outcome in our study. Although both scores emphasize ischemic changes in the brain stem, pc-ASPECTS assesses ischemic changes in additional posterior circulation territories with prognostic relevance. Future studies should assess whether 1 score provides superior prognostic information in a subgroup of patients with BAO.

The optimal treatment regimen for patients with BAO is unknown. A recent meta-analysis has demonstrated that IA compared with IV thrombolysis is not associated with improved functional outcome in patients with BAO.³ In line with these results, the BASICS registry did not identify an overall treatment benefit of IA therapies compared with IV thrombolysis or antithrombotic treatment regimens.¹ We could not demonstrate a pc-ASPECTS by thrombolysis interaction in our study. Our data therefore do not support withholding thrombolytic therapies in patients with basilar

artery occlusion and extensive CTA-SI hypoattenuation. However, this analysis has low power due to small numbers. Therefore, failure to show a statistical interaction effect could be due to a Type 2 error. The BASICS trial will randomize patients with BAO to IV thrombolysis or a combined IV–IA treatment approach. We plan to test for a pc-ASPECTS by treatment–category interaction as a prespecified imaging substudy in the BASICS trial. The demonstration of such an interaction may have implications for the clinical management of patients with BAO.

We were not able to collect all CTAs of patients in the BASICS registry. Our results may therefore be influenced by selection bias. Because BASICS had no time window exclusion criteria, we may have misinterpreted subacute ischemic changes as early ischemic changes in our study. Because follow-up images were not available, we cannot comment on the accuracy of CTA-SI to predict infarction in the present study. Patients in the BASICS registry were not treated under a treatment protocol and different treatment regimens may have influenced the importance of imaging findings on functional outcomes in our study. Because the functional status of patients with BAO may still improve after 1 month, the assessment of functional outcomes after a longer rehabilitation period may have caused different results. Moreover, this imaging substudy was not prospectively designed as part of the BASICS registry. However, images were prospectively and blindly analyzed with prespecified imaging criteria and prespecified imaging hypotheses based on the results of published literature.^{12,13}

In summary, our study confirms the prognostic relevance of early ischemic changes on CTA-SI in patients with acute symptomatic BAO. Patients with BAO and extensive hypoattenuation on CTA-SI were unlikely to achieve a favorable functional outcome. A potential pc-ASPECTS-by-treatment–category interaction will be prospectively analyzed as an imaging substudy in the BASICS trial.

Acknowledgments

Participants of the study: The Netherlands: St Antonius Hospital Nieuwegein—Wouter J. Schonewille and Erik van der Hoeven; Utrecht Stroke Center—L. Jaap Kappelle, Ale Algra (also affiliated with the Julius Center for Health Sciences and Primary Care, Utrecht); Switzerland: University of Bern—Heinrich P. Mattle and Marcel Arnold; University Hospital Basel—Stefan T. Engelter and Stephan Wetzel; Centre Hospitalier Universitaire Vaudois Lausanne—Patrik Michel; Germany: Dresden University Stroke Center—Volker Puetz, Andrei Khomenko, Imanuel Dzialowski, and Ruediger von Kummer; University of Duisburg-Essen—Christian Weimar; University of Leipzig—Dominik Michalski; Medizinische Hochschule Hannover—Karin Weissenborn; University Clinics Freiburg—Christian Haverkamp; University of Munich, Klinikum Grosshad-

em—Thomas Pfefferkorn; Universitätsklinikum Mannheim—Krisztina Szabo and Christoph Groden; US: Stanford University—Christine A.C. Wijman; Canada: Calgary Stroke Program, University of Calgary—Michael D. Hill and Andrew M. Demchuk (also affiliated with the Department of Clinical Neurosciences, Hotchkiss Brain Institute, University of Calgary); UK: University of Glasgow—Keith Muir and Niall MacDougall; Israel: Sheba Medical Center and Tel Aviv University—David Tanne and David Orion.

Sources of Funding

The development of the BASICS database was supported by the Department of Neurology, University Medical Center Utrecht, Utrecht, The Netherlands. The image collection and transfer was funded by an allowance grant from the Medical Faculty, University of Technology Dresden, Dresden, Germany.

Disclosures

None.

References

- Schonewille WJ, Wijman CA, Michel P, Rueckert CM, Weimar C, Mattle HP, et al. Treatment and outcomes of acute basilar artery occlusion in the Basilar Artery International Cooperation Study (BASICS): a prospective registry study. *Lancet Neurol*. 2009;8:724–730.
- Schonewille WJ, Algra A, Serena J, Molina CA, Kappelle LJ. Outcome in patients with basilar artery occlusion treated conventionally. *J Neurol Neurosurg Psychiatry*. 2005;76:1238–1241.
- Lindsberg PJ, Mattle HP. Therapy of basilar artery occlusion: a systematic analysis comparing intra-arterial and intravenous thrombolysis. *Stroke*. 2006;37:922–928.
- Demchuk AM, Hill MD, Barber PA, Silver B, Patel SC, Levine SR. Importance of early ischemic computed tomography changes using ASPECTS in NINDS rtPA stroke study. *Stroke*. 2005;36:2110–2115.
- Hill MD, Demchuk AM, Tomsick TA, Palesch YY, Broderick JP. Using the baseline CT scan to select acute stroke patients for IV–IA therapy. *AJNR Am J Neuroradiol*. 2006;27:1612–1616.
- Hill MD, Rowley HA, Adler F, Eliasziw M, Furlan A, Higashida RT, et al. Selection of acute ischemic stroke patients for intra-arterial thrombolysis with pro-urokinase by using ASPECTS. *Stroke*. 2003;34:1925–1931.
- Parsons MW, Christensen S, McElduff P, Levi CR, Butcher KS, De Silva DA, et al. Pretreatment diffusion- and perfusion-MR lesion volumes have a crucial influence on clinical response to stroke thrombolysis. *J Cereb Blood Flow Metab*. 2010;30:1214–1225.
- Camargo EC, Furie KL, Singhal AB, Roccatagliata L, Cunnane ME, Halpern EF, et al. Acute brain infarct: detection and delineation with CT angiographic source images versus nonenhanced CT scans. *Radiology*. 2007;244:541–548.
- Coutts SB, Lev MH, Eliasziw M, Roccatagliata L, Hill MD, Schwamm LH, et al. ASPECTS on CTA source images versus unenhanced CT: added value in predicting final infarct extent and clinical outcome. *Stroke*. 2004;35:2472–2476.
- Lev MH, Segal AZ, Farkas J, Hossain ST, Putman C, Hunter GJ, et al. Utility of perfusion-weighted CT imaging in acute middle cerebral artery stroke treated with intra-arterial thrombolysis: prediction of final infarct volume and clinical outcome. *Stroke*. 2001;32:2021–2028.
- Schramm P, Schellinger PD, Klotz E, Kallenberg K, Fiebich JB, Kulkens S, et al. Comparison of perfusion computed tomography and computed tomography angiography source images with perfusion-weighted imaging and diffusion-weighted imaging in patients with acute stroke of less than 6 hours' duration. *Stroke*. 2004;35:1652–1658.
- Puetz V, Sylaja PN, Coutts SB, Hill MD, Dzialowski I, Mueller P, et al. Extent of hypoattenuation on CT angiography source images predicts functional outcome in patients with basilar artery occlusion. *Stroke*. 2008;39:2485–2490.
- Schaefer PW, Yoo AJ, Bell D, Barak ER, Romero JM, Nogueira RG, et al. CT angiography-source image hypoattenuation predicts clinical outcome in posterior circulation strokes treated with intra-arterial therapy. *Stroke*. 2008;39:3107–3109.
- Schonewille WJ, Wijman CAC, Michal P, Algra A, Kappelle LK. The Basilar Artery International Cooperation Study (BASICS). *Int J Stroke*. 2007;2:220–223.
- Pfefferkorn T, Holtmannspotter M, Schmidt C, Bender A, Pfister HW, Straube A, et al. Drip, ship, and retrieve: cooperative recanalization therapy in acute basilar artery occlusion. *Stroke*. 2010;41:722–726.
- Puetz V, Sylaja PN, Hill MD, Coutts SB, Dzialowski I, Becker U, et al. CT angiography source images predict final infarct extent in patients with basilar artery occlusion. *AJNR Am J Neuroradiol*. 2009;30:1877–1883.
- Muir KW, Buchan A, von Kummer R, Rother J, Baron JC. Imaging of acute stroke. *Lancet Neurol*. 2006;5:755–768.
- Tei H, Uchiyama S, Usui T, Ohara K. Posterior circulation ASPECTS on diffusion-weighted MRI can be a powerful marker for predicting functional outcome. *J Neurol*. 2010;257:767–773.
- Hand PJ, Wardlaw JM, Rowat AM, Haisma JA, Lindley RI, Dennis MS. Magnetic resonance brain imaging in patients with acute stroke: feasibility and patient related difficulties. *J Neurol Neurosurg Psychiatry*. 2005;76:1525–1527.
- Handschu R, Garling A, Heuschmann PU, Kolominsky-Rabas PL, Erbguth F, Neundorfer B. Acute stroke management in the local general hospital. *Stroke*. 2001;32:866–870.
- Nagahori T, Hirashima Y, Umemura K, Nishijima M, Kuwayama N, Kubo M, et al. Supratentorial dynamic computed tomography for the diagnosis of vertebrobasilar ischemic stroke. *Neurol Med Chir (Tokyo)*. 2004;44:105–110; discussion 110–111.
- Parsons MW. Perfusion CT: is it clinically useful? *Int J Stroke*. 2008;3:41–50.