

From the Department of Obstetrics and Gynecology, Großhadern,
Ludwig-Maximilians-University, Munich
Chair: **Prof. Dr. med. H. Hepp**

**Pharmacokinetics and Selectivity of ALA-induced Porphyrin Synthesis
after Topical Application of Hexyl-Aminolevulinic-Acid in Cervical
Intraepithelial Neoplasia**

Dissertation
zum Erwerb des Doktorgrades der Medizin
an der Medizinischen Fakultät der
Ludwig-Maximilians-Universität zu München

Submitted by
Xiuli Wang
from Weihui/Henan

2004

**Mit Genehmigung der Medizinischen Fakultät
Der Universität München**

Berichterstatter:

PD. Dr. med. P. Hillemanns

Mitberichterstatter:

Priv. Doz. Dr. D. Zaak
Priv. Doz. Dr. V. Heinemann
Prof. Dr. M. Gratzl

Mitbetreuung durch den
Promovierten Mitarbeiter:

Dekan:

Prof. Dr. med. Dr. h. c. K. Peter

Tag der mündlichen Prüfung:

07. 10. 2004

CONTENTS	PAGE NO.
1. Introduction	5
1.1. Cervical intraepithelial neoplasia	5
1.2. Human papillomavirus and CIN	6
1.3. Management of CIN	11
1.4. Photodynamic therapy and diagnosis (PDT, PDD)	11
1.5 Aim of the study	17
2. Materials and Methods	19
2.1. Patients	19
2.2. HPV detection	20
2.3. Hexyl-ALA preparation and administration	21
2.4. Fluorescence imaging for CIN lesions	21
2.5. Fluorescence microscopy for CIN tissues	24
2.6. Statistical analysis	26
3. Results	27
3.1. Fluorescence imaging for CIN	27
3.2. Time course of PPIX fluorescence intensity in normal and dysplastic epithelium after topical application of hexyl-ALA	28
3.3. Selectivity of PPIX fluorescence for CIN	30
3.4. Influence of ALA concentration on fluorescence intensity	33
3.5. Topographical fluorescence assessment by microscopy	34

4. Discussion	37
5. Summary	43
6. Zusammenfassung	45
7. Reference	47
8. Acknowledgements	57
9. Curriculum Vitae	58
10. Study Protocol	60

1. Introduction

1.1. Cervical intraepithelial neoplasia

In the late 1960s, a number of studies on precancerous lesions of the cervix suggested that the cellular changes of dysplasia and carcinoma in situ were qualitatively similar and remained constant throughout the histologic spectrum. Both dysplasia and carcinoma in situ were found to be monoclonal proliferations of abnormal squamous epithelial cells with an aneuploid nuclear DNA content. On the basis of these descriptive biological studies, Richart introduced the concept that all types of precursor lesions to squamous cell carcinoma of cervix represented a single disease process, which he termed cervical intraepithelial neoplasia (CIN) (Richart RM, 1973).

CIN is predominantly a disease of women in their reproductive years, with a large population impact and risk factors characteristic of a sexually transmitted disease.

The prevalence of CIN has increased during the last decades, especially among younger women. Currently the age specific incidence for CIN peaks in the 25-29 years old group and decreases with age thereafter (Bosch et al, 1995). Another large national program that compiles statistics of cytologic abnormalities among women in the United States was performed. This program is designed to increase access to cancer screening for low-income and uninsured women. The prevalence of cytologically detected CIN among women enrolled decreases with increasing age (Lawson et al., 1998) (Fig. 1).

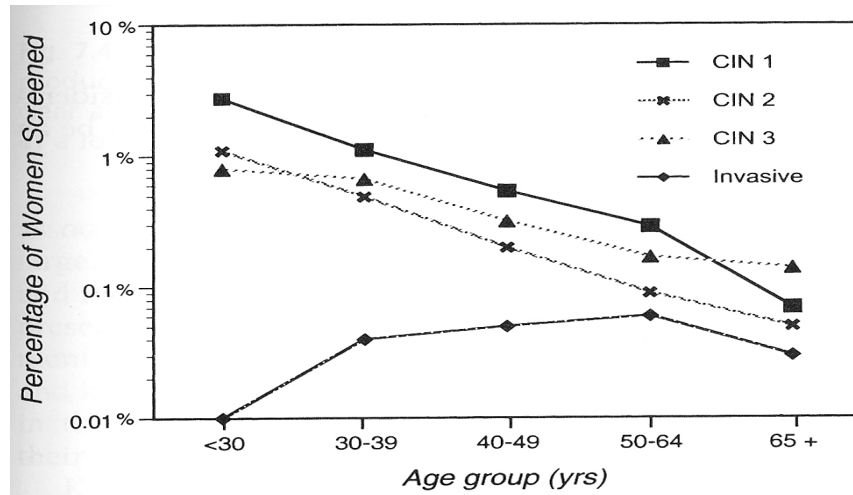


Fig. 1. Impact of age on the prevalence of biopsy-confirmed cervical lesions. Data from the National Breast and Cervical Cancer Early Detection Program demonstrates a reduction in the prevalence of both low-grade CIN and high-grade CIN with increasing age. The prevalence of invasive cervical cancer increase until age 64 years.

1.2. Human papillomavirus and CIN

A large number of epidemiologic, clinicopathologic, and molecular studies have subsequently linked the presence of specific types of human papillomavirus (HPV) to the development of anogenital cancers and their precursors, and it is now accepted that HPVs play a critical role in the pathogenesis of most cervical cancers and CIN lesions (Munoz, 2000).

Human papillomavirus (HPV) is a DNA virus with a small genome of 7.9 kilobase pairs (kb) that infect epithelial cells (Fig. 2). About 70 different genotypes have been identified to date. Some HPV types (e.g. HPV 6 and 11) are mainly detected in genital warts, flat condylomata, and low grade intraepithelial neoplasias whereas others (e.g., HPV 16 and 18) are frequently associated with severe intraepithelial neoplasia and invasive cancer, leading to the concept of two groups of HPV, low risk HPV and high risk HPV (HR-HPV).

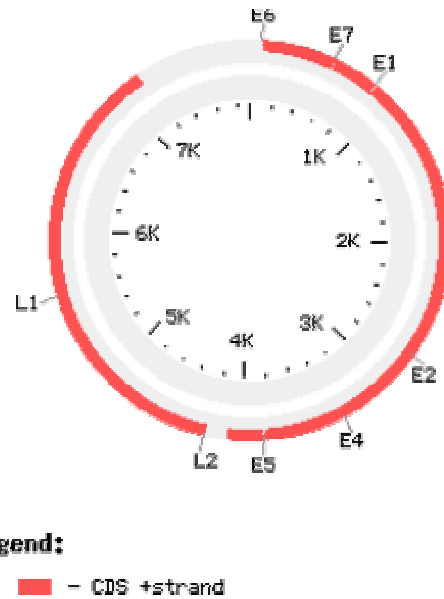


Fig. 2. Genome organization of HPV 16 deduced from the DNA sequence.

Although the HPV life cycle is not completely characterized, the rough outlines of the process are known (Fig. 3). The initial site of infection is thought to be either basal cells or primitive “basal-like” cells of the immature squamous epithelium, which may result from the presence of specific receptors for HPV on the basal cells. One potential receptor that has been localized to the basal cells complexes containing α_6 integrin complexed with either beta 1 or beta 2 integrins (Evander et al., 1997). Once HPV enters into the basal cells, it can exist within the cells in two distinct biologic states. One is as a nonproductive infection in which HPV DNA continues to reside in the basal cells but infectious virions are not produced. In the literature, nonproductive HPV infections have frequently been referred to as latent infections. In non-productive latent infections, a small number of copies of the HPV genome usually remain in the nucleus in a free circular form called an episome. Replication of the episomal DNA in latent infections is tightly coupled to the

replication of the epithelial cells and only occurs in concert with replication of the host cell chromosomal DNA. The other form of HPV infection is a productive viral infection. In productive viral infections, viral DNA replication occurs independently of host chromosomal DNA synthesis. This independent viral DNA replication produces large amounts of viral DNA and results in infectious virions. Viral DNA replication takes place predominantly in the intermediate and superficial cell layers of the stratified squamous epithelium. As the virally infected epithelial cells mature and move toward the epithelial surface, cell-derived, differentiation-specific transcriptional factors produced by the epithelium stimulate the production of viral capsid proteins. This process allows large amounts of intact virions to be formed and produces the characteristic cytopathic effects of HPV that can be detected cytologically and histologically. These cytopathic effects include acanthosis, cytoplasmic vacuolization, koilocytosis, multinucleation, and nuclear atypia.

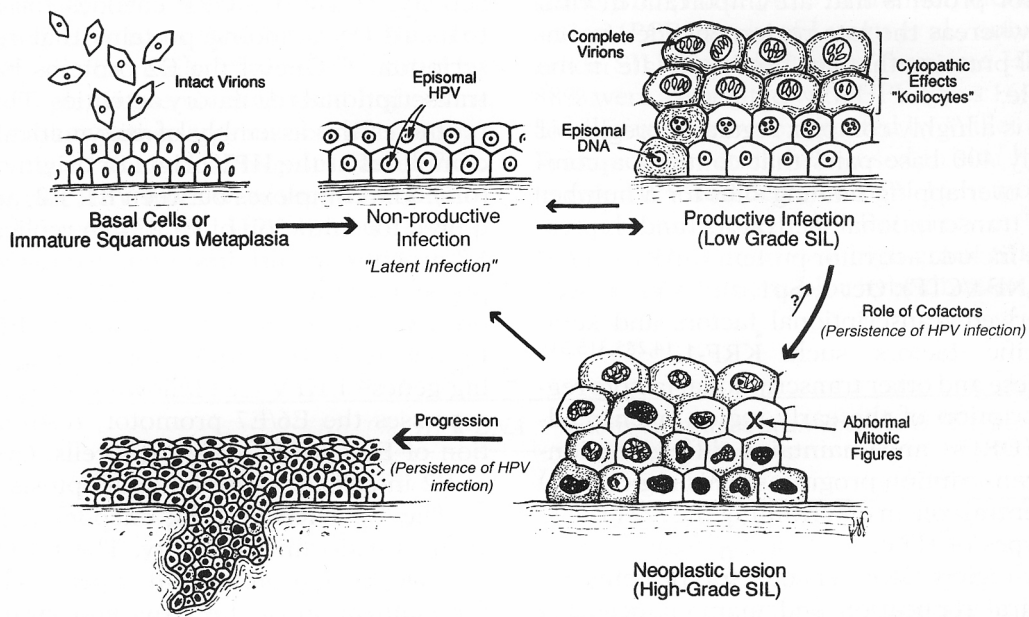


Fig. 3. Lifecycle of HPV The first step in an HPV infection is contact of intact virions with basal cells or immature squamous metaplastic cells. This can produce either a non-productive infection or productive infection. In a non-productive infection HPV DNA remains as an episomal form in the nucleus of the infected vassal cell. In productive infections, viral replication becomes uncoupled from cellular DNA synthesis and large amounts of viral DNA and proteins are made in the intermediate and superficial cell layers of the epithelium, producing the characteristic cytopathic effects of HPV. During the development of high-grade squamous intraepithelial lesion (SIL) and invasive squamous cancers, additional cellular and viral events take place resulting in the formation of a “true” cancer precursor. These can include the generation of aneuploid stemlines and integration of HPV DNA into the chromosomal DNA.

Molecular studies using tissue culture cells have provided insight into the mechanism by which HPV malignant transforms in cervical epithelium (McDougall, 1994). Substantial evidence has been accumulated demonstrating the requirement for viral oncogene expression in order to maintain the immortalized state in high risk HPV-DNA carrying cells (zur Hausen, 1996). HR-HPV such as HPV16 and 18 produce three proteins with growth-stimulating and transforming proteins, E5, E6 and E7. E5 is not essential for

transformation as the E5 region is frequently deleted in cervical carcinoma cells (Schwarz et al, 1985). However, E6 and E7 are consistently expressed in more than 90% of cervical cancers (zur Hausen, 1991). Mutational analysis of E6 and E7 indicates that the capacity to bind Rb and p53, respectively, is important for the transforming and immortalizing function of these oncoproteins (Hollingworth et al, 1991). Both E6 and E7 play important roles in productive viral infection and the life cycle of HPV. During the viral life cycle, E2-derived proteins act as important regulators of the expression of the E6 and E7 open reading frames (ORFs) (Ustav et al, 1998). In most infected epithelia, E2 appears to inhibit transcription from the E6 and E7 ORFs, which helps maintain some regulation of cellular proliferation. In most low-grade cervical cancer precursor lesions, HPV DNA exists as episome. In the episomal form, the E2 ORF is physically intact, and transcription from the E6 and E7 ORFs is presumed to be well regulated. However, in some high-grade precursor lesions, 75% of HPV16- and almost all HPV18-associated carcinomas, the HPV genome becomes physically integrated into the host chromosomal DNA (Cullen et al, 1991). Integration into the host chromosomal DNA appears to be a random event that does not lead to the consistent activation of specific cellular oncogenes. However, integration requires that the episomal viral genome breaks, and this break frequently leads to disruption of the E2 ORF (Choo et al, 1987). Disruption of the E2 ORF with retention of the E6 and E7 ORFs could result in the unregulated expression of the E6 and E7 uncontrolled cell proliferation.

1.3. Management of CIN

Numerous approaches have been suggested for treating CIN with satisfactory efficacy. Standard treatment includes excision techniques, such as cold knife conization or loop electrosurgical excision. These procedures have the advantage of providing an evaluable pathological specimen, being, however, commonly associated with post-operative bleeding. Destructive techniques, such as cryotherapy and laser ablation, frequently suffer from unsatisfactory post-operative colposcopy or, for the latter, increased costs. All methods involve a substantial destruction of the cervical stroma, which may lead to scar stricture with increased risk of infertility and necessity of subsequent cesarean section or, adversely, cervical incompetence with premature deliveries and low-birth-weight babies (Bigrigg et al., 1991; Luesley et al., 1985). 5-Aminolaevulinic acid (ALA)-mediated photodynamic therapy provides an alternative therapy avoiding complications like post-operative bleeding, cervical stenosis with consequent infertility and cervical incompetence leading to premature deliveries and low birth weight, respectively (Mathevet et al, 2003).

1.4. Photodynamic therapy and diagnosis (PDT, PDD)

Photodynamic therapy (PDT) is an investigational strategy for cancer therapy. It consists of the administration of an exogenous photoactivable compound that accumulates in malignant and other hyperproliferating tissues, followed by an adequate dose of photoactivating light. It is thought to operate via the generation of highly reactive oxygen species that induce tumour necrosis by direct cytotoxicity and /or by indirect effects mediated via collapse of the tumour vascular supply (Henderso et al., 1992; Stewart et al., 1998). Photofrin, a mixture of porphyrin, is the photosensitizer that has been used in the majority of clinical trials (Dougherty, 1987; Marcus, 1992). However, prolonged skin

photosensitivity due to non-specific localisation of the photosensitizers is associated with Photofrin-mediated PDT (Benson, 1988). Therefore new photosensitizers and better methods of photosensitizer localisation are being investigated (Bachor et al., 1991; Goff et al., 1991). Other approaches for achieving better localisation include local administration of the photosensitizer (Amano et al., 1988; Bachor et al., 1992).

In the last decade much interest has been focused on a different approach to PDT in which a precursor, 5-ALA (Fig. 4A), is administered and synthesis of the photosensitizer, Protoporphyrin IX (PPIX) (Fig. 4B), accomplished in situ (Kennedy, 1990; Loh, 1993; Svanberg, 1994, Peng et al, 1997). In most clinical and preclinical studies systemic or topical application of 5-ALA is used to temporarily increase the accumulation of porphyrins, i. e., in particular PPIX in the target tissue. 5-ALA is a precursor of heme formed by 5-ALA- synthase from glycine and succinyl-CoA, the rate limiting step of the heme biosynthesis (Fig. 5, 6). Once this step is bypassed by exogenous administration of 5-ALA, formation and accumulation of PPIX preferentially takes place in tissues known for high cellular turnover. The main reason why PPIX accumulates with some degree of selectivity is still unknown. In some tumors, however, ferrochelatase activity is reduced, which forms heme by incorporation iron into PPIX (Kondo et al, 1993). 5-ALA-induced porphyrins are cleared from the skin within 24 – 48 hours of topical, systemic, or intradermal administration. Inconvenience of the patient is minimized, e. g. by shielding against exposure of light.

To date 5-ALA-induced fluorescence has been successfully employed in diagnosis and treatment of various premalignant and malignant diseases. As a given condition for both techniques photoreactive drugs accumulate mainly in tumors and other hyperproliferating tissues such as dysplastic lesions. Light induced fluorescence can then be used to detect

CIN lesions and e. g. serve as a guide for the surgeon to resect malignant tissues (Stummer et al, 2000) or help to diagnose CIN without the requirement of an extensive training as a colposcopist. Furthermore after application of a photosensitizer light induced fluorescence renders dysplastic cell susceptible to destruction by laserlight of a certain wavelength mediated by local cytotoxic effects of reactive oxygen species, in particular, singlet oxygen. The short half-life of such cytotoxic species, the tissue selectivity of the photosensitizer and the laser irradiation restricted to the tumour area ensures that phototoxic damage localizes mainly to tumour tissue, sparing normal surrounding tissue (Henderson et al, 1992).

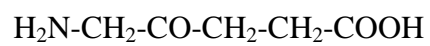


Fig. 4A. Structure of 5-Aminolevulinic acid (5-ALA)

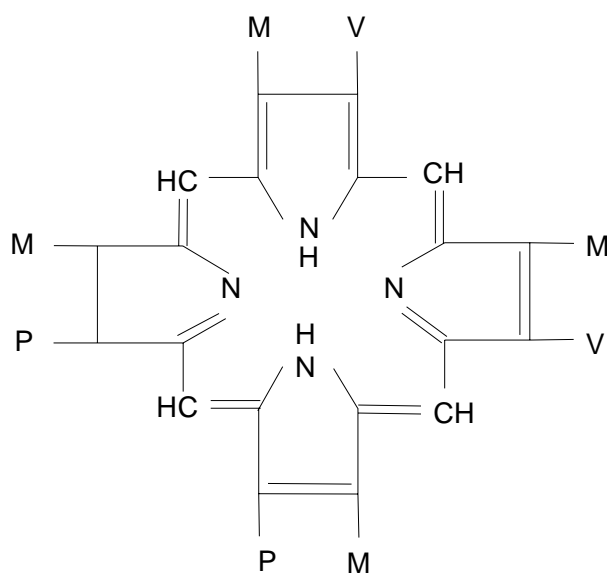


Fig. 4B. Structure of Protoporphyrin IX (P=Propionylethyl-, M=Methylethyl-, V=Vinylethyl-groups).

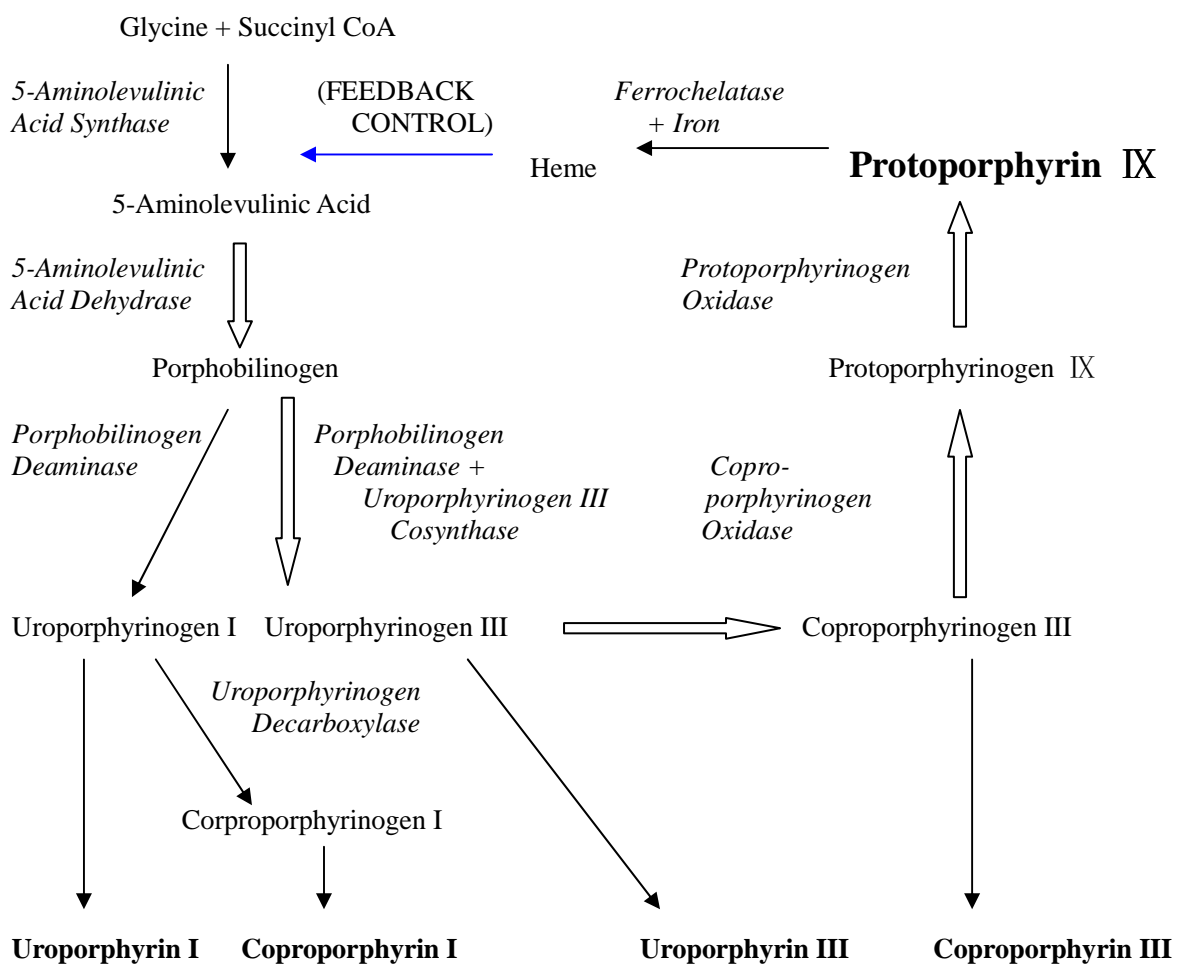


Fig. 5. Simplified biosynthetic pathway for heme. Fluorescing and photosensitizing compounds are highlighted, with bigger protoporphyrin IX highlighted. The 5-aminolevulinic acid/heme feedback control is indicated by a blue arrow. The principal biosynthetic route for ALA-induced protoporphyrin IX is indicated by the large arrows.

Heme biosynthesis and application of 5-ALA

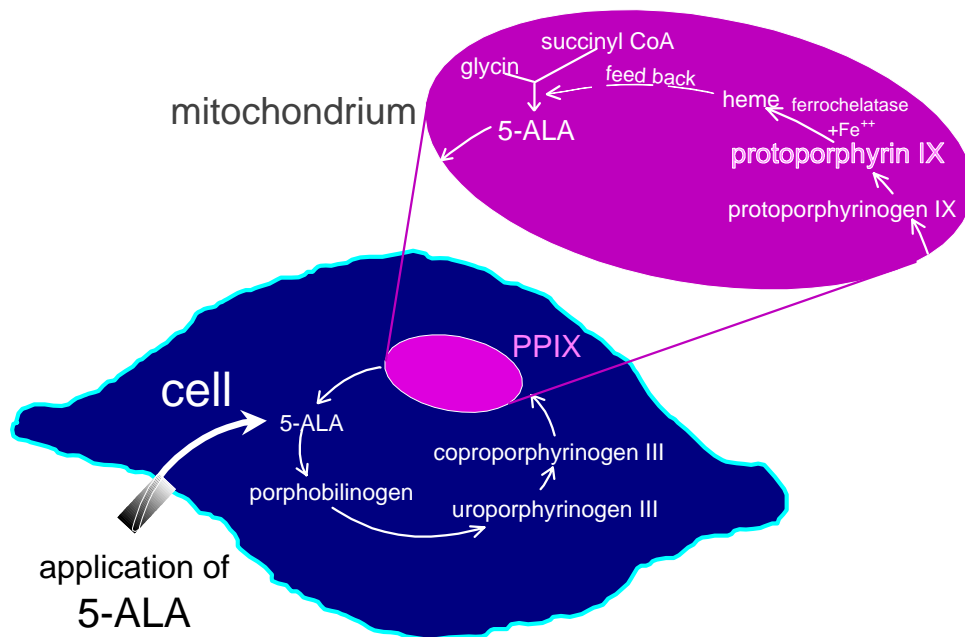


Fig. 6. Photosensitizer: Protoporphyrin IX, induced by topical 5-ALA application.

Photodynamic diagnosis (PDD) is the method of choice for the endoscopic detection of preneoplastic and neoplastic lesions of the urinary bladder (Zaak et al, 2002) and has been proven to be a reliable tool for the detection of low and high grade dysplasia in Barrett's oesophagus, melanoma, oral and laryngeal cancer, and early stage lung cancer (Endlicher et al, 2001, Pahernik et al, 2001, Leunig et al, 2002, Baumgartner et al, 1996). Furthermore 5-ALA induced fluorescence is useful in guided resection of tumors, such as glioblastoma (Stummer et al, 2000) or ovarian cancer (Hillemanns et al, submitted for publication).

1.5. Aim of the study

For CIN lesions studies showed equivocal outcomes. Although Hillemanns et al could verify specific porphyrin fluorescence of CIN after local administration of 1 % aqueous solution of 5-ALA (Hillemanns et al 2000), photodynamic therapy after topical application of 3% 5-ALA in Intravite Gel® was not successful in the treatment of CIN (Barnett et al, 2002). In contrast in another study PDT with 5-ALA applied to the cervix as a 12 % watery solution was efficient in improving the grading of the PAP smears in 19 of 20 CIN patients and in eradication of cervical HPV-Infection in 80 % (Wierrani et al, 1999). These contradictory results suggest that the outcome of PDD and PDT depends on various factors.

Esterified derivatives of ALA that increase its lipophilicity, such as methyl-ALA, butyl-ALA and hexyl-ALA, could potentially enhance efficacy. Xiang et al. confirmed that hexyl-ALA penetrates across biological barriers of cervical carcinoma cell lines in a significantly faster manner, generated an obvious higher formation of PPIX and induced the highest level of phototoxicity compared to 5-ALA or other ALA-ester (Xiang et al., 2001). In non lesional skin, equimolar concentrations of the hexyl and pentyl ester, but not butyl ester, promote higher PPIX levels and greater PPIX-induced phototoxicity than ALA (Gerscher et al, 2000; Gerscher et al, 2001).

Thermogel is a thermolabile bioadhesive gel which consist of Lutrol F-127 (poloxamer 407). The significant character of thermogel is the temperature dependant viscosity. It is of

liquid state at 4°C and turn into viscous gel state at more than 30°C. It is easy to handle and proved reliable as vehicle carrier for the application to cervix (Andikyan et al, 2004).

In order to obtain basic clinical data for the further development of PDD and PDT, we investigated the pharmacokinetics and the tissue selectivity of topically applied ALA-induced porphyrins from hexyl-ALA-thermogel in patients with CIN lesions by in situ fluorescence microscopy of conization specimens.

2. Materials and Methods

2.1 Patients

Our study was approved by the ethics committee of our institution, and informed consent was obtained from all women enrolled. Twenty-four non-pregnant women with a mean age of 39 years (range 22 - 47 years) with a cytological diagnosis of high grade or permanent low grade squamous intra-epithelial lesions were included. Each patient had a complete history and gynecologic examination taken including cervical cytology, HPV DNA testing, colposcopy and biopsy. Tissue biopsies were obtained according to colposcopy. H&E staining of the final conization specimens showed CIN 1 in 9 cases, CIN 2 in 8 cases, and CIN 3 in 7 cases (Fig. 7). In one case, the specimen taken for the study measurements was not satisfactory, containing only endocervical glands (histology showed CIN 3 of the conization specimen).

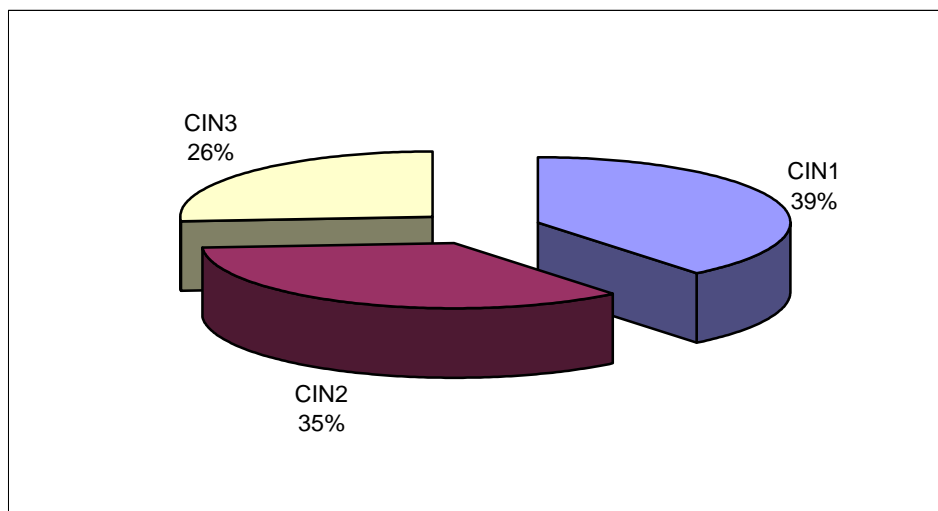


Fig. 7. The ratio of CIN component

2.2. HPV detection

Specimens were tested for HPV DNA by the Food and Drug Administration (FDA) approved Hybrid Capture 2 HPV DNA assay (Digene, Silver Spring, MD) and analyzed for the presence of low risk HPV types 6, 11, 42, 43, and 44 and high risk HPV types 16, 18, 31, 33, 35, 45, 51, 52 and 56. The hybrid capture system is a capture molecular hybridization assay that uses chemoluminescence detection in tubes. Samples were classified positive for HPV DNA if the relative light-unit reading obtained from the luminometer was equal to or greater than the mean of positive control values according to the instructions by the manufacturer. One woman was negative for HPV DNA, whereas one harboured only low risk type viruses, 22 harboured high risk type viruses, and one harboured both high and low risk viruses (Fig. 8).

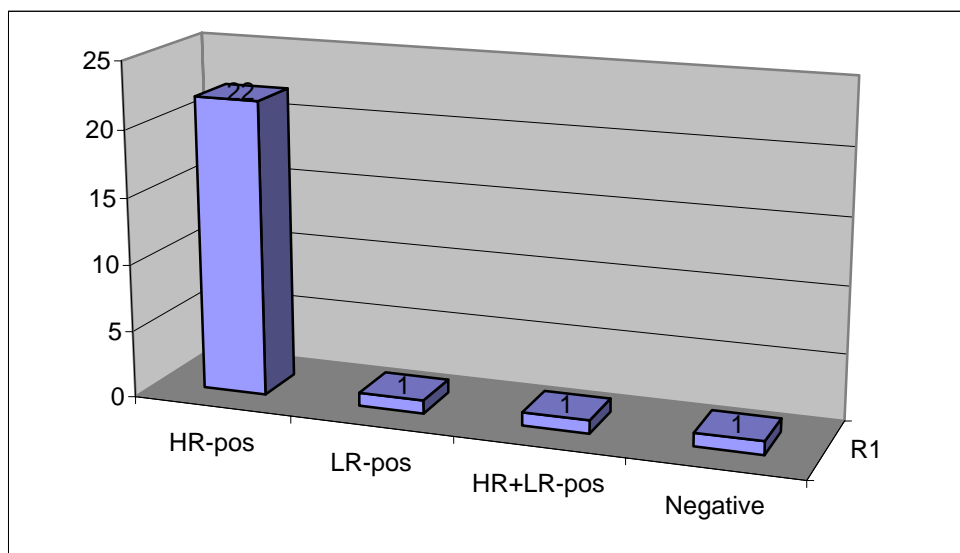


Fig.8. HPV DNA detection in CIN patients

2.3. Hexyl-ALA-thermogel preparation and administration

Thermogel was supplied as powder by Biolitec GmbH (Jena, Germany). 19% thermogel was made dissolving Lutrol F-127 powder in sterile water and stored at 4°C. 4mmol (mM) and 10mM hexyl-ALA-thermogel were freshly prepared before application at 4°C. Ten millilitres of hexyl-ALA-thermogel in concentrations of 4 mM (12 patients), 10 mM (12 patients) were topically applied to the cervix for 5 to 720 minutes.

2.4. Fluorescence imaging for CIN lesions

Prior to surgical conization, the fluorescence video image analysis was performed using a special equipment for semiquantitative fluorescence video image analysis of ALA-induced porphyrin (Fig. 9). It was performed under violet light (D-LIGHT) by looking through a modified endoscope (Fig. 10). Visual observation of the fluorescence images was possible with the naked eye. For documentation, a sensitive color charge coupled device camera was attached to the endoscope. A specific red PPIX fluorescence of the CIN lesions corresponding to the acetowhite colposcopic pattern with mosaicism was observed after an optimal time applying ALA.




Fig. 9. Complete equipment for fluorescence endoscope with ALA

The standard equipment includes D-LIGHT System and fluorescence-capable endoscopes (KARL STORZ GmbH). Video documentation additionally requires: fluorescence-capable camera (TRICAM SL-PDD), video monitor and video recorder.

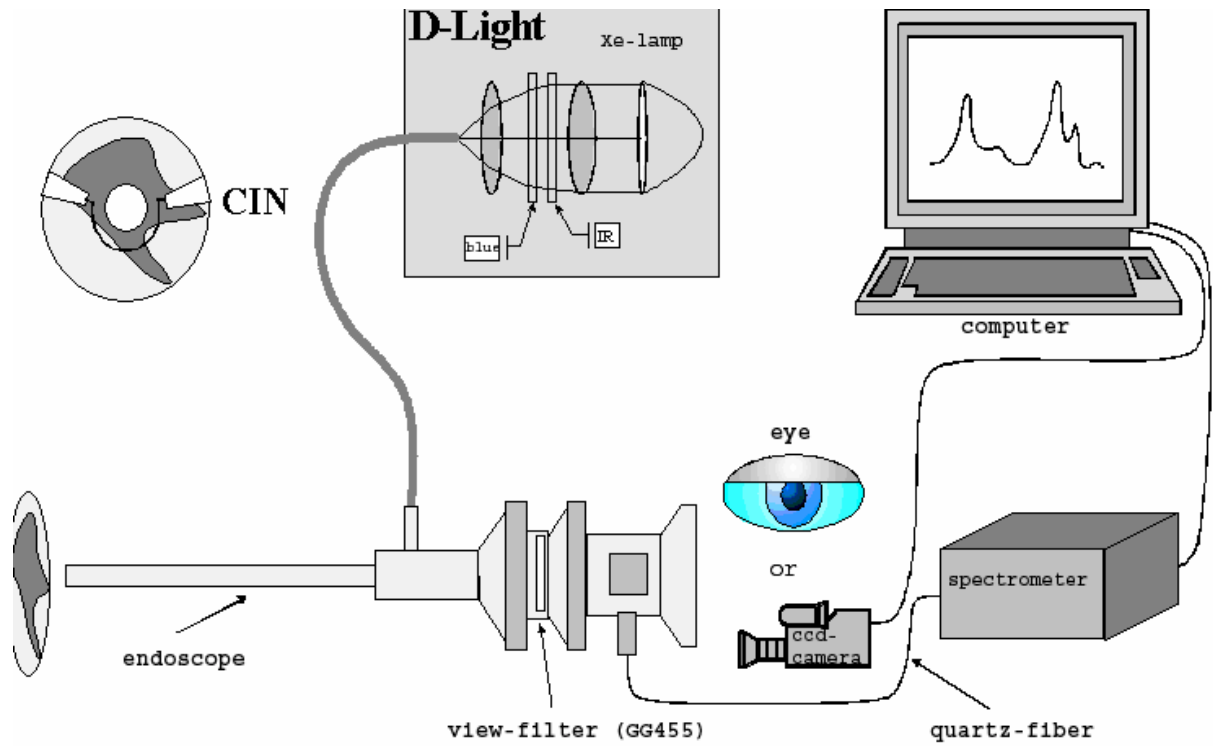


Fig. 10. Scheme of the fluorescence imaging and spectroscopic system used for fluorescence photodetection of cervical lesions after topical application of ALA. CIN: cervical intraepithelial neoplasia

2.5. Fluorescence microscopy for CIN tissues

Excised tissues were forwarded for routine diagnostic evaluation, while a segment of the resected tissue (conization specimens) was deep frozen at -80°C for quantitative fluorescence measurements. Samples were cut under reduced ambient light into serial cryosections for histological evaluation ($6\ \mu\text{m}$ thickness; staining with haematoxylin and eosin) and for quantitative fluorescence microscopy ($15\ \mu\text{m}$ thickness).

All procedures were carried out under reduced ambient light to minimize photodegradation of porphyrins. On a microscope with epifluorescence and transillumination facilities (Orthoplan; Leitz, Wetzlar, Germany), images from identical areas (magnification 10X) were taken by a Three-Chip-CCD camera with an integration mode which was developed for the purpose of fluorescence documentation (Tricam SL PAL PDD, K. Storz, Tuttlingen, Germany) (Fig. 11). This set-up allowed us to depict two different images from identical areas in one tissue section at a high spatial resolution, one by transillumination for determining regions of interest (ROI) for specific tissue types and one by fluorescence microscopy for quantifying fluorescence with a high light sensitivity. A 100 Watt mercury light source was used to excite porphyrins by a wavelength of 355 to 425 nm. Fluorescence emission was detected above 610 nm. Transillumination and fluorescence images were digitized and analyzed by an image analysis system (Optimas 6.2, Media Cybernetics, Silver Spring, MD, USA). For measurements, the regions of interest (ROI) in dysplastic squamous epithelium and normal tissue were identified from sequential histological sections stained with hematoxylin and eosin, defined in the transilluminated picture, and the respective fluorescence intensity was quantified in the fluorescence image.

In each specimen, fluorescence was quantified in defined ROIs (as mentioned above) of

dysplastic and normal squamous epithelium as well as of subepithelial stroma and some specimens of cervical glands.

Squamous epithelium was divided into three layers:

- lower layer: basal and parabasal cells
- middle layer: intermediate cells
- upper layer: superficial cells

Because of the heterogenous morphology of particularly the dysplastic epithelium we quantified the intensity of PPIX fluorescence in the corresponding layer of normal and dysplastic squamous epithelium.

The contrast of red PPIX fluorescence to green autofluorescence was divided into four degrees:

- no fluorescence (0 point)
- little fluorescence (1 point)
- moderate fluorescence (2 points)
- strong fluorescence (3 points)

Quantitative spectroscopy was performed at a wavelength of 635 nm for PPIX fluorescence and at 600 nm for autofluorescence using an optic multi-channel-analyzer (Princeton Instruments, Trenton, NJ, USA), which was connected to the camera by a fiber.

Results are given as mean values from 625 to 635 nm and 595 to 605 nm wavelength, respectively.

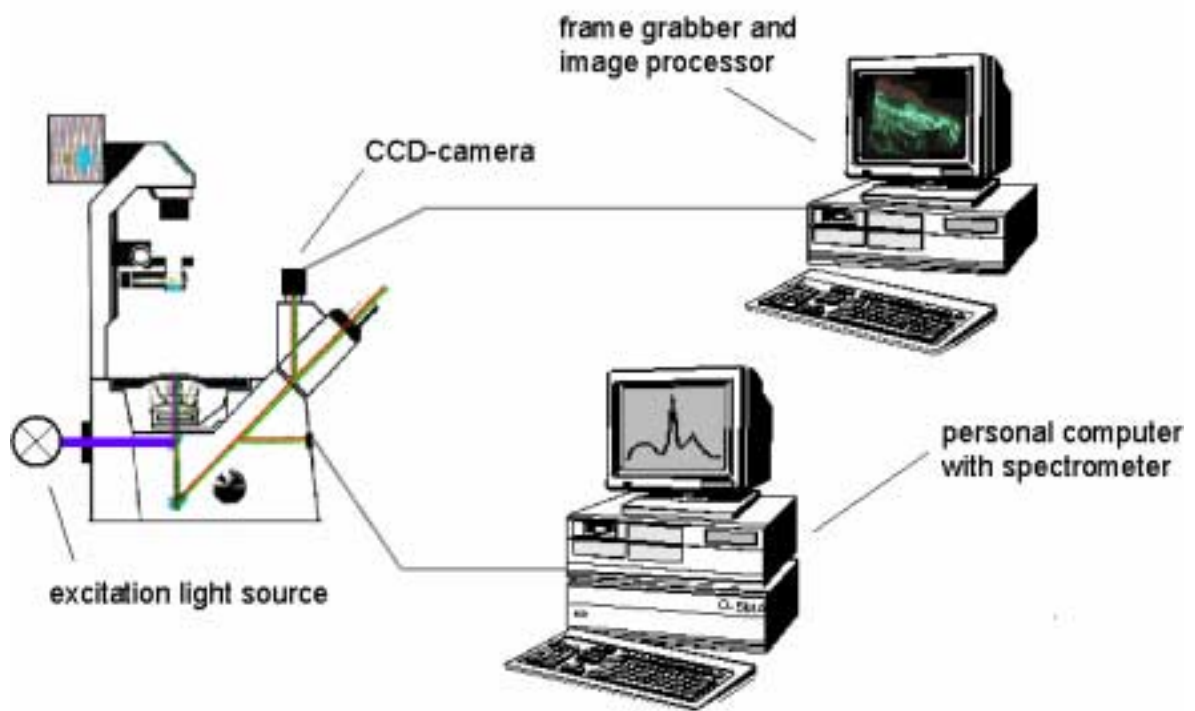


Fig. 11. Scheme of the fluorescence microscope and imaging system used for transillumination and fluorescence images of CIN tissues.

2.6. Statistical analysis

Statistical analysis was performed using the Student-t-Test. P-values < 0.05 were regarded as statistically significant.

3. Results

3.1. Fluorescence imaging for CIN

The modified endoscope proved to be applicable for real-time and non-invasive fluorescence imaging of ALA- induced PPIX of the ectocervix in 24 CIN patients. The red fluorescence could be studied either directly by looking through the endoscope or on a video monitor via an attached color endocamera. During endoscopic evaluation of the portio uteri and the vagina, switching of camera and light modes between blue light for fluorescence detection and normal white light was easy to perform and did not hinder the procedure.

Using an optimal time frame of 100-540 minutes between hexyl-ALA application and fluorescent detection, we observed a specific red PPIX fluorescence of the CIN lesions corresponding to the acetowhite colposcopic pattern with mosaicism (Fig. 12).

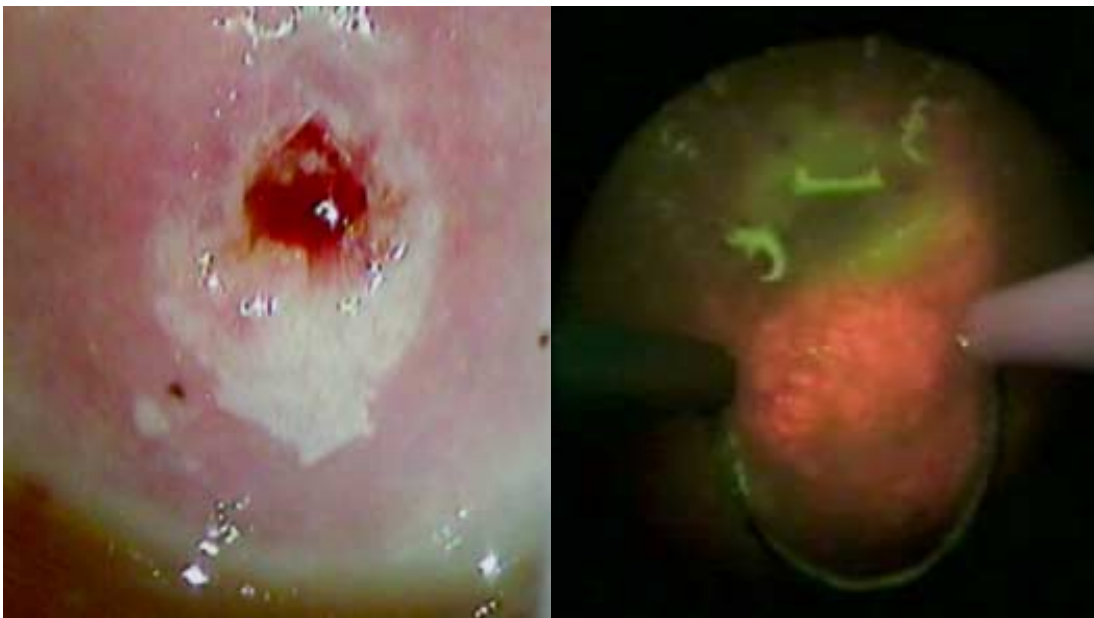


Fig. 12. Colposcopy of a CIN 2 lesion at the posterior lip of the ectocervix representing acetowhiteness and mosaicism is shown. Correspondingly, the red hexyl-ALA-induced PPIX fluorescence of the same lesions is clearly distinct from the background of the greenish autofluorescence of the normal cervical tissue.

3.2. Time course of PPIX fluorescence intensity in normal and dysplastic epithelium after topical application of hexyl-ALA

All of the specimens were obtained from the surgical conization tissues of CIN patients. One patient was evaluated at one time point in our study.

According to data from our in vitro study (Xiang et al., 2001), it was assumed that uptake and conversion of hexyl-ALA to PPIX requires a short time interval. Therefore, we proposed in this feasibility study a short incubation of hexyl-ALA with time intervals from 5 minutes to 100 minutes for both concentration 4 mM and 10 mM. After the assessment of fluorescence microscopy in the conization resections, rather low fluorescence intensity values were detected. Therefore, longer incubation intervals had to be evaluated. However, time intervals of 300 to 500 minutes are clinically difficult because the conization surgery is performed in the morning and the application should be done between midnight and morning.

The histological evaluation of the 24 specimens revealed CIN 1-3 in 23 cases, however, in one specimen (4 mM hexyl-ALA) no squamous epithelium could be seen. By means of fluorescence microscopy, the hexyl-ALA induced PPIX fluorescence intensity was measured both in dysplastic and adjacent normal epithelium of the 11 specimens with 4 mM hexyl-ALA and 12 specimens with 10 mM hexyl-ALA. The spectroscopic measurement were performed three times for one specimen. The mean of the measurement was displayed in the figures. The time course of the intensity of porphyrin fluorescence in 23 patients with 4 mM and 10 mM hexy-ALA is shown in Figure 13 A-B.

In both dysplastic and normal adjacent epithelium fluorescence intensity increased with time of exposition. Up to sixty minutes nearly no fluorescence could be detected. Then the fluorescence intensity rose and reached a peak between 180 to 540 minutes. After an application time of 540 minutes, the fluorescence intensity seemed to decline again. However, due to limited data of the long incubation intervals this remains speculative. Time-dependency of fluorescence intensity showed the same kinetics in normal epithelium and CIN lesions. However the peak between 180 to 540 minutes was much more pronounced in dysplastic epithelium just as the absolute fluorescence intensity was generally higher in CIN than in normal adjacent epithelium.

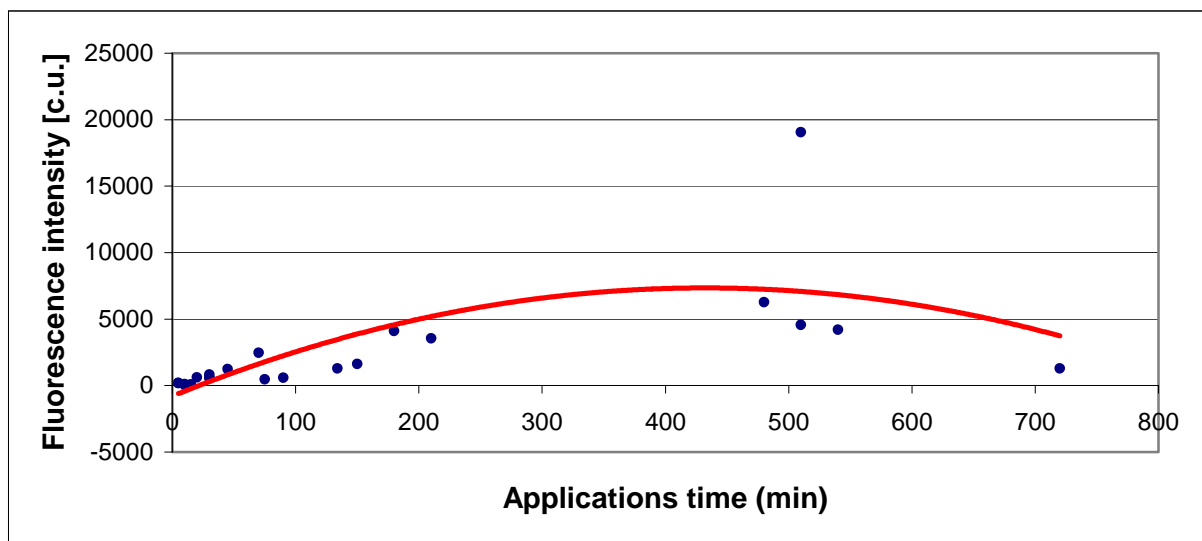


Fig. 13 A. Fluorescence intensity (calibrated units) and application time of hexyl-ALA in CIN 1-3

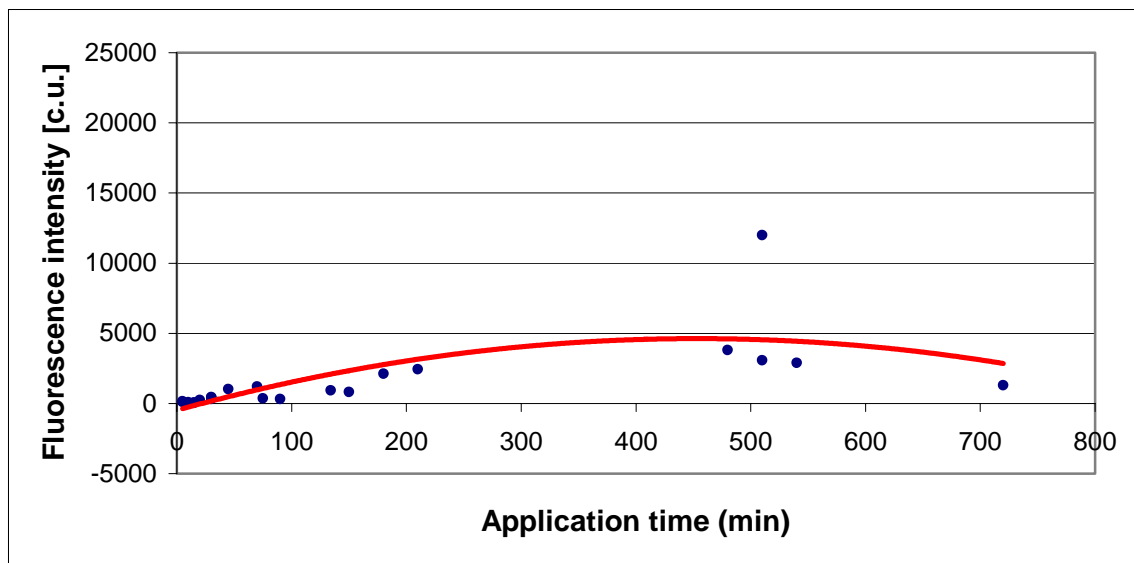


Fig. 13 B. Fluorescence intensity (calibrated units) and application time of hexyl-ALA in normal epithelium

The fluorescence pattern was homogeneous along the horizontal dimension of the tissue section. There was no such irregularities noted as compared to our first study employing 3% 5-ALA without Lutrol F-127 thermolabile gel as carrier (Pahernik et al, 1998).

3.3. Selectivity of PPIX fluorescence for CIN

Mean fluorescence intensity of 23 specimens with 4 mM and 10 mM hexyl-ALA was 1484 ± 263 calibrated units (c.u.) for normal epithelium and 2342 ± 381 c.u. for CIN of different grades. This difference is statistically significant ($p < 0.05$) (Fig. 14). The mean fluorescence intensity of the 9 cases with CIN 1, the 8 cases with CIN 2 and of the 6 cases with CIN 3 were 2052 ± 361 c.u., 2516 ± 147 c.u. and 2546 ± 353 c.u., respectively (Fig.

15). Comparing the mean fluorescence intensity of high and low grade CIN no statistical difference could be found.

Tumour selectivity which is a preferred parameter for PDD and to a certain extent also for PDT was defined as the ratio of dysplastic vs. adjacent normal epithelium in 23 specimens. According to the regression curve set through the measured fluorescence data the tumor selectively for CIN showed a peak of 1.8 after 240 to 420 minutes, gradually decreasing afterwards to a ratio of 1 after 600 to 720 minutes (Fig. 16). However, it has to be stressed that this is an assumption based on only few long term incubation data.

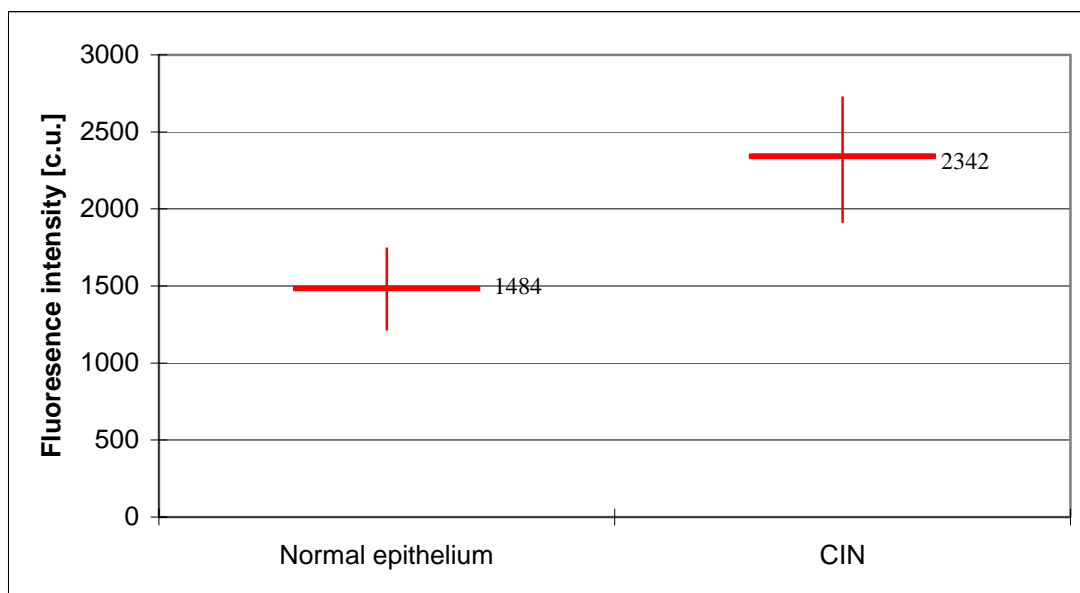


Fig. 14. Mean PPIX fluorescence intensity in normal squamous epithelium and CIN (p<0.05)

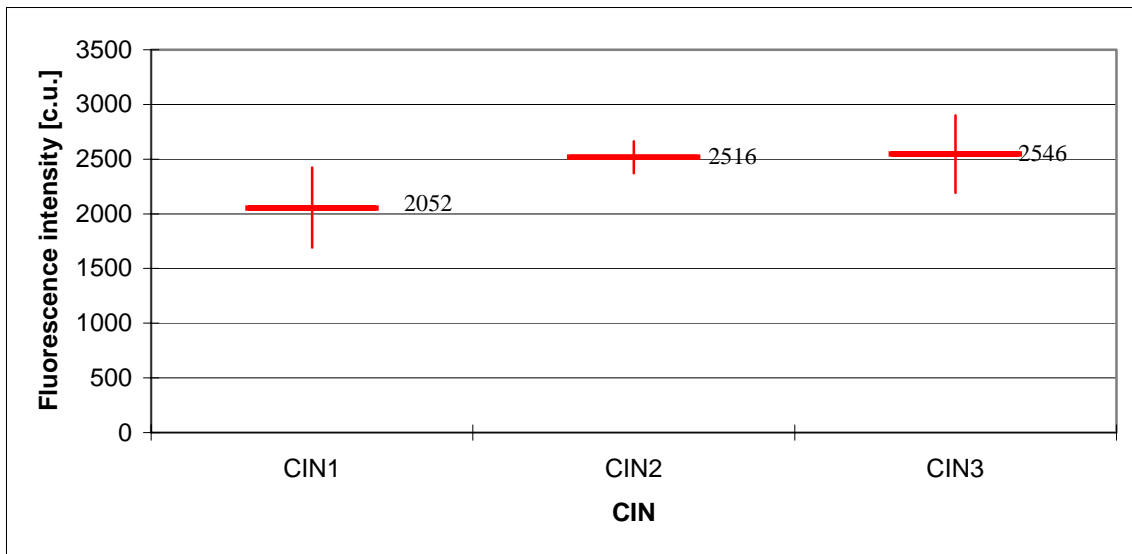


Fig. 15. Mean PPIX fluorescence intensity in CIN1-3 ($p>0.05$)

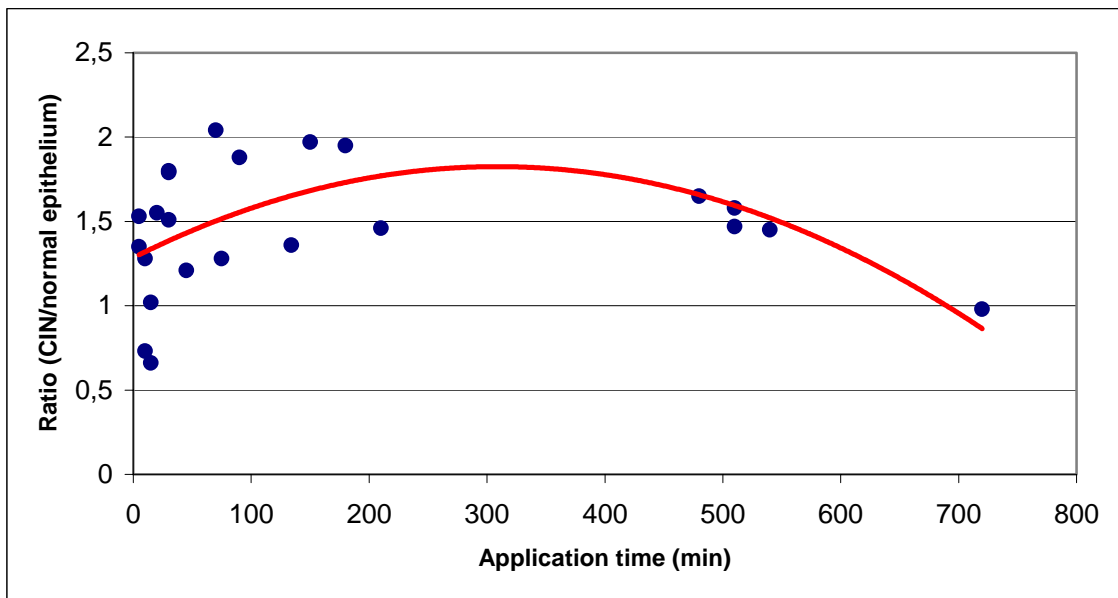


Fig. 16. Ratio of PPIX-fluorescence intensity of CIN vs. normal epithelium

3.4. Influence of hexyl-ALA concentration on fluorescence intensity

PPIX fluorescence intensity after administration of 4mM (11 cases) and 10mM (12 cases) concentration of hexyl-ALA were 2294 ± 175 c.u. and 2386 ± 463 c.u. in CIN 1-3, respectively (Fig. 17). It did not reach statistical significant but the PPIX fluorescence intensity was more stable and higher after application of 10mM hexyl-ALA (Fig. 18).

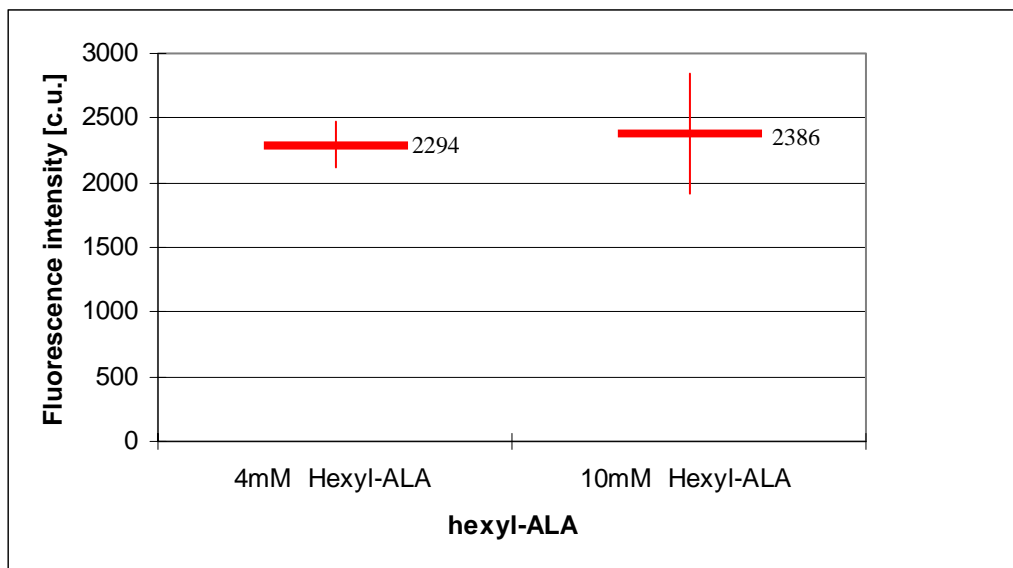


Fig. 17. Mean PPIX fluorescence intensity in 4mM hexyl-ALA and 10mM hexyl-ALA groups ($p>0.05$)

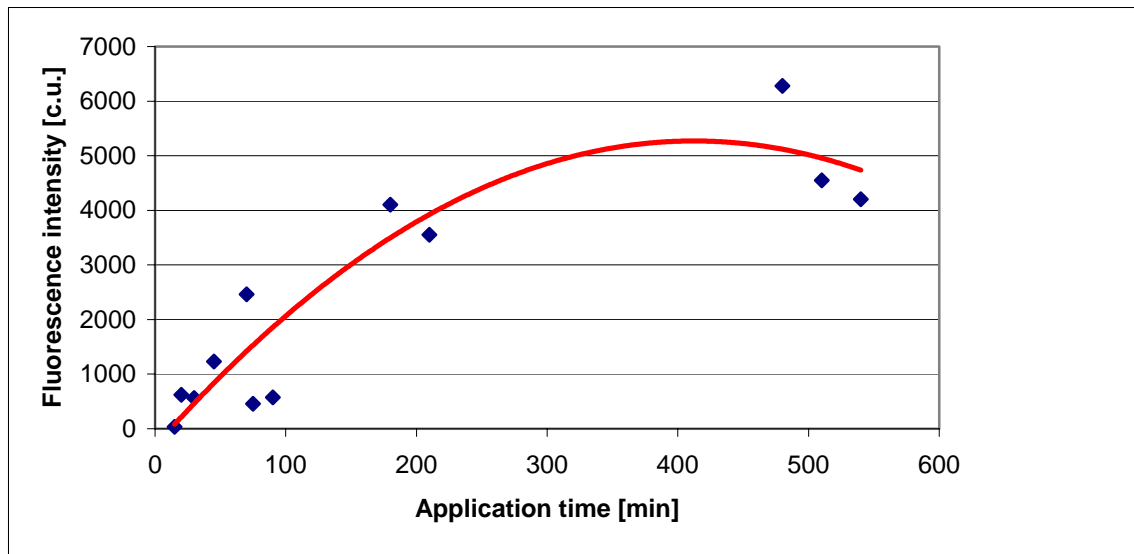


Fig. 18. The PPIX fluorescence intensity after application of 10mM hexyl-ALA in CIN 1-3

3.5. Topographical fluorescence assessment by microscopy

Table 1. shows the results of a semi-quantitative evaluation of fluorescence intensity by microscopy in 23 CIN patients.

Maximum intensity could generally be detected in the lower layer of the epithelium, consisting of basal and parabasal cells. Fluorescence intensity gradually declined from the basal membrane to the surface of the epithelium (Fig. 19, 20). The fluorescence intensities of the lower layer is much higher than in the upper layer ($p < 0.05$), but not significantly higher than in the intermediate layer ($p > 0.05$). This applies to normal and dysplastic epithelium. In CIN lesions PPIX fluorescence intensity (mean $5.2 \pm 0,88$) was higher than in normal epithelium (mean $3.45 \pm 0,4$). This difference is statistically significant ($p < 0.05$). The fluorescence intensities of between lower, intermediate and upper layers of CIN lesions did not reach statistics statistically significance compared to normal epithelium ($p > 0.05$).

Table 1: Mean PPIX-fluorescence intensity in semiquantitative, topographic fluorescence microscopy in normal squamous epithelia and CIN

Histology	Total Fluorescence	Fluorescence in lower layer	Fluorescence in intermediate layer	Fluorescence in upper layer
Negativ	3,45±0,4	1,5	1,25	0,7
CIN	5,2±0,88	2,23	1,8	1,17

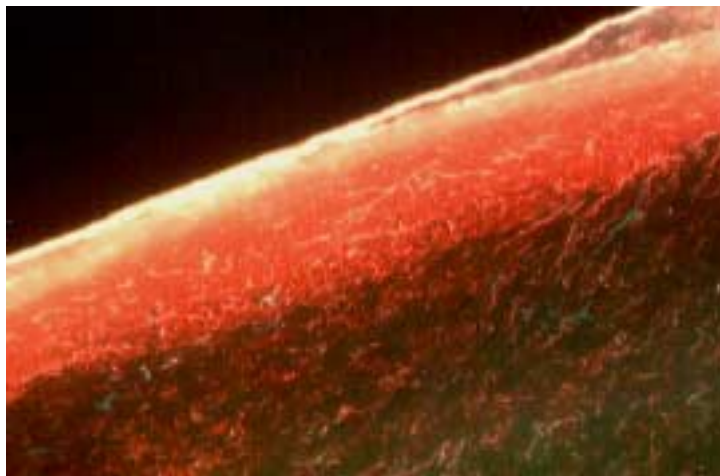


Fig. 19A. Topographical fluorescence. Strong fluorescence in the squamous epithelia of CIN3 (x 100)

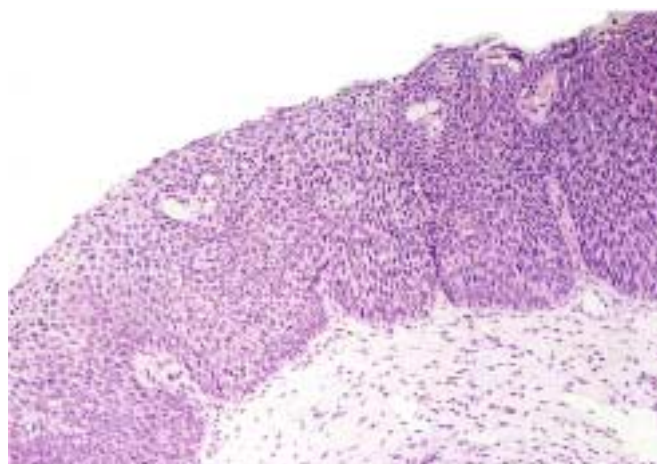


Fig. 19B. Histopathologic findings of patient 19A (H&E, x 100)

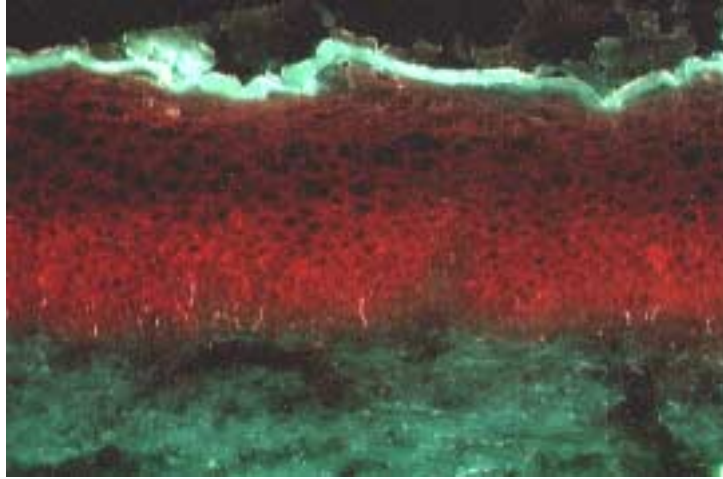


Fig. 20A. Topographical fluorescence. Moderate fluorescence in the squamous epithelium of CIN1 (x 100)

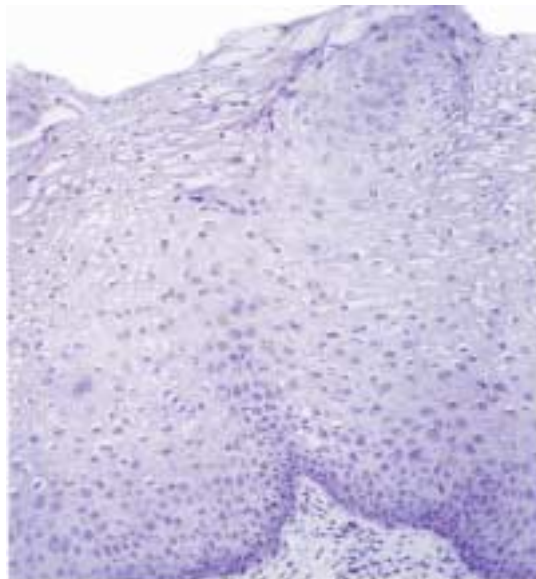


Fig. 20B. Histopathologic findings of patient 20A (H&E, x 100)

4. Discussion

Topical ALA induced endogenous photosensitisation seems to be a very promising approach for selective PDT and has been used clinically for various diseases. A great advantage of topical PDT compared with systemic photosensitizers like photofrin is the rapid clearance of protoporphyrin and ALA from the skin. In addition, compared to systemic application of ALA, after its topical administration no significantly increased porphyrin levels in plasma were detected. Systemic ALA administration might cause liver damage as well as neuropsychiatric disorders similar to symptoms of acute intermittent porphyria (Regula et al, 1995).

Up to now, only a few studies have been performed with respect to the pharmacokinetics of ALA- induced porphyrins following topically application using various administration modalities and dosages. This study was designed to obtain more information about pharmacokinetics and selectivity about 5-ALA induced PPIX fluorescence from hexyl-ALA as a basis for porphyrin mediated diagnosis and therapy of CIN.

To date several studies investigated concentration-dependency of 5-ALA-induced fluorescence in vitro (Rossi et al, 1996; Fukuda et al, 1993). Fukuda et al. cultured mammalian epithelial cells (CNCM-I-221) and Rossi et al. cultured various gynaecological tumour cell lines (HeLa, SiHa, MDA-MB-231, A2780-9S, 2780^{AD}) with 5-ALA. They all could find a stagnation of fluorescence with rising concentration. This saturation may be attributed to a limited uptake of 5-ALA or a limited conversion to PPIX (Iinuma et al, 1994). Our group demonstrated that hexyl-ALA penetrates across biological barriers of cervical carcinoma cell lines in a significantly faster manner, generated a obviously higher

formation of PPIX and induced the highest level of phototoxicity compared to 5-ALA or other ALA-ester (Xiang et al., 2001). Recently, a clinical investigation with hexyl-ALA has shown that hexyl-ALA induced fluorescence can be used for photodynamic diagnosis (PDD) in human bladder cancer. They applied 4 to 16 mM hexyl-ALA to assess the feasibility and the advantages of a topical ALA ester-based fluorescence photodetection in the human bladder. The results shown that the application of 8 mM hexyl-ALA could provide sufficient PPIX fluorescence for reliable photodetection of malignant and pre-malignant lesions. The PPIX fluorescence intensity reached a twofold increase using 20-fold lower concentrations as compared to ALA (Lange et al, 1999). Furthermore, Marti et al demonstrated that hexyl-ALA could lead to a homogenous distribution of PPIX fluorescence in pig bladder model (Marti et al, 1999). Therefore, we applied two different concentrations of hexyl-ALA (4mM and 10mM) to the cervix in order to identify the required concentration to reach the highest fluorescence intensity. Fluorescence intensity was highest after application of 10mM hexyl-ALA but we could not find a statistical difference in the fluorescence intensity achieved by different hexyl-ALA-concentrations. However, the hexyl-ALA induced fluorescence was longer stable at 10mmol compared to 4 mmol which may be relevant to extended cytotoxic effects. Consequently, we recommend the use of 10mM hexyl-ALA for PDT.

We also investigated the time course of PPIX fluorescence and found for CIN-lesions an increased porphyrin fluorescence peak beyond 200 minutes. Up to sixty minutes nearly no fluorescence could be detected. Then the fluorescence intensity rose and reached a peak between 180 to 540 minutes. After an application time of 540 minutes, the fluorescence intensity seemed to decline again. However, due to limited data of the long incubation

intervals this remains speculative. Our results are concordant to other investigations showing a peak fluorescence intensity after 4 to 7 hours depending on the mode of application (Ash et al, 1993). Based on these data we recommend an exposition-time of more than 200 minutes.

A statistically significant difference in PPIX fluorescence intensity was found between CIN (2342 ± 381 c.u.) and normal surrounding squamous epithelium (1484 ± 263 c.u.) ($p < 0.05$). Furthermore, we could also observe a clear contrast between CIN tissue and normal surrounding epithelium. This so called dysplastic cell selectivity was defined as ratio of fluorescence intensity in CIN areas vs. fluorescence intensity in normal tissue. For PDT high dysplastic cell selectivity means an optimum therapeutic effect with minimum destruction of normal tissue. Kinetics showed that dysplastic cell selectivity was best between 60 and 200 minutes according to raw data. According to the regression curve set through the measured fluorescence data the tumor selectivity for CIN showed a peak of 1.8 after 240 to 420 minutes, gradually decreasing afterwards to a ratio of 1 after 600 to 720 minutes. However, it has to be stressed this is an assumption based on only few long term incubation data. The highest measured selectivity between 60 and 200 minutes in this fluorescence microscopy study corresponds to clinical data using fluorescence diagnosis and spectroscopy of patients. Longer time intervals reached a lower selectivity, but higher fluorescence (Hillemans et al, 2000).

Compared to our previous 5-ALA- induced porphyrin fluorescence microscopy study, we achieved improved results with hexyl-ALA (Andikyan et al, 2004) (Tab. 2). The maximum fluorescence derived from the extrapolated curve (Fig.13A) is 7500 calibrated units.

However, the reliability of that value is limited because of the few data gathered in long incubation intervals. Hexyl-ALA induced a three-fold higher fluorescence intensity compared to 5-ALA in the same through timely separate experimental setting. The optimal time intervals did not differ significantly between hexyl-ALA and 5-ALA thermogel. The averaged tumor selectivities for hexyl-ALA and 5-ALA measured as ratio of CIN versus normal epithelium were the same with 1.6. Therefore, hexyl-ALA seems superior compared to 5-ALA and may be recommended for the PDT of CIN lesions. The ratio of CIN versus normal epithelium is an important parameter for fluorescence diagnosis. For photodynamic therapy, however, a maximum fluorescence intensity seems to be of at least equal importance. If a high fluorescence intensity can be achieved while having a high tumor selectivity, the treatment effect may be restricted to lesional areas only. Otherwise, the illumination has to be restricted to CIN areas only in order to avoid side effects in normal tissue.

Tab. 2. Comparison of PPIX fluorescence with 5-ALA and hexyl-ALA

	5-ALA	hexyl-ALA
Maximum fluorescence intensity (c.u.)	2060	7500
Optimal time (minutes) for maximum fluorescence intensity	300	>200
Ratio of fluorescence CIN vs. normal epithelium	1116/704=1.6	2342/1484=1.6

Pahernik et al. applied topically 3% ALA solution on CIN lesions. Four hours later, fluorescence intensities in tumors were significantly exceeding normal surrounding host tissue, but the quantification of ALA induced fluorescence as a function of penetration depth revealed that fluorescence intensity was heterogeneous in CIN tissue (Pahernik et al. 1998). It is important to note that PDT may lead to ineffective elimination of dysplastic cells because of a heterogeneous accumulation of PPIX. However, topographic fluorescence microscopy showed a more homogenous distribution of PPIX fluorescence in dysplastic tissue in our hexyl-ALA study (data not shown). Compared to Pahernik's study, hexyl-ALA could lead to a more homogenous distribution of PPIX fluorescence in dysplastic epithelium. This is of major importance for PDT as homogenous PPIX fluorescence facilitates a more effective elimination of premalignant cells.

Topographical fluorescence assessment by microscopy showed that maximum intensity could generally be detected in the lower layer of the epithelium, consisting of basal and parabasal cells, and gradually declined from the basal membrane to the surface of the epithelium. This may be explained by the fact that the highest mitotic activity is being found in the basal and parabasal cells, which may lead to an accelerated conversion rate of hexyl-ALA to PPIX. As opposed to the proliferative basal cells, the intermediate and superficial cells are characteristic for cell differentiation. This has been demonstrated by various virological and molecular cell studies (Howley et al, 1990; zur Hausen, 1996). It would be advantageous to have an improved photodynamic treatment effect in the higher fluorescing basal/parabasal layers, where cell proliferation and replication of HPV take place.

Our findings suggest that hexyl-ALA with Lutrol F-127 thermolabile gel as a vehicle seems to be a promising molecule for fluorescence diagnosis and treatment of CIN lesions. Another relevant factor contributing to a more homogeneous distribution of PPIX may be the use of Lutrol F-127 thermolabile gel which yields a more stable presence of hexyl-ALA in contact to the cervical surface. This effect has been already demonstrated for the topical administration of 5-ALA thermogel (Andikyan et al, 2004) when compared to the results by Pahernik et al.(Pahernik et al, 1998). Whether the use of hexyl-ALA thermogel leads to an even improved homogeneity than ALA-thermogel needs to be determined.

5. Summary

Photodynamic therapy (PDT) following topical application of 5-aminolevulinic acid (ALA) is increasingly employed for several types of malignancies. Although 5-ALA mediated fluorescence has been proven to be effective in diagnosis and treatment of cervical intraepithelial neoplasia (CIN), results remain contradictory most likely attributed to the difficult precervical application. In order to investigate the pharmacokinetics and selectivity of ALA induced porphyrin fluorescence in CIN lesions, 24 non-pregnant women with CIN were studied. Prior to surgical conization, hexyl-ALA-thermogel in concentrations of 4mM (12 Patients) and 10mM (12 Patients) was applied to the cervix for 5 to 720 minutes. The fluorescence pattern was quantified by fluorescence microscopy and digital image analysis from cryosections. The results showed that hexyl-ALA-induced porphyrin fluorescence was stable and higher after application of 10mM hexyl-ALA. We observed a higher porphyrin fluorescence intensity within the CIN lesions (2342 ± 381 c.u.) as compared to normal adjacent epithelium (1484 ± 263 c.u.). This difference was statistically significant ($p < 0,05$). 180 to 540 minutes after application porphyrin fluorescence in dysplastic epithelium reached a maximal intensity. Tumor selectivity was highest in CIN with average tumor to normal tissue ratio of 1.6. Comparing the mean fluorescence intensity of high and low grade CIN no statistical difference could be found. Topographical fluorescence assessment by microscopy showed that maximum intensity could generally be detected in the lower layer of the epithelium, consisting of basal and parabasal cells, and gradually declined from the basal membrane to the surface of the epithelium.

Compared to studies using 5-ALA, hexyl-ALA leads to a much stronger PPIX fluorescence in dysplastic epithelium and a similar tumor selectivity. Based on these results, hexyl-ALA dissolved in Lutrol F-127 thermolabile gel seems to be a promising form for the administration. We recommend the topical application of 10mM of hexyl-ALA 180-540 minutes prior to photodynamic therapy (PDT) in CIN.

6. Zusammenfassung

Die photodynamische Therapie (PDT) nach topischer Applikation von 5-Aminolävulinsäure (5-ALA) findet zunehmenden Einsatz bei verschiedenen Tumorentitäten. Obgleich einige Studien gute Resultate mit 5-ALA in der Diagnostik und Behandlung von zervikalen intraepitheliale Neoplasie (CIN) aufweisen, bleiben insgesamt die Ergebnisse widersprüchlich. Dies ist am ehesten auf das Problem der schwierigen präzervikalen Applikation zurückzuführen. Zur Erforschung der Pharmakokinetik und der Selektivität von ALA induzierter Porphyrinfluoreszenz in CIN Läsionen wurden 24 nichtschwangere Frauen in diese ex vivo Studie aufgenommen. Vor der geplanten Konisation erfolgte die topische Applikation von Hexyl-ALA-Thermogel in einer Konzentration von 4 mM (12 Patientinnen) und 10 mM (12 Patientinnen) vor die Cervix uteri mit einem Applikationsintervall von 5 bis 720 Minuten. Die Porphyrinfluoreszenz wurde quantifiziert mittels Fluoreszenzmikroskopie und digitaler Bildanalyse von Gefrierschnitten. Die Ergebnisse zeigen, dass nach Illumination (Wellenlänge 370-430nm) eine höhere Porphyrinfluoreszenz bei 10 mM gegenüber 4 mM Hexyl-ALA erzielt wurde. In CIN-Läsionen wurde eine höhere Porphyrinfluoreszenzintensität gemessen (2342 ± 381 kal. E.) als im benachbarten normalen Epithel (1484 ± 263 kal.E.). Dieser Unterschied war statistisch signifikant ($p < 0,05$). 180 bis 540 Minuten nach topischer Applikation erzielte die Porphyrinfluoreszenz im dysplastischen Epithel eine maximale Intensität. Die höchste Tumorselektivität wurde in CIN-Läsionen mit einer durchschnittlichen Tumor-Normalgewebe-Ratio von 1,6 erzielt. Es fand sich kein statistisch signifikanter Unterschied zwischen der mittleren Fluoreszenzintensität von hochgradiger im Vergleich zu geringgradiger CIN. In der topografischen Fluoreszenzmikroskopie war jedoch die

maximale Fluoreszenzintensität in den proliferativen Basal-und Parabasalzellschichten am höchsten nachweisbar und fiel kontinuierlich zu den oberen Zellagen ab.

Verglichen mit Studien, die 5-ALA als Photosensibilisator verwendet haben, erzielte Hexyl-ALA induziertes Porphyrin eine deutlich höhere Fluoreszenzintensität im dysplastischen Epithel bei vergleichbarer Tumorselektivität. Deshalb empfehlen wir Hexyl-ALA Thermogel in einer Konzentration von 10 mM und einer Applikationszeit von 180-540 Minuten für die Photodynamische Therapie der CIN.

7. References

Andikyan V, Kronschnabl M, Hillemanns M, Wang X, Stepp H, Hillemanns P (2004)

Fluorescence Diagnosis with 5-ALA Thermogel of Cervical Intraepithelial Neoplasia.

Gynakol Geburtshilfliche Rundsch 44:31-7

Amano T, Prout JGR, Lin CW (1988)

Intratumor injection as a more effective means of porphyrin administration for photodynamic therapy. J Urol 139: 392-5

Ash D, Brown S (1993)

New drugs and future developments in photodynamic therapy. Eur J Cancer 29A: 1781-1783

Bachor R, Shea CR, Gillies R, Hasan T (1991)

Photosensitized destruction of human bladder carcinoma cells treated with chlorin e6-conjugated microspheres. Proc Natl Acad Sci USA 88 : 1580-4

Bachor R, Flotte TJ, Scholz M Dretler P, Hasan T (1992).

Comparison of intravenous and intravenous and intravesical administration of chloro-aluminium sulfonated phthalocyanine for photodynamic treatment in a rat bladder cancer model. J Urol 147 :1404-10

Barnett AA, Haller JC, Cairnduff F, Lane G, Brown SB, Roberts DJH (2003)

A randomised, double-blind, placebo-controlled trial of photodynamic therapy using 5-aminolevulinic acid for the treatment of cervical intraepithelial neoplasia. *Int J Cancer* 103: 829 – 832

Baumgartner R, Huber RM, Schulz H, Stepp H, Rick K, Gamarra F, Leberig A, Roth C(1996)

Inhalation of 5-aminolevulinic acid: a new technique for fluorescence detection of early stage lung cancer. *J Photochem Photobiol B* 36: 169-74

Benson JRC (1988)

Treatment of bladder cancer with hematoporphyrin derivatives and laser light. *Urology* 31: 13-7

Bigrigg MA, Codling BW, Pearson P, Read MD, Swingler GR (1991)

Pregnancy after cervical loop diathermy [Letter]. *Lancet* 337: 119

Bosch FX, Manos MM, Munoz N, Sherman M, Jansen AM, Peto J, Schiffman MH, Moreno V, Kurman R, Shah KV (1995)

Prevalence of human papillomavirus in cervical cancer: a worldwide perspective. International Biological Study on Cervical Cancer (IBSCC) study group. *J Natl Cancer Inst* 87: 770-80

Choo KB, Pan CC, Han SH (1987)

Integration of human papillomavirus type 16 into cellular DNA of cervical carcinoma: preferential deletion of the E2 gene and invariable retention of the long control region and the E6/E7 open reading frames. *Virology* 161: 259-61

Cullen AP, Reid R, Campion M, Lorincz AT (1991)

Analysis of the physical state of different human papillomavirus DNAs in intraepithelial and invasive cervical neoplasm. *J Virol* 65:606-12

Dougherty TJ (1987)

Photosensitizers: therapy and detection of malignant tumors. *Photochem Photobiol* 45: 879-89

Endlicher E, Knuechel R, Hauser T, Szeimies RM, Scholmerich J, Messmann H (2001)

Endoscopic fluorescence detection of low and high grade dysplasia in Barrett's oesophagus using systemic or local 5-aminolevulinic acid sensitisation. *Gut* 48: 314-6

Evander M, Frazer IH, Payne E, Qi YM, Hengst K, McMillan NA (1997)

Identification of the alpha6 integrin as a candidate receptor for papillomaviruses. *J Virol* 71: 2449-56

Gerscher S, Connelly JP, Griffiths J, Brown SB, MacRobert AJ, Wong G, Rhodes LE (2000)

Comparison of the pharmacokinetics and phototoxicity of protoporphyrin IX metabolized from 5-aminolevulinic acid and two derivatives in human skin in vivo. *Photochem Photobiol* 72: 569-74

Gerscher S, Connelly JP, Beijersbergen Van Henegouwen GM, MacRobert AJ, Watt P, Rhodes LE (2001)

A quantitative assessment of protoporphyrin IX metabolism and phototoxicity in human skin following dose-controlled delivery of the prodrugs 5-aminolaevulinic acid and 5-aminolaevulinic acid-n-pentylester. *Br J Dermatol* 144: 983-90

Goff BA, Bamberg M, Hasan T (1991)

Photoimmunotherapy of human ovarian carcinoma cells ex vivo. *Cancer Res* 51: 4762-7

Fukuda H, Battle M, Riley P (1993)

Kinetics of porphyrin accumulation in cultured epithelial cells exposed to ALA. *Int J Biochem* 25: 1407-1410.

Henderson BW, Dougherty TJ (1992)

How does photodynamic therapy work? *Photochem Photobiol* 55: 145-157

Hillemanns P, Korell M, Schmitt-Sody M, Baumgartner R, Beyer W, Kimmig R, Untch M, Hepp H (1999)

Photodynamic therapy in women with cervical intraepithelial neoplasia using topically applied 5-aminolevulinic acid. *Int J Cancer* 81: 34-38

Hillemanns P, Weingandt H, Baumgartner R, Diebold J, Xiang W, Stepp H (2000)

Photodetection of cervical intraepithelial neoplasia using 5-aminolevulinic acid-induced porphyrin fluorescence. *Cancer* 88: 2275-2282

Hollingworth RE, Lee WH (1991)

Tumor suppression genes: new prospects for cancer research. *J Natl Cancer Inst* 83: 91-6

Howley PM, Broker TR (1990)

Papillomaviruses. Wiley-Liss, New York, 1-540

Iinuma S, Farshi S, Ortel B, Hasan T (1994)

A mechanistic study of cellular photodestruction with 5-aminolaevulinic acid-induced porphyrin. *Br J Cancer* 70: 21-28

Kennedy JC, Pottier RH, Pross DC (1990)

Photodynamic therapy with endogenous protoporphyrin IX: basic principles and present clinical experience. *J Photochem Photobiol B* 6: 143-8

Kondo M, Hirota N, Takaoka T, Kajiwara M (1993)

Hemebiosynthesis enzyme activities and porphyrin accumulation in normal and hepatoma cell lines of rats. *Cell Biol Toxicol* 9: 95 - 105

Lange N, Jichlinski P, Zellweger M, Forrer M, Marti A, Guillou L, Kucera P, Wagnieres G, van den Bergh H (1999)

Photodetection of early human bladder cancer based on the fluorescence of 5-aminolaevulinic acid hexylester-induced protoporphyrin IX: a pilot study. *Br J Cancer* 80: 185-93

Lawson HW, Lee NC, Thames SF, Henson R, Miller DS (1998)

Cervical cancer screening among low-income women: results of a national screening program, 1991-1995. *Obstet Gynecol* 92: 745-52

Leunig A, Betz CS, Heinrich P, Janda P, Baumgartner R (2002)

Fluorescence staining of oral and laryngeal cancer after application of 5-aminolevulinic acid. *Laryngorhinootologie* 81: 807 –14

Loh CS, MacRobert AJ, Bedwell J, Regula J, Kransner N, Bown SG (1993)

Oral versus intravenous administration of 5-aminolaevulinic acid for photodynamic therapy. *Br J Cancer* 68: 41-51

Luesley DM, McCrum A, Terry PB, Wade ET, Nicholson HO, Mylotte MJ, Emens JM, Jordan JA (1985)

Complications of cone biopsy related to the dimensions of the cone and the influence of prior colposcopic assessment. *Brit J Obstet Gynecol* 92: 158-64

Marcus SL (1992)

Photodynamic therapy of human cancer. Proc IEEE 80: 869-89

Marti A, Lange N, van den Bergh H, Sedmera D, Jichlinski P, Kucera P (1999)

Optimisation of the formation and distribution of protoporphyrin IX in the urothelium: an in vitro approach. J Urol 162: 546-52

Mathevet P, Chemali E, Roy M, Dargent D (2003)

Long-term outcome of a randomized study comparing three techniques of conization: cold knife, laser and LEEP. Eur J Obstet Gynecol Reprod Biol 106: 214 –8

McDougall JK (1994)

Immortalization and transformation of human cells by human papillomavirus. Curr Top Microbiol Immunol 186: 101-19

Munoz N (2000)

Human papillomavirus and cancer: the epidemiological evidence. J Clin Viro 19: 1-5

Pahernik SA, Botzlar A, Hillemanns P, Dellian M, Kirschstein M, Abels C, Korell M, Mueller-Hoecker J, Untch M, Goetz AE (1998)

Pharmacokinetics and selectivity of aminolevulinic acid-induced porphyrin synthesis in patients with cervical intra-epithelial neoplasia. Int J Cancer 78:310-4

Peng Q, Berg K, Moan J, Kongshaug M, Nesland JM (1997)

5-Aminolevulinic acid based photodynamic therapy: principles and experimental research.
Photochem Photobiol 65: 235 – 251

Regula J, MacRobert AJ, Gorchein A, Buonaccorsi GA, Thorpe SM, Spencer GM, Hatfield AR, Bown SG (1995)

Photosensitisation and photodynamic therapy of oesophageal, duodenal, and colorectal tumors using 5 aminolaevulinic acid induced protoporphyrin IX- a pilot study. Gut 36: 67-75

Richart RM (1973)

Cervical intraepithelial neoplasia: a review. In: Sommers SC (ed) Pathology annual. Appleton-Century-Crofts, East Norwalk, pp 301-328

Rossi F, Campbell D, Pottier R, Kennedy J, Gudgin Dickson E (1996)

In vitro studies on the potential use of 5-aminolaevulinic acid-mediated photodynamic therapy for gynaecological tumours. Br J Cancer 74: 881-887

Schwarz E, Freese UK, Gissmann L, Mayer W, Roggenbuck B, Stremlau A, zur Hausen H (1985)

Structure and transcription of human papillomavirus sequences in cervical carcinoma cells. Nature 314:111-4

Stewart F, Baas P, Star W (1998)

What does photodynamic therapy have to offer radiation oncologists (or their cancer patients)? *Radiother Oncol* 48:233-48

Stummer W, Novotny A, Stepp H, Goetz C, Bise K, Reulen HJ (2000)

Fluorescence-guided resection of glioblastoma multiforme by using 5-aminolevulinic acid-induced porphyrins: a prospective study in 52 consecutive patients. *J Neurosurg* 93: 1003 – 13

Svanberg K, Andersson T, Killander I, Stenram U, Andersson-Engels S, Berg R, Johansson J, Svanberg S (1994)

Photodynamic therapy of non-melanoma malignant tumours of the skin using topical δ -amino levulinic acid sensitisation and laser irradiation. *Br J Dermatology* 130: 743-5

Ustav E, Ustav M (1998)

E2 protein as the master regulator of extrachromosomal replication of the papillomaviruses. *Papillimavirus Rep* 9: 145-50

Ward P, Coleman AD, Malcolm DB (1989)

Regulatory mechanisms of the papillomaviruses. *Trends Genet* 5: 92-8

Xiang W, Weingandt H, Liessmann F, Klein S, Stepp H, Baumgartner R, Hillemanns P (2001)

Photodynamic effects induced by aminolevulinic acid esters on human cervical carcinoma cells in culture. *Photochem Photobiol* 74:617-23

Wierrani F, Kubin A, Jindra R, Henry M, Gharehbaghi K, Grin W, Soltz-Szotz J, Alth G, Gruneberger W (1999)

5-Aminolevulinic acid-mediated photodynamic therapy of intraepithelial neoplasia and human papillomavirus of the cervix - a new experimental approach. *Cancer Detect Prev* 23: 351-5

Zaak D, Hungerhuber E, Schneede P, Stepp H, Frimberger D, Corvin S, Schmeller N, Kriegmair M, Hofstetter A, Knuechel R, Knochel R (2002)

Role of 5-aminolevulinic acid in the detection of urothelial premalignant lesions. *Cancer* 95, 1234 – 8

zur Hausen H (1991)

Human papillomaviruses in the pathogenesis of anogenital cancer. *Virology* 184: 9-13

zur Hausen H (1996)

Papillomavirus infections-a major cause of human cancers. *Biochem Biophys Acta Rev Cancer* 1288: F55-F78

8. Acknowledgement

I am very grateful to my supervisor **PD Dr. med. Peter Hillemanns** for providing the opportunity to work in the Oncology Research Laboratory of the Department of Obstetrics and Gynecology, Klinikum Großhadern, LMU, Munich. I wish to thank him for his thematic and personal support.

I thank Dr. Herbert Stepp of Laser Research Laboratory, Klinikum Großhadern, LMU for important hardware adjustments and valuable comments on the interpretation of the data.

I would like to thank Marianna Fileki, Magret Felber, Martina Rahmeh and Dieta Egner for their kind help and encouragement, for all the talks and laughs we had together. These friendships were a strong support during my work in the research laboratory in Germany.

And finally, this work was not possible without the support and encouragement of my husband Hongwei and my son Bob.

9. Curriculum Vitae

Name: Xiuli Wang

Date of Birth: 15 April 1964

Nationality: Chinese

Postal Address: Heighhofstr. 70 / 014, 81377 Munich, Germany
Tel: 0049 89 70942324 (home), 0049 89 70954775 (lab)

Email: Xiuliwang2001@yahoo.com.cn

Education:

1983: M.D. Luoyang Medical college, Major in Medicine, P.R.China.

1995: M.S.(Master) Institute of Dermatology and Venereology, Tongji Medical University, Wuhan, P.R. China

Since March 2003, study for the Doctoral degree in human medicine, Department of Obstetrics and Gynecology, Klinikum Großhadern, University of Munich, Munich, Germany

Academic appointments:

May/2000-Feb/2003: Assistant-Chief-Doctor, Shanghai Skin and STD Hospital, Shanghai, P.R. China

July/1995-April/2000: Physician-in-Charge, Dermatology and Venereology, the Affiliated People's Hospital, Wuhan University, Wuhan, P.R. China

1985-1992: Resident Physician, Division of Dermatology and Venereology, Jiaozhuo City Hospital, Henan Province

List of publications:

1. **Wang XL**, Xu SZ, He Ping. Detection of four pathogens in patients with sexually transmitted diseases by PCR. The Chinese Journal of Dermatovenereology, 1996; 10(6): 352
2. **Wang XL**, Xu SZ, Xiong LY. Statement of bcl-2 and Fas proteins in lesions of basal cell carcinoma and squamous cell carcinoma. Chinese Journal of Dermatology, 1997; 30(6): 371
3. Xu SZ, Wang HW and **Wang XL**. Statement of P53 and P21 protein in lesions of psoriasis. Chinese Journal of Dermatology, 1998; 31(2): 105
4. **Wang XL**, Xu SZ, Xiong LY. A primary study of apoptosis in keratinocytes of skin lesions from patients with discoid and systemic lupus erythematosus. Chinese Journal of Dermatology, 1998; 31(5): 319

5. Wang HW, **Wang XL**, Zhang G. Statement of PCNA, P21 and P53 protein in skin cancer. Chinese Journal of Dermatology, 1998; 31(6): 380.
6. **Wang XL**, Xu SZ, Xiong LY, He P. Statement of Fas and Fas-L in the skin lesions of systemic lupus erythematosus. Chinese Journal of Dermatology, 1999; 32(1): 6
7. Xu SZ, **Wang XL**, Zhang CR. δ -Aminolevulinic acid-photodynamic therapy for cutaneous basal cell carcinoma and squamous cell carcinoma. Chinese Journal of Dermatology, 1999; 32(3): 185
8. Wang HW, **Wang XL**. Statement of PCNA in Squamous Cell Carcinoma and γ -IFN Influence on Proliferative Activity of Hep-2 Cells in Vitro. Journal of Clinical Dermatology, 1999; 28(3):165
9. Wang HW, Zhang G and **Wang XL**. Statement of PCNA and Fas in Condyloma Acuminatum. Chinese Journal of Dermatology, 2000; 33(3): 180
10. Wang HW, **Wang XL**. Expression of p53, p21 and PCNA in condyloma acuminatum. Central China Medical Journal, 2001; 25(2): 59
11. **Wang XL**, Xu SZ, Lu L. Expression of costimulatory molecules on peripheral blood lymphocytes in patients with systemic lupus erythematosus. The Chinese Journal of Dermatovenereology. 2002; 16(2): 81
12. Xu SZ, **Wang XL**, Xu W, Zhang CR. Evaluation of photodynamic therapy of skin cancers with 5-aminolevulinic acid. Chinese Medical Journal. 2002; 115(8): 1141.
13. Co-edited Immunology and Dermatology. Published by Hubei Science and Technology Publishing House, Wuhan, China
14. Andikyan V, Kronschnabl M, Hillemanns M, **Wang X**, Stepp H, Hillemanns P. Fluorescence diagnosis with 5-ALA thermogel of cervical intraepithelial neoplasia. Gynol Geburtshilfl Rundsch. 2004; 44(1): 31-7.
15. **Wang XL**, Wang HW, Wang HS, Xu SZ, Liao KH, Hillemanns P. Topical 5-ALA photodynamic therapy for the treatment of urethral condylomata acuminata. Bri J Dermatol. In press.

11. Study Protocol

**Antrag an die Ethikkommission
des Fachbereichs Medizin
der Ludwig-Maximilians-Universität
München**

**Klinische Phase I - Studie: Pharmakokinetische,
fluoreszenzmikroskopische Studie mit
Video-Imaging zur Gewebeaufnahme und -verteilung von
Hexyl-Aminolaevulinsäure bei zervikaler intraepithelialer
Neoplasie (CIN 1 bis 3)**

**PD Dr. med. Peter Hillemanns, Oberarzt
Klinik und Poliklinik für Geburtshilfe und Frauenheilkunde
Universität München - Klinikum Großhadern**

München 24.8.2002

1. Formalia des Antrages

1.1 Antragsteller

PD Dr. med. Peter Hillemanns, Oberarzt
Klinik und Poliklinik für Frauenheilkunde und Geburtshilfe
Universität München - Großhadern
Marchioninistrasse 15
81377 München, Germany
Tel: ++49 89 7095-0
Fax: ++49 89 7095-4697
Mail: peter.hillemanns@med.uni-muenchen.de

1.2 Titel des Forschungsvorhabens:

Klinische Phase I - Studie: Pharmakokinetische, fluoreszenzmikroskopische Studie mit Videoimaging zur Gewebeaufnahme und -verteilung von Hexyl-Aminolaevulinsäure bei zervikaler intraepithelialer Neoplasie (CIN 1-3)

1.3 Ausbildungsdaten und Prüferfahrungen des Antragstellers:

- Facharzt und Oberarzt der Frauenklinik Großhadern, München
 - Curriculum vitae mit Publikationsverzeichnis zu diesem Gebiet anbei
 - Prüferfahrung des Antragstellers:
- Klinische Phase 2 - Studie: MX6-16: MX6 in Prentif™ vs. Femcap Kombination bei Patientinnen mit hochgradiger intraepithelialer Neoplasie (CIN 2/3): Leiter der Klinischen Prüfung für Deutschland
 - Randomisierte, plazebokontrollierte klinische Studie der ersten Anwendung von HPV 16 L1E7 CVLP-Impfung bei Zervixdysplasie (CIN 2/3)
 - Multizentrische, offene klinische Studie zu Imiquimod bei Genitalwarzen (IMIQ 1294), Firma 3M Medica (1997)
 - Multizentrische klinische Studie zur adjuvanten Therapie mit Aldara 5% nach Laserablation bei Kondylomen, Firma 3M Medica (1998)
 - Multizentrische Studie (Phase II) „Photodynamische Lasertherapie von Hautmetastasen des Mammakarzinoms mit SnET2“, Pharmacia (1996)

1.4 Studiendesign: Monozentrische, klinische Phase I Studie

1.5 Ärztlicher Leiter der Studie

PD Dr. med. Peter Hillemanns, Oberarzt

1.5 Schriftliche Zustimmung des verantwortlichen Leiters der klinischen Einrichtung:

Als Direktor der Klinik und Poliklinik für Frauenheilkunde und Geburtshilfe der Universität München - Großhadern, gebe ich zur Durchführung des geplanten Forschungsprojekts

Klinische Phase I - Studie: Pharmakokinetische, fluoreszenzmikroskopische Studie mit Videoimaging zur Gewebeaufnahme und -verteilung von Hexyl-Aminolaevulinsäure bei zervikaler intraepithelialer Neoplasie (CIN 1-3)

in meiner Klinik meine Zustimmung.

Prof. Dr. H. Hepp
Direktor der Klinik

München, 26.08.2002

1.6 Finanzierung des Forschungsvorhabens durch

Das vorliegende Studienprotokoll entspricht einer monozentrischen Phase I Prüfung. Teilfinanzierung durch Fa. Photocure ASA, Hoffsvæien 48, 0377 Oslo.

Hexyl-Aminolävulinsäure wird von der Firma Photocure, Norwegen, zur Verfügung gestellt.

Die Patientendokumentation wird vom Antragsteller durchgeführt.

1.7 Abgeschlossener Versicherungsschutz für Probanden und Patientinnen

Patientenversicherung gemäß § 40, 41 wurde bei der Allianz unter folgender Versicherungspolicennummer abgeschlossen: ?

1.8 Erklärung der berücksichtigten Grundsätze der Deklaration von Helsinki liegt bei.

1.9 Erklärung über die Einhaltung der Bestimmungen des Arzneimittelgesetzes

liegt bei: Die Vorschriften des AMG (§ 40, 41 und 67 AMG) werden eingehalten werden.

2. Spezielle Angaben zum Forschungsvorhaben

2.1 Fragestellung (Ziel der Studie, Grundlagen, Bedeutung)

Ziele der Studie sind

1. Untersuchung der Aufnahme von Hexyl-Aminolävalinsäure in zervikale intraepitheliale Neoplasien zur Prüfung der Eignung von Hexyl-Aminolävalinsäure zur Behandlung dieser Neoplasien mit Photodynamischer Therapie
2. Ermittlung der günstigsten Anwendungsdauer und Konzentration von Hexyl-Aminolävalinsäure (4 mM, 10 mM)

Grundlagen

Der Gebärmutterhalskrebs ist weltweit gesehen die zweithäufigste Krebserkrankung der Frau (WHO 1990). Er entsteht über seine Präkanzerose, die zervikale intraepitheliale Neoplasie (CIN). Diese verläuft über drei Schweregrade, CIN 1 bis CIN 3, bevor sie mit einer Latenz von 10 Jahren und mehr in das invasive Plattenepithelkarzinom übergehen kann. Die Prävalenz der CIN zeigte in Westeuropa und den USA eine ständige Zunahme in den letzten zwei Dekaden und liegt bei ca. 3-5%. Es sind vorwiegend Frauen im reproduktiven Alter zwischen 25 und 40 Jahren betroffen. Die Krebsvorsorge in der westlichen Welt - mit zytologischen Kontrollen im Stadium CIN 1 und 2 (Pap III D) und chirurgischer Therapie im Stadium CIN 3 (Pap IVa) - bewirkte einen deutlichen Rückgang der Zervixkarzinom-mortalität um ca. 40%.

Die Infektion mit bestimmten Typen von Humanen Papillomviren (HPV) stellt den wesentlichen ursächlichen Faktor in der Entwicklung des Gebärmutterhalskrebses dar. In einer weltweiten Untersuchung an fast 1000 Zervixkarzinomen konnte in 99,7% HPV DNA mittels Polymerasekettenreaktion (PCR) nachgewiesen werden. Angesichts dieser Daten muss auch in einem vergleichbar hohen Prozentsatz die Prävalenz von HPV bei den Dysplasien angesetzt werden. In klinischen Studien liegt der Nachweis von HPV bei CIN 2/3 in Abhängigkeit vom Testverfahren bei 85-100%. Bei gesunden Frauen liegt die Prävalenz altersabhängig zwischen 7-20%.

Natürlicher Verlauf: Ungefähr 15% bis 20% der unbehandelten Dysplasien der Portio uteri (CIN 1-2) gehen in eine schwere Dysplasie über und ungefähr 5 bis 10% in ein invasives Zervixkarzinom nach einem Intervall von 10-20 Jahren. Die mittlere Remissionsrate der CIN 1-2 liegt bei ca. 30-50% und rechtfertigt bei Erstdiagnose das kontrollierende Zuwarten über einen Zeitraum von ein bis zwei Jahren. Während dieses Zeitraums müssen die Patientinnen 3-6 monatlich gynäkologisch untersucht werden mit Entnahme von Zytologie, Kolposkopie (Lupenbetrachtung der Zervix) und evtl. gezielten Knipsbiopsien der Portio uteri bzw. endozervikale Curettage. Diese engmaschigen Kontrollen stellen für die Patientin häufig auch eine erhebliche psychische Belastung dar. Bei der schwergradigen Dysplasie (CIN 3) ist in 30-50% mit einer Progression zum invasiven Karzinom zu rechnen. In dem Stadium CIN 3 wird die chirurgische Therapie empfohlen. Allerdings nicht in der Schwangerschaft. Bei CIN 3 in graviditate wird unter 2-monatigen Kontrollen die Geburt abgewartet und erst 2-3 Monate postpartal die Therapie durchgeführt.

Therapie: Bei Persistenz oder Progression der CIN ist eine Behandlung indiziert. Die im deutschen Sprachraum vorherrschende Technik zur Behandlung der CIN ist die klassische Messerkonisation. Mehrere Studien konnten jedoch belegen, dass diese Methode mit einem statistisch signifikant erhöhten Risiko für Zervixinsuffizienz und Frühgeburtlichkeit einhergeht. Ein weiteres Problem ist die erhöhte perioperative Blutungsrate. Diese Nachteile weisen destruirende Methoden wie CO₂-Lasertherapie, Kryotherapie oder Kauterisation nicht auf. Diese Verfahren konnten sich allerdings nicht etablieren.

Mit photodynamischer Therapie unter Verwendung von 5-Aminolaevulinsäure können prinzipiell Dysplasien mit einer begrenzten Dicke, wie bei den zervikalen Dysplasien anzutreffen, behandelt werden. Die Wirksamkeit dieser Therapie für zervikale Dysplasien ist zu prüfen. Es ist eine sehr grosse Akzeptanz seitens unserer Patientinnen zu erwarten, da die bisherige Alternative allein ein chirurgisches Verfahren mit Destruktion der Portio uteri darstellt.

Studienpräparat: Hierbei handelt es sich um eine 4 mM bzw. 10 mM Lösung von Hexyl-Aminolaevulinsäure. Hexyl-Aminolävulinsäure ist ein Ester der 5-Aminolävulinsäure (5-ALA), das als hydrophile Substanz häufig nur in oberflächliche Zellschichten aufgenommen wird und sich inhomogen verteilt. Hexyl-Aminolävulinsäure ist wesentlich lipophiler und führt zu einer bis zu 100-fach höheren Konzentration des Photosensibilisators Protoporphyrin IX, der aus ALA gebildet wird. Intrazellulär wird die Esterbindung gespalten, die Wirksubstanz ist ALA. Bei über 250 Patienten wurden bereits 4 – 16 mM Lösungen von Hexyl-ALA in die Blase instilliert zur Fluoreszenz-Zystoskopie, ohne daß es dabei zu Nebenwirkungen kam. Entsprechende klinische Erfahrungen liegen in der Klinik für Urologie der LMU (Direktor: Prof. Dr. A. Hofstetter) vor. Nach unseren in vitro Daten liegt auch ein weiterer Vorteil in der kurzen Konversionszeit von H-ALA zu Protoporphyrin IX (W. Xiang, Photochem Photobiol 2001).

Bisherige Ergebnisse: Es ist seit längerem bekannt, dass Photodynamische Therapie (PDT) mit ALA die Dysplasien zur Abheilung bringen kann, z.B. im Ösophagus und im Bereich der Vulva. Die Eignung von PDT mit ALA wurde auch für zervikale Dysplasien untersucht. In einer Studie des Antragstellers (Hillemanns et al., 1999, Int.J.Cancer 81, 34-38) mit Anwendung einer flüssigen ALA-Präparation und Zervixkappe wurde gefunden, dass zervikale Dysplasien deutlich verkleinert, aber nicht immer eliminiert werden konnten. Es stellt sich die Frage, ob mit einer veränderten Pharmakokinetik durch Veresterung von ALA mit eventuell höheren Gewebekonzentration von 5-ALA ein größerer therapeutischer Effekt zu erreichen ist. Für Zellkulturen von Cervix-Karzinom-Zellen wurde eine beschleunigte Aufnahme in die Zelle bereits nachgewiesen (Xiang W., Hillemanns P. et al.). Die Methodik zur Untersuchung der ALA-Gewebeaufnahme, wie z.B. die für die vorliegende Studie vorgesehene Fluoreszenzmikroskopie von entnommenem Gewebe, ist beim Antragsteller etabliert (Pahernik et al., 1998, Int.J.Cancer 78, 310-314). Eine ähnliche Studie wie diese geplante Studie wird derzeit mit dem Präparat 5-Aminolävulinsäure in Verbindung mit einer Transportersubstanz „Thermogel“ zur Optimierung der lokalen Applikationstechnik (EK Projekt 127/01 und 128/01) durchgeführt.

2.2 Studienart

Pharmakokinetik-Studie

2.3 Untersuchungsdesign

Es handelt sich um eine prospektive Studie, die die Sicherheit und Pharmakokinetik von verschiedenen Konzentrationen und Applikationszeiten von Hexyl-ALA bei Patientinnen mit cervikaler intraepithelialer Neoplasie beurteilt. Die Routinediagnostik mit Kolposkopie, Zytologie, HPV-DNA Test und kolposkopisch gezielter Knipsbiopsie für die Histologie wird vor der Studien-Fluoreszenzdiagnostik durchgeführt.

Hexyl-ALA wird als eine Lösung in Konzentrationen von 4mM und 10mM aufgetragen, beginnend mit kurzen Inkubationszeiten von 5 min, 10 min, 30 min, 60 min und 100 min – in Abhängigkeit vom schwer exakt planbaren Operationszeitpunkt (Logistik, Narkose etc.). Nach Vorlage von in vitro Daten für das Zervixepithel scheinen kurze Inkubationsintervalle ausreichend zu sein. Im Rahmen der klinisch indizierten Konisation erfolgt präoperativ ein Fluoreszenz-Imaging. Am entnommenen Konisat wird dann neben der Routinehistologie die Fluoreszenzmikroskopie (entspr. der im Hause erfolgten Studie von Pahernik et al., Int. Journal of Cancer, 78:310, 1998) durchgeführt. Anhand der fluoreszenzmikroskopischen Daten sind längere Inkubationszeiträume gegebenenfalls notwendig.

2.4 Diskussion der ethisch-rechtlich relevanten Probleme des Studiendesigns:

Die vorliegende Studie soll mit Patientinnen durchgeführt werden, für die auf Grund etablierter, durch die vorliegende Studie nicht beeinflusster Kriterien eine Konisation zur Therapie von zervikalen Dysplasien vorgesehen ist. Die vorliegende Studie beinhaltet keine Umstände, auf Grund derer eine relevante Beeinflussung der geplanten Konisation anzunehmen wäre.

Es ist weiterhin nicht anzunehmen, dass die geplante Anwendung von Hexyl-ALA zu Unverträglichkeitserscheinungen oder Beschwerden führen wird, da keine Photodynamische Therapie stattfinden soll, die durch die dabei stattfindende Anwendung energiereichen Lichts erst relevante Wirkungen von Hexyl-ALA auf das Gewebe erzeugen würde. Die lokale Verträglichkeit von 5-ALA ohne Verbindung mit PDT ist durch toxikologische Untersuchungen etabliert. Methyl-ALA, ein weiteres Ester-Derivat von 5-ALA ist von der Europäischen Kommission zugelassen.

Von der hier geplanten lokalen Anwendung von Hexyl-ALA in einem kleinen Areal ist keine relevante systemische Resorption zu erwarten. Entsprechend sind keine Nebenwirkungen durch Verteilung in andere Gewebe zu erwarten, wie beispielsweise Sensibilisierung der Haut gegenüber Sonneneinstrahlung, wie sie bei systemischer Gabe von ALA-Derivaten in zeitlich begrenztem Ausmaße vorkommen kann. Eine ähnliche Studie wie diese geplante Studie wird derzeit mit dem Präparat 5-Aminolävulinsäure in Verbindung mit einer Transportersubstanz „Thermogel“ zur Optimierung der lokalen Applikationstechnik (EK Projekt 127/01 und 128/01) durchgeführt.

2.5 Zustimmungsfähigkeit – mutmasslicher Wille der Patientin.

In dieser Studie werden nur erwachsene und zustimmungsfähige Patientinnen eingeschlossen.

2.6 Allfällige Honorierung von Probanden und Patienten.

Es ist keine Honorierung der Patientinnen vorgesehen.

2.7 Rahmenbedingungen des Studiendesigns

Einschlusskriterien:

- Histologisch nachgewiesene CIN 1 bis 3
- Kolposkopie: Transformationszone vollständig einsehbar
- Zytologie: Pap-Resultate vereinbar mit CIN 1-3 (Pap IIID bis IVb)
- Verwendung einer zuverlässigen Verhütungsmethode (Verhütungsmittel in oraler, injizierter oder implantierter Form) falls Patientin vor der Menopause steht, ihre Postmenopause noch keine 2 Jahre her ist oder sie nicht operativ sterilisiert ist.
- Unterzeichnete Einverständniserklärung

Ausschlusskriterien:

- Nicht volljährig
- Entfernung aller CIN 1-3 Läsionen durch Screening-Biopsie (nachgewiesen durch entsprechende Kolpophotographien)
- Schwangerschaft oder Laktation, positiver Urin-Schwangerschaftstest bei der Screeninguntersuchung (Test notwendig bei nicht sterilisierten und prä- und perimenopausalen Patientinnen)
- Toxisches Schock-Syndrom, bekannte Überempfindlichkeit auf Hexyl-ALA
- Entzündungen in Gebärmutter oder Vagina mit klinischen Symptomen
- Menstruation hat begonnen oder wird innerhalb von zwei Tagen nach Studieneintritt erwartet.
- Geburt innerhalb von zehn Wochen vor Studieneintritt oder Fehlgeburt innerhalb von sechs Wochen vor Studieneintritt.
- Verwendung eines Intrauterinpeessars, der Patientin im gebärfähigen Alter, die kein anderes Verhütungsmittel nimmt bzw. nehmen kann.
- Klinisch bedeutsame abnorme Laborbefunde in Routineblutabnahme:
 - --Transaminasen \geq 2fache normale Obergrenze
 - --Alkalische Phosphatase \geq 2fache normale Obergrenze
 - --Bilirubin, gesamt \geq 2,0 mg/100 ml
 - --Kreatinin \geq 2,0 mg/100 ml
 - --Glucose \geq 180 mg/100 ml

Auswertung: Die Studiendaten inklusive Fotografien der Zervix, histologische und zytologische Ergebnisse sowie HPV-Resultate werden beim ärztlichen Leiter der Studie ausgewertet.

Nachkontrollen nach der Studie :

Wie an unserer Klinik üblich, werden Patientinnen mit einer Dysplasie oder im Z. n. Konisation alle 3-6 Monate zur Beobachtung einbestellt.

2.8 Aufklärungsschreiben und Einverständniserklärung (Informed consent)

liegt anbei.

2.9 Vertrauensschutz, Datenschutz liegt anbei

2.10 Änderungen des Studienprotokolls werden der Ethikkommission mitgeteilt.

2.11 Aufwandsentschädigung keine