

An Epizootic of Infectious Hepatopancreatic and Lymphoid Organ Necrosis Disease in Cultured *Penaeus monodon*: A Case Study

K.K. VIJAYAN, K.V. RAJENDRAN, S.V. ALAVANDI
and K. ALAGARSWAMI

Abstract

Shrimp diseases of viral origin have caused large production losses worldwide. This paper presents a case study of shrimp epizootic disease, covering an area of 1 050 ha in Andhra Pradesh, India. The disease struck shrimp farms in the area in July 1994. Samples from 26 shrimp farms were studied in the laboratory, and the pattern of the disease and of mortality recorded. The disease was classified as infectious hepatopancreatic and lymphoid organ necrosis disease (IHLN).

Introduction

The shrimp farming industry in India recorded phenomenal growth during 1987-1994 (FAO/NACA 1995), but the incidence of disease also increased proportionately, casting a shadow over the future of the industry. Worldwide, shrimp diseases of viral origin have been observed to cause most of the production losses and Indian shrimp farming is no exception.

In India, shrimp epizootic disease was first seen from July to September 1994, when it struck the shrimp farms located along the Kandaluru creek basin in Nellore district of Andhra Pradesh, covering an area of about 1 050 ha. It inflicted widespread mass mortality. The farms in that area range from 1 to 50 ha in size and have been in operation since 1989. Estimates indicate that 60-70% of the area was under semi-intensive culture, while the rest was under extensive culture with *Penaeus monodon* (90%) and *P. indicus* (10%) as candidate species. The stocking densities ranged from 5 to 30 post-larvae (PL)/m² with production rates ranging from 1 to 6 t/ha/crop.

Disease Outbreak and Mortality

The outbreak of a virulent shrimp disease was noticed in the second week of July 1994 in the middle portion of the creek at Pudiparthi. Occurring suddenly, it spread rapidly in both directions within 3-5 days of onset of the disease and more than 90% of the stock in the farms was lost. Treatment with antibiotics and disinfectants was not successful. The loss in production was estimated at about 350 t of shrimp. The disease prevailed in a virulent form from the second week of July to the end of September 1994 and faded by October 1994. This paper presents details of the epizootic.

Methodology

The shrimp farms were surveyed during and after the disease outbreak and samples were collected for investigation from 26 shrimp farms. Detailed laboratory studies were carried out to examine the exact etiological agent and microscopic pathology.

Exoskeleton with epidermis, gills, hepatopancreas, stomach, heart, intestine and lymphoid organs were fixed in Davidson's fixative and processed for paraffin sectioning (Bell and Lightner 1988). Sections were stained with haematoxylin and eosin. For haemocyte studies, haemolymph was drawn from the heart. A thin film of haemolymph was prepared on a clean glass slide, air dried and stained with Giemsa (Nash et al. 1993; Supamattaya et al. 1994).

Bacteriological Analysis

Moribund shrimp were collected from the ponds. The carapace was disinfected with 70% ethanol and haemolymph was then drawn from the heart. The haemolymph samples were inoculated on to Zobells' Marine Agar 2216 (ZMA) and Thiosulphate Citrate Bile Salts Sucrose (TCBS) Agar. The plates were incubated at 30°C and observed for 4 days for bacterial growth. Morphologically distinct colonies were isolated on ZMA and identified by their biochemical characteristics (Baumann and Schubert 1984).

Disease Induction Studies

Challenge trials were conducted on healthy *P. monodon* (12-16 g in size) by injecting 0.1 ml pure culture of *Vibrio alginolyticus* (3.3×10^6 cfu/ml) isolated from the moribund shrimp into the abdominal musculature of the shrimps. Similarly, infection trials were conducted using extract of hepatopancreas of moribund *P. monodon* filtered through 0.45 mm membrane. Filtrates were injected into the abdominal muscle of healthy *P. monodon* at 0.1% body weight. Twenty shrimps were used in each treatment and those injected with sterile seawater served as the control. Experimental animals were maintained as groups in separate fiber glass tanks with 250-l seawater (salinity 28-32 ppt, temperature 27-30°C) with proper aeration and water exchange (50% daily). Shrimps were fed daily with 40% protein pelletized feed at 8% body weight. Unused feed and fecal matters were removed daily. The experiment was conducted for a period of 10 days.

Results and Discussion

The disease affected the crops of culture duration ranging from 60 to 120 days and the shrimps weighed from 3 to 28 g. Gross signs displayed by the diseased shrimp included: light yellow cephalothorax (30%), pinkish cephalothorax (13%), slight reddish

discoloration of the body and appendages, empty gut, lethargy, poor escape reflex, surface fouling by epicomensal, secondary vibriosis and mortality. Dead shrimps were found scattered all over the pond bottom. Many of the affected shrimp appeared clinically normal. However, dissection revealed atrophied hepatopancreas with melanized streaks. The notable observation was that *P. indicus* cultured along with *P. monodon* in the same pond was refractory to the disease. Haemocytes of the affected shrimp did not show any apparent abnormality in structure. Except for the *Zoothamnium* fouling, wet mount preparation and histological sections of gills did not show any pathological manifestations.

The most prominent feature of the disease was the acute damage observed in the hepatopancreas, manifested by multifocal necrosis of the tubule epithelium marked by haemocytic infiltration and encapsulation resulting in melanization (Fig. 1). Densely stained, globular, basophilic bodies were observed in the tubular epithelium and interstitial cells of the hepatopancreas (Fig. 2). Some (15%) of the hepato-pancreas sections showed typical eosinophilic occlusions of Monodon Baculo Virus (MBV). Another noticeable observation in the hepatopancreas sections was the presence of many filamentous nonseptate structures similar to the

filamentous bacteria in the lumen of the tubules (Fig. 3).

Lymphoid organ showed marked necrosis associated with degeneration of the stromal matrix cells (Fig. 4). The necrotic areas of the lymphoid organ were characterized by the presence of colonies of rod-shaped, gram negative bacteria. Densely stained, basophilic, globular bodies were also present in the sections.

The mortality pattern, external signs of infection (yellow cephalothorax) and a few histopathological changes of the present disease suggested resemblance to the Yellow Head Disease (YHD) in the black tiger shrimp reported by Boonyaratpalin et al. (1993) and Lu et al. (1994). The bodies present in the lymphoid organ also showed resemblance to the viral inclusions reported in cases of YHD. Nash et al. (1993) and Supamattaya et al. (1994) reported that YHD could be easily diagnosed by studying the haemocytes, and wet and haematoxylin-stained gills. However, in the present case, haemocytes were normal and did not show any abnormal characteristic of YHD. Further, the prominent necrotic changes in the hepatopancreas and the absence of pathological changes in the gills indicated that the disease clearly differed from YHD. The exoskeletal surface of the affected shrimp did not show any white spots or patches. Moreover, characteristic histological observations of white spot disease such as the presence of eosinophilic/basophilic inclusions in ectodermal and mesodermal tissues like subcuticular epidermis, gills and stomach (Takahashi et al. 1994; Wongteerasupaya et al. 1995) were absent ruling out the presence of the white spot disease virus (SEMBV).

Nevertheless, the typical histopathological changes in the hepatopancreas strongly resembled the necrotizing hepatopancreatitis in *P. vannamei* (Lightner and Redman 1994) but other features of the infection were not in accordance with this. Pathogenic bacterium, *Vibrio alginolyticus*, could be isolated from the infected shrimp, and when healthy *P. monodon* were challenged using this

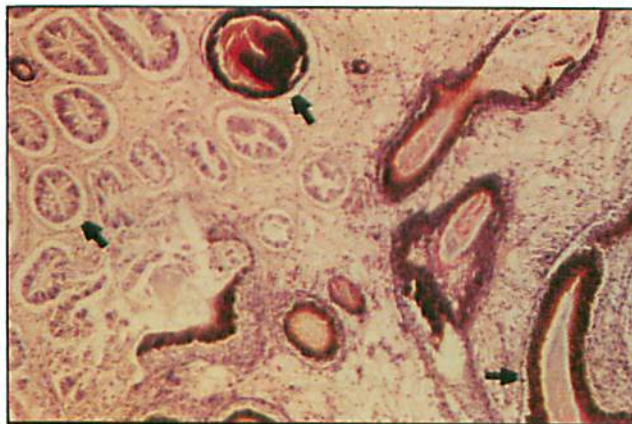

Fig. 1. Section of hepatopancreas showing extensive necrosis, haemocytic infiltration, encapsulation and melanization (arrow). (H&E, X200).

Photos by KK Vijayan et al.

bacteria, the shrimp developed typical symptoms of vibriosis similar to the observation of Nash et al. (1992), resulting in low level mortality. They did not show any symptoms of the present disease. At the same time, in the challenge test using infected extracts of hepatopancreas, *P. monodon* started dying 48 hours after inoculation and all shrimps died within eight days (Table 1).

Filamentous bacteria observed in the hepatopancreas of *P. monodon* resembled *Leucothrix*, but differed by being nonseptate; pathogenicity of this bacterium is reported to be minimal (Johnson 1983). Although a few shrimp showed moderate infection of MBV, presence of this epizootic virus in Indian shrimp farms (Vijayan et al. 1995) was not a constant occurrence in all samples. Considering the peculiar host specificity to *P. monodon*, the presence of basophilic globular structures resembling viral inclusion bodies in the hepatopancreas and lymphoid organ, sudden and mass mortality, and the total failure of antibiotic treatment, allow us to hypothesize that the primary causative organism might be a virus which acted as a predisposing factor for the severe secondary bacterial infection resulting in the large-scale mortality.

The present disease therefore, is, presumptively being named infectious hepatopancreatic and lymphoid organ necrosis disease (IHLN).

Acknowledgment

The authors are grateful to the staff of the shrimp farms for their help in providing facilities and specimens.

References

- Baumann, P. and R.H.W. Schubert. 1984. Family II, Vibrionaceae, p. 516-550. In N.R. Krieg and J.G. Holt (eds.) Manual of systemic bacteriology, Vol. I. Williams and Wilkins, Baltimore.
- Bell, T.A. and D.V. Lightner. 1988. A handbook of normal penaeid shrimp histology. World Aquacult. Soc. 114 p.
- Boonyaratpalin, S., K. Supamattaya, J. Kasornchandra, S. Direkbusaracom, U. Aekpanithanpong and C. Chantachooklin. 1993. Non-occluded

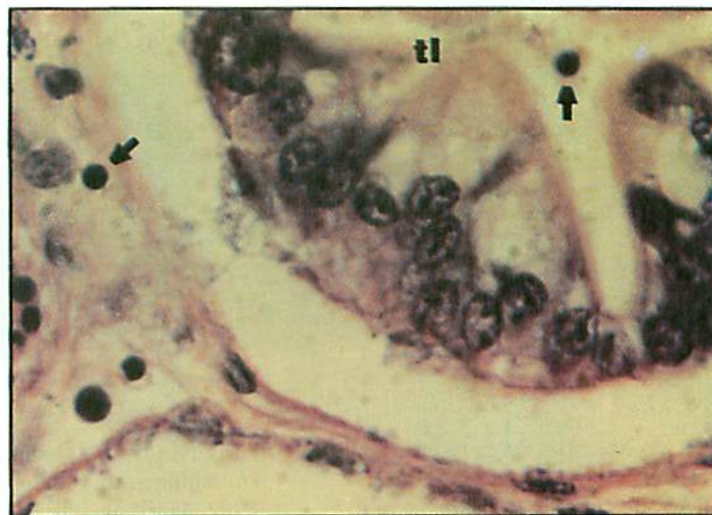


Fig. 2. Section of hepatopancreas showing deeply stained globose basophilic bodies (arrow). tl: tubular lumen (H&E, X1000).

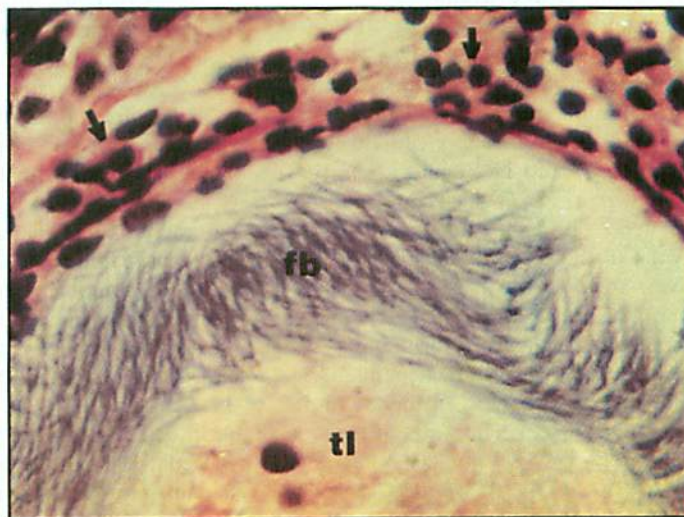


Fig. 3. Section of hepatopancreas showing filamentous, non-septate structures (fb), haemocytic infiltration (arrow). (H&E, X1000).

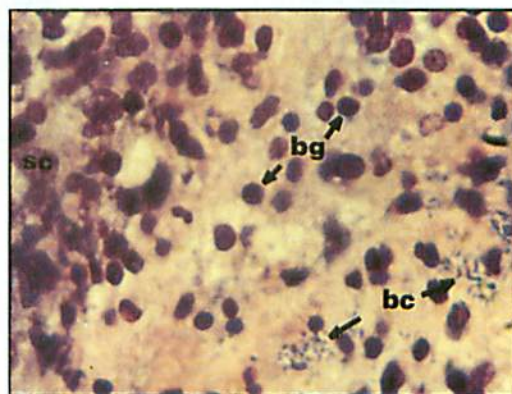


Fig. 4. Section of lymphoid organ showing degeneration of stromal matrix cells (sc), basophilic globose bodies (bg) and colonies of bacteria (bc). (H&E, X1000).

Photos by KK Vijayan et al.

Table 1. Mortality of healthy *P. monodon* upon challenge with *V. alginolyticus* isolate and filtrate of hepatopancreas of IHLN infected moribund *P. monodon*.

Sample	Cumulative mortality (%) ^a									
	Days post infection									
1. <i>V. alginolyticus</i>	0	5	5	15	15	20	20	25	30	30
2. Hepatopancreatic extract (filtrate)	0	0	35	45	60	70	90	100	-	-
3. Sterile seawater (control)	0	0	0	0	0	0	5	5	5	5

^a20 healthy shrimps (12-16 g size) were used in each treatment.

- baculo-like virus, the causative agent of yellow head disease in the black tiger shrimp (*Penaeus monodon*). J. Fish. Pathol. 28:103-109.
- FAO/NACA. 1995: Regional Study and Workshop on the Environmental Assessment and Management of Aquaculture Development. TCP/RAS/2253 NACA No. 1, 492 p. Network of Aquaculture Centres in Asia-Pacific, Bangkok, Thailand.
- Johnson, P.T. 1983. Diseases caused by viruses, rickettsiae, bacteria, and fungi, p. 1-78. In A.J. Provenzano, Jr. (ed.) The biology of crustacea. Vol. 6. Pathobiology. Academic Press, New York.
- Lightner, D.V. and R. Redman. 1994. An epizootic of necrotizing hepatopancreatitis in cultured penaeid shrimp (Crustacea: Decapoda) in northwestern Peru. Aquaculture 122:9-18.
- Lu, Y., L.M. Tapay, J.A. Brock and P.C. Loh. 1994. Infection of the yellow head baculo-like virus (YBV) in two species of penaeid shrimp, *Penaeus stylirostris* (Simpson) and *Penaeus vannamei* (Boone). J. Fish Dis. 17:649-656.
- Nash, G., C. Nithimathachoke, C. Tungmandi, A. Arkarjamorn, P. Prathanpipat and Ruamthvreesub. 1992. Vibriosis and its control in pond reared *Penaeus monodon* in Thailand, p. 143-155. In M. Shariff, R.P. Subasinghe and J.R. Artur (eds.) Diseases in aquaculture I. Asian Fisheries Society, Manila, Philippines.
- Nash, G., A. Arkarjamorn and B. Withyachumanarkul. 1993. Rapid diagnosis of yellow-head disease in black tiger shrimp. AAHRI Newsl. 2: 3-4.
- Supamattaya, K., J. Kasornchandra and S. Boonyaratpalin. 1994. Comparative study of simple methods for the diagnosis of yellow-head disease in the black tiger shrimp (*Penaeus monodon*). Asian Shrimp News 17:2-3.
- Takahashi, Y., T. Itami, M. Kondo, M. Maeeda, R. Fujii, S. Tomonaga, K. Supamattaya and S. Boonyaratpalin. 1994. Electron microscopic evidence of bacilliform virus infection in kuruma shrimp (*P. japonicus*). Fish Pathol. 29:121-125.
- Vijayan, K.K., S.V. Alvandi, K.V. Rajendran and K. Alagarwami. 1995. Prevalence and histopathology of *Monodon Baculovirus* (MBV) infection in *Penaeus monodon* and *P. indicus* in shrimp farms in the southeast coast of India. Asian Fish. Sci. 8:267-272.
- Wongteerasupaya, C., J.E. Vickers, S. Sriurairatana, G.L. Nash, A. Akarajamorn, V. Boosaeng, S. Pan-yim, A. Tassanakajon, B. Withyachumanarkul and T.W. Flegel. 1995. A non-occluded, systemic baculovirus that occurs in cells of ectodermal origin and cause high mortality in the black tiger prawn *Penaeus monodon*. Dis. Aquat. Org. 21:69-77.

K.K. VIJAYAN is currently a visiting scientist at Gulf Coast Research Laboratory, Institute of Marine Science, University of Southern Mississippi, USA, while K.V. RAJENDRAN, S.V. ALVANDI and K. ALAGARWAMI are from the Central Institute of Brackish-water Aquaculture, 141 Marshalls Road, Egmore, Madras-600008, India.