

An investigation into the electrical activity of tender, resting paraspinal muscles using surface electromyography: a pilot study

Hubbard A, Fryer G, Ball K. An investigation into the electrical activity of tender, resting paraspinal muscles using surface electromyography: a pilot study. *Journal of Osteopathic Medicine*. 2002;5(2):59-64.

Address correspondence to Gary Fryer, School of Health Science, City Campus Victoria University, P.O. Box 14428 MCMC, Melbourne 8001, Australia.

Email: gary.fryer@vu.edu.au

Abstract

Abnormal resting paraspinal muscle activity has been claimed to be responsible for changes in spinal tissue texture which are detectable by manual palpation. This pilot study investigated whether there was significant electrical activity in paraspinal musculature that was tender and that appeared to have altered tissue texture on palpation. Sixteen healthy volunteers between 18 and 35 years of age had their thoracic erector spinae mass palpated bilaterally from spinal levels T3 to T10 to identify paraspinal regions exhibiting altered tissue texture relative to the contralateral muscle mass. Surface electromyography (sEMG) was used to measure electrical activity in the muscle mass at the selected levels. No significant differences in electrical activity were observed between the tender and non-tender muscle masses, although a large difference existed in the one symptomatic subject. All muscle sites displayed EMG activity at rest, although the source of activity is not clear. A number of methodological problems with the EMG recording were encountered and are discussed. Future research is recommended using symptomatic participants.

Introduction

Somatic dysfunction has long been recognised by the osteopathic profession as having certain characteristics that can be diagnosed by physical examination and palpation and treated using osteopathic modalities.¹ The tissue texture abnormalities associated with somatic dysfunction are thought to involve muscles, skin, fascia, ligaments and tendons, as well as the vascular, neural and lymphatic networks embedded in those tissues.^{2,3}

Abnormally increased motor activity, or “muscle spasm”, has been a popular explanation for the nature of palpable muscle hypertonicity in the field of osteopathy for over half a century.¹ Although still commonly cited as an explanation for palpable tissue change, this belief has recently been questioned by authors in the field of osteopathy. Recently, Lederman⁴ questioned the concept of muscle tone and attributed palpable changes in resting muscle tone to purely biomechanical factors, such as passive length changes in the muscle, the effects of transient fluid accumulation, and changes in the connective tissue elements of the muscle. Research as early as 1935 reported that there was no electrical motor activity in resting muscles,^{5,6} and this remains the conventional view.^{4,7}

John Stedman Denslow was the first osteopath to use scientific methods to study somatic dysfunction.⁸ In 1941, Denslow and Clough⁵ published an article entitled “Reflex activity in the spinal extensors”, in which they used electromyography (EMG) to detect electrical activity in the paraspinal muscles of 16 asymptomatic participants. They palpated the erector spinae mass and inserted needle electrodes into areas assessed to be hard, or “lesioned”, and into adjacent “normal” areas. The participant then lay prone for between thirty and sixty minutes. Readings were taken during the few seconds between expiration and inhalation, as this period was considered to have the least muscle contraction.

Denslow and Clough⁵ reported electrical activity in 21 of the 25 lesion sites tested and absence of activity in adjacent normal areas. No activity was found in the other four sites. The activity reported varied in degree with no real pattern, only increasing as the subject became fatigued from being in the same position for 30 minutes or more. For “some” of the participants Denslow and Clough used a different protocol. The participants’ head was turned to one side in order to compare the response of the left and right thoracic erector spinae to head rotation. It was not reported how many such recordings were affected, nor were the results distinguished from those with participants’ heads resting in the midline. Other divergences from the testing procedure included measuring muscle responses to additional

influences such as extremely slight voluntary contraction of the abdominal wall, shallow respiration of the abdominal type, counting or talking aloud, and swallowing. The methodology and results were not described thoroughly, nor was any data other than a few EMG tracings displayed. No analysis was performed to determine whether the differences seen in the tracings were statistically significant. It is unclear from the published results where many of their interpretations and conclusions were drawn from.

Much of the early research of Denslow and others was of similar standard to that described above. Methods and results were poorly described, no statistical analysis was performed, and far-reaching conclusions drawn that were not always supported by the results.⁹ It appears that even the original authors had misgivings about the initial research findings. In 1942, Denslow and Hassett¹⁰ conceded that what was described to be the presence of reflex motor activity in his earlier study was not constant in degree and did not appear for a considerable time after placement of the electrodes (1-45 mins). In 1947, Korr,¹¹ who is credited with developing the facilitated segment model, commented that when a patient was prone there was no activity in spinal muscles, even those at lesioned segments, although when muscle activity was present it was “almost invariably found in the lesioned segments”. In 1975, thirty-one years after his original research was published, Denslow¹ acknowledged that the palpable tissue texture changes of somatic dysfunction might, in all likelihood, not be due to muscle contraction. Nevertheless, these early articles have provided much of the basis for the concept of the facilitated segment and other neurological models that are still widely quoted.^{2,12,13,14,15,16}

The therapeutic mechanisms underlying high velocity low amplitude (HVLA) technique are largely unknown,^{17,18,19} but it has been hypothesised that HVLA may be beneficial in the treatment of reflex muscle spasm by reducing motor neuron excitability and inhibiting hypertonic muscles.^{17,18, 20,21} Several recent studies have investigated the short-term reflex EMG responses in paraspinal muscles following HVLA,^{18,22,23} commonly with the underlying assumption that areas of dysfunction will have increased EMG activity (often quoting Denslow’s studies to support this claim) and that HVLA may decrease this activity. No study has yet demonstrated that abnormal paraspinal muscle activity is associated with clinically detected somatic dysfunction. The proposal that HVLA could decrease electrical activity in muscles needs to be reconsidered if no abnormal activity can be demonstrated in dysfunctional muscles.

Surface electromyography (sEMG) is a safe and non-invasive technique that provides an objective view of the dynamic internal environment of a muscle.^{24, 25} It has been suggested that sEMG recordings may be used to enhance clinical methods such as palpation, visual postural assessment and muscle testing. Cram and Kasman claimed that sEMG provides an objective assessment of resting tone, which correlates exceptionally well with any hypertrophied muscle mass noted during a palpation exam, but did not cite any evidence to support this.²⁵

The use of sEMG is not without limitations. The amplitude of the signal depends on many factors such as individual variations in participants, the diameter of muscle fibre, the amount of subcutaneous tissue, the normal resting electrical skin resistance, variations in muscle length, fibre size and the position of the electrode over the muscle. Electrical cross-talk is another consideration in the thoracic spine with several muscle layers including trapezius, rhomboids, spinalis, longissimus and iliocostalis muscles.²⁶ Energy from adjacent muscles is detected by surface electrodes and so cannot completely isolate the EMG signal from a single muscle.²⁷

Early osteopathic researchers recognised the importance of finding objective measures of clinical observations as well as scientific justification of osteopathic theories and beliefs.¹ With the need to objectively justify not only treatment modalities, but also the diagnostic basis for treatment, theories and beliefs cannot simply endure and continue to be assumed simply because they have always existed, without a sound scientific basis for their survival. It is necessary to continually challenge hypothetical models and discard those that are implausible, whilst refining and developing those that are more tenable.

The pioneering work of Denslow, Korr and others made a significant contribution to osteopathy as a profession, and their research was instrumental at a time when the very survival of osteopathy was under pressure.^{28,29,30} Nevertheless, Denslow's initial research was published 60 years ago and to the authors' knowledge, none of the original research has been reproduced despite much evidence that the neurological models proposed by Denslow & Korr may need revision.^{4,19,31,32}

This pilot study aims to re-examine the work of Denslow and Clough⁵ and determine if spontaneous electrical activity occurs in resting paraspinal muscles with altered tissue texture on palpation and reported tenderness, or whether these muscles are electrically silent as detected by surface electromyography.

Methods

Participants

Sixteen healthy volunteers between 18 and 35 (mean 25.2) years of age were recruited from a university student population. They had no history of pathology, major trauma or spinal surgery. After written and verbal explanation of the testing protocol, participants signed a written consent form authorising their participation in the study. Testing was performed in the university biomechanics laboratory. Ethical approval for the study was granted by the University Human Research Ethics Committee.

Procedure

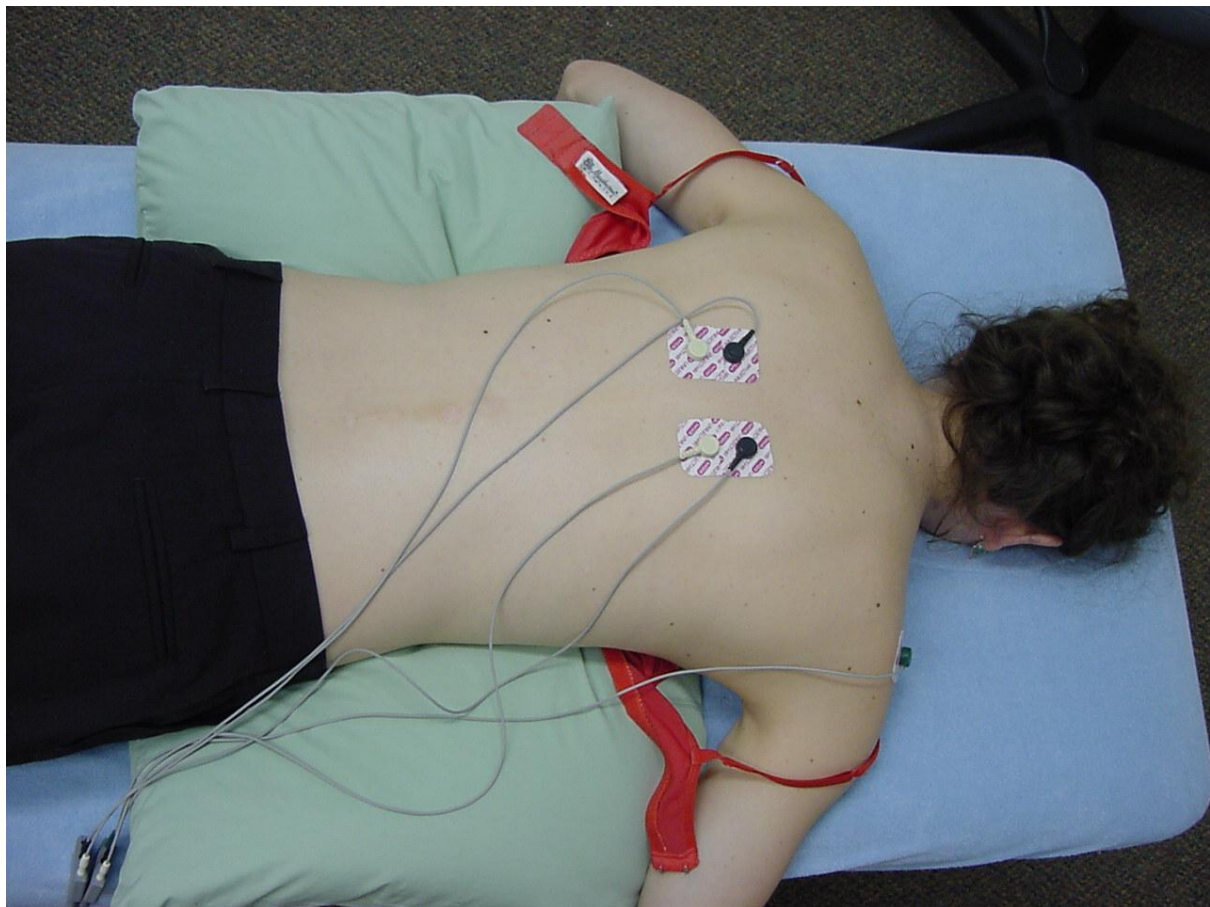
Participants lay prone on a treatment table with their head in the face hole and their back exposed down to the waist. A senior osteopathic student palpated the thoracic erector spinae mass from T3-T10 bilaterally for spinal levels exhibiting altered tissue texture on one side compared with the other. Participants were asked to report any tenderness elicited. The most tender muscle mass that exhibited altered tissue texture was selected for further examination using sEMG. The skin overlying the muscle mass at the selected level was swabbed on both sides of the spine with a 70% alcohol preparation to cleanse the skin. An additional area was prepared over the right acromion of each participant to provide a reference electrode (earth).

Two channels of sEMG were used to record simultaneously from the left and right sides. Two self-adhesive pre-gelled bipolar Ag/AgCl Medi-Trace pellet electrodes[§] were positioned over the site identified as being tender and notable for altered tissue texture and over the corresponding non-tender muscles on the contralateral side at the same segmental level, at a distance 3 cm lateral to the spinous processes. Electrodes were square shaped surface electrodes with a conductive surface area of 1 cm². The interelectrode distance was 25mm. All care was taken to ensure that inter-electrode distances remained constant, and that on each participant, electrodes were placed on the identical muscle mass either side of the spine. After placement of the electrodes, connections were tested by asking the participant to actively extend their head and back. Muscle activity from this brief contraction was observed on the display of the EMG computer. The participant was then asked to relax prone with head

[§] Graphic Controls Corp, Medical Products Div, PO Box 1274, Buffalo, NY 14240.

in the face hole. The sampling rate was set at 500 Hz, over a period of 14 seconds to ensure stability of the signal,²⁵ then swapped between sides to adjust for impedance differences in the leads and to provide normalisation of EMG recordings. A further 14 seconds were recorded (eg 1st recording lead A on right, lead B on left; 2nd recording lead A on left, lead B on right). Electrodes were removed and the skin cleaned to remove any residual gel and adhesive.

Figure 1: Electrode placement



Equipment

The EMG signal was captured using a telemetric system, Telemyo 8 (Glonner Electronics GmbH, Martinsried, Germany) and displayed using AMLAB II software (version type 2.0, build 19.8. Amlab Technology, Lewisham, NSW) on a standard personal computer. The signal was amplified in the AMLAB software (factor of 50), smoothed using a high pass filter (500Hz) and full wave rectified. The rectified data was then transferred to Microsoft Excel and smoothed using a low pass recursive Butterworth digital filter (10Hz).

Analysis

Of the sixteen participants tested, technical problems affected three sets of results and one participant moved during the recording period. Therefore a total of four participants' results were excluded from analysis.

In association with descriptive analysis using graphical display, it is important to quantify the data and present objective figures that describe the amount of electrical energy present in a muscle. The integral average describes the voltage as a function of time and was calculated as the area under the voltage-time curve of the graphical EMG signal.²³ Independent sample t-tests using SPSS Version 10 were performed comparing the integral average of the left and the right side to evaluate within subject asymmetries between sides.

Results

Figures 2 and 3 show two typical EMG traces. The white lines represent the right side of the body and the black lines, the left. The effect of differences in the leads can be clearly seen by the fact that the trace from one lead is almost twice the amplitude of the other. The crossover of leads can be clearly seen at the 2.3 sec mark in figures 1 and 2. Both traces are a 5 second snapshot of the entire 28.6 second duration.

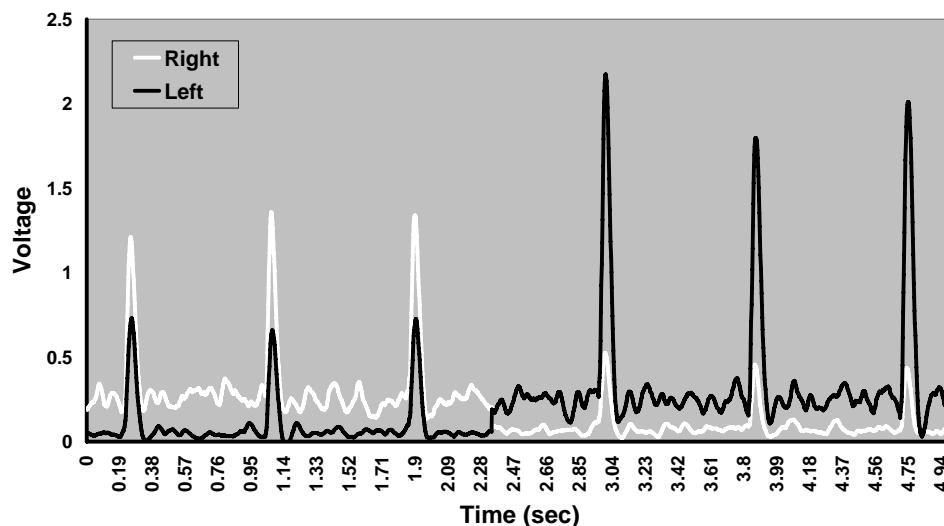


Figure 2: Asymptomatic Participant

Figure 2 shows a typical trace from an asymptomatic participant. The cardiac artifact can be clearly seen, and is larger on the left hand side (black line). The amplitude of signal detected

from both left and right sides is comparable, as seen by the equal difference between signals after the crossover of recording electrodes.

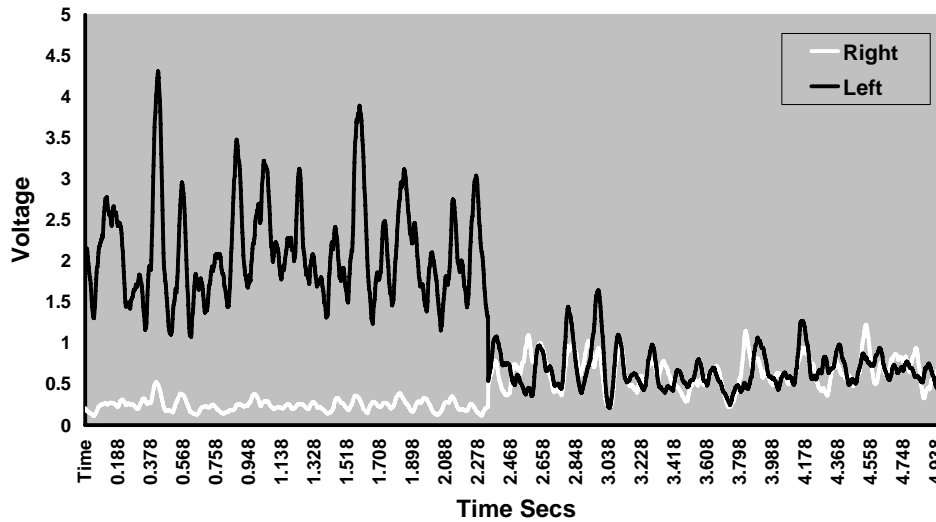


Figure 3: Symptomatic Participant.

Figure 3 shows the EMG trace from the symptomatic participant. The cardiac artifact is less distinguishable due to the higher amplitude of the signal from the muscle mass, which is approximately four times greater than the signal from the asymptomatic participant.

Table 1: Total Area Under the Curve

Tender side	Area Under Curve Tender (vt^{-1})	Difference	Area Under Curve Non-tender (vt^{-1})
Right	5.21	25.11%	6.96
Right	12.46	48.10%	6.46
Right	5.75	32.66%	8.53
Right	11.08	45.35%	20.28
Right	9.91	53.73%	21.41
Right	5.68	9.47%	6.27
Right	14.98	22.57%	11.60
*Left	40.85	68.34%	12.93
Left	7.25	3.22%	7.01
Left	15.06	24.56%	11.37
Left	14.27	45.53%	7.78
Left	6.93	35.95%	10.81

Table 1 outlines the values for the total area under the graph (voltage/time) of EMG tracings for each participant over two testing periods, each 14.332 seconds in duration. The greater area for each participant is presented in bold. The difference column displays the percentage of asymmetry between the tender and non-tender sides, calculated by the following formula:

$$\% \text{ Asymmetry} = \frac{\text{high} - \text{low}}{\text{high}} \times 100$$

Independent T-tests indicated that the within subject asymmetries between tender and non-tender sides were not significant ($p > 0.05$).

Discussion

Six participants exhibited greater resting paraspinal EMG activity on the tender side compared to the contra-lateral non-tender side. Of these, only three demonstrated an asymmetry of 40% or greater between sides. Cram and Kasman²⁵ recommend that 40% is the degree of asymmetry required to infer a real difference between the state of muscle activity using sEMG, taking into account a $\pm 10\%$ allowance for variability of the sEMG signal. Six participants exhibited an increased activity on the non-tender side. Of these, two had a 40% or greater asymmetry. Statistical analysis showed these differences were not significant ($p > 0.05$).

Only one of the participants was symptomatic at the time of testing. This participant reported left sided thoracic pain which was reproduced and exacerbated by palpation over the rib angle and demonstrated the greatest asymmetry between sides (68%). It would be valuable to further investigate more symptomatic participants to determine whether this electrical activity is a consistent finding in symptomatic presentations.

Participants were tested whilst lying prone with head position maintained in the midline. The voltage values used for analysis in this study were derived by plotting the numerical values detected by sEMG and calculating the area under the voltage-time curves (integration). The leads were swapped over to control for bias caused by asymmetry in the leads. Sites tested were documented, with comparison made between left and right sides at the same vertebral

level. All participants exhibited some degree of electrical activity, although it is inconclusive as to whether this activity was the result of motor activity in the underlying paraspinal musculature or was from cross-talk or other artifact.

Denslow and Clough drew their conclusions from visual interpretation of tracings of 1-2 second duration on ECG paper,⁵ that were not constant and sometimes took 45 minutes to appear.¹ Their methodology was unclear and appeared to vary between participants. No consideration was given to any potential asymmetry bias in the electrode leads, which was a major consideration in the present study. Likewise, no rationale was provided for the selection of the sites chosen for analysis. This presents several important questions, for example: How many of the lesion sites were on the left side or right side? Were the non-lesioned sites located on the contralateral muscle mass at the same or at a different segmental level? How many of the participants were symptomatic at the time of testing? How did their tracings differ from the asymptomatic participants? The current pilot study failed to support Denslow and Clough's claim that paraspinal regions detected as abnormal with palpation display increased and spontaneous resting EMG activity.

One important difference between this study and that of Denslow and Clough is our use of sEMG. Surface electrodes may be less sensitive to the activity of the muscles and more prone to cardiac artifact activity and cross-talk than intramuscular needle EMG. In particular, cardiac (ECG) artifact is problematic because it is often of greater magnitude than the muscle activity and particularly prominent in the thoracic spine, especially when recording from the left hand side.²⁵ This may partially explain why only two of the twelve participants exhibited greater electrical activity on the right. Five participants (out of seven) with tenderness on the right exhibited more activity on the left and four out of five with left sided tenderness had more activity on the left.

The authors were initially unfamiliar with sEMG equipment and encountered several problems. The difference in sensitivity of the electrode leads affected the study design as there was an 88% asymmetry in activity between the two leads before being placed on the participant. By crossing over the leads as part of the testing procedure, this error could be averaged out and the error reduced. Due to software difficulties three participants' results were incomplete. These results were omitted from the analysis.

Muscles of respiration also create electrical noise, especially if ancillary muscles are used to assist breathing. Other artifacts include lights, computers and radio frequencies, as well as the

EMG instrumentation itself.^{7,23} Basmajian⁷ even proposed polyester clothing as a potential source of noise. Participants were tested under identical conditions to keep artifact noise constant. A reference electrode (earth) was placed on the right acromion of each participant to adjust for the difference in resting electrical activity between participants.

Intramuscular needle electrodes are more specific to the muscle they are testing and would be more suited to the study of symptomatic participants when it is important to isolate the activity coming from a specific muscle and to minimise cross-talk. Nevertheless, indwelling needle electrodes also require more specialised skills and carry greater complexity in attaining ethical approval and participant consent. Specific muscle isolation was considered to be unimportant for the purpose of this study, as we were interested in the electrical properties of the whole muscle mass. However, further investigations should adopt improved filtering techniques to eliminate artifacts, perhaps with the addition of an ECG monitor to simultaneously record cardiac activity so this may be subtracted from the electrical activity of the spinal muscle mass of interest.

Conclusion

This pilot study did not demonstrate abnormal electrical activity in tender, resting paraspinal musculature, relative to the non-tender side in asymptomatic participants using surface electromyography. In one symptomatic participant, however, a considerable increase in activity was found on the symptomatic side. All paraspinal regions examined exhibited some electrical activity, but it was unclear whether this represented motor activity or noise in the form of cardiac artifact or cross-talk from other muscles.

Further investigation is required to examine the properties of tissues considered to have altered texture as detected by palpation. Future investigations should focus on symptomatic participants and consider the use of indwelling needle electrodes. If abnormal electrical motor activity cannot be detected in muscles that have palpably altered tissue texture, and that are tender, then other factors such as changes in connective tissue elements, transient fluid accumulation, and length changes need to be investigated to account for abnormal paraspinal tissue texture.

References

- ¹ Denslow JS. Pathophysiologic evidence for the osteopathic lesion: The known, unknown and controversial. *Journal of the American Osteopathic Association*. 1975; 75: 415-421. In: Beal MC. Ed. *Selected Papers of JS Denslow, DO. 1993 Year Book*. Indiana: American Academy of Osteopathy; 1993: 154-60.
- ² Greenman PE. *Principles of Manual Medicine 2nd Ed*. Baltimore; Williams & Wilkins; 1996: 99
- ³ Denslow JS. Soft tissues in areas of osteopathic lesion. *Journal of the American Osteopathic Association*. 1947; 46. In: Beal MC. Ed. *Selected Papers of JS Denslow, DO. 1993 Year Book*. Indiana: American Academy of Osteopathy; 1993: 144-149.
- ⁴ Lederman E. *Fundamentals of Manual Therapy*. London; Churchill Livingstone; 1997: 133-135.
- ⁵ Denslow JS, Clough GH. Reflex activity in the spinal extensors. *Journal of Neurophysiology*. 1941; 4:430-437. In: Beal MC. Ed. *Selected Papers of JS Denslow, DO. 1993 Year Book*. Indiana: American Academy of Osteopathy; 1993: 19-23.
- ⁶ Slosberg M. Effects of altered afferent articular input on sensation, proprioception, muscle tone and sympathetic reflex responses. *Journal of Manipulative and Physiological Therapeutics*. 1988; 11: 400-408.
- ⁷ Basmajian JV, De Luca CJ. *Muscles Alive: Their Functions Revealed by Electromyography*. 5th Ed. Baltimore; Williams & Wilkins; 1985.
- ⁸ Kuchera WA. *Osteopathic Principles in Practice. 2nd Ed. Revised*. Missouri; KCOM Press; 1992: 32.

⁹ Lederman E. Facilitated segments: a critical review. *British Osteopathic Journal*. 2000; 23: 7-10.

¹⁰ Denslow JS, Hassett CC. The central excitatory state associated with postural abnormalities. *Journal of Neurophysiology*. 1942; 5: 393-402. In: Beal MC. Ed. *Selected Papers of JS Denslow, DO. 1993 Year Book*. Indiana: American Academy of Osteopathy; 1993: 24-30.

¹¹ Korr IM. The neural basis of the osteopathic lesion. In: *The Collected Papers of Irvin M. Korr. 4th Ed*. Indiana; American Academy of Osteopathy; 1993; 120-127.

¹² Patterson MM, Wurster RD. Neurophysiologic system: integration and disintegration. In: Ward RC. Ed. *Foundations for osteopathic medicine*. Baltimore; Williams & Wilkins; 1997: 402-403.

¹³ Drummer T. *A Textbook of Osteopathy. Volume 1*. East Sussex; JoTom Publications; 1999: 99.

¹⁴ Gatterman MI. Ed. *Foundations of Chiropractic Subluxation*. St Louis; Mosby; 1995: 155.

¹⁵ Sammut EA, Searle-Barnes PJ. *Osteopathic Diagnosis*. Cheltenham; Stanley Thornes (Publishers) Ltd.; 1998: 33-35.

¹⁶ Stone C. *Science in the Art of Osteopathy*. Cheltenham; Stanley Thornes (Publishers) Ltd.; 1999: 75-77.

¹⁷ Katavich L. Differential effects of spinal manipulative therapy on acute and chronic muscle spasm: a proposal for mechanisms and efficacy. *Manual Therapy*. 1998; 3: 132-139.

-
- ¹⁸ Herzog W, Scheele D, Conway PJ. Electromyographic responses of back & limb muscles associated with spinal manipulative therapy. *Spine*. 1999; 24: 146-153.
- ¹⁹ Zusman M. What does manipulation do? The need for basic research. In: Boyling J, Palastanga NM, eds. *Grieve's Modern Manual Therapy of the Vertebral Column*. Edinburgh; Churchill Livingstone; 1994: 651-659.
- ²⁰ Walker BF. The reliability of Chiropractic methods used for the detection of spinal subluxation: An overview of the literature. *Australian Chiropractic and Osteopathy*. 1996; 5: 12-22.
- ²¹ Mitchell FL, Jr. *The Muscle Energy Manual. Volume 1*. Michigan: MET Press; 1995.
- ²² Herzog W, Conway PJ, Zhang YT, Gal J, Guimaraes ACS. Reflex responses associated with manipulative treatments on the thoracic spine: A pilot study. *Journal of Manipulative and Physiological Therapeutics*. 1995; 18: 233-236.
- ²³ Callaghan JP, Gunning JL, McGill SM. The relationship between lumbar spine load and muscle activity during extensor exercises. *Physical Therapy*. 1998; 78: 8-18.
- ²⁴ Cram JR, Kasman GS. *Introduction to Surface Electromyography*. Gaithersburg, Maryland; Aspen Publishers Inc.; 1998: 111.
- ²⁵ Greenough CG, Oliver CW, Jones APC. Assessment of spinal musculature using surface electromyographic spectral colour mapping. *Spine*. 1998; 23: 1768-1774.
- ²⁶ Gray H, Williams PL, Bannister, LH. *Gray's Anatomy, 38th Ed*. Edinburgh: Churchill Livingstone, 1995
- ²⁷ Roy SH, Oddson LIE. Classification of Paraspinal Muscle Impairments by Surface Electromyography. *Physical Therapy*. 1998; 78: 838-851.

²⁸ Patterson MM. Ed. *The Collected Papers of Irvin M. Korr. 4th ed.* Indiana; American Academy of Osteopathy; 1993: 11-12.

²⁹ Patterson MM. Ed. *Selected Papers of JS Denslow, DO. 1993 Year Book.* Indiana; American Academy of Osteopathy; 1993: 1-4.

³⁰ Patterson MM. Ed. *The Collected Papers of Irvin M. Korr Volume 2.* Indiana; American Academy of Osteopathy; 1997: 17-19.

³¹ Van Buskirk RL. Nociceptive reflexes and the somatic dysfunction. In: Mitchell FL, Jnr. *The Muscle Energy Manual. Volume 1.* Michigan: MET Press; 1995: 34-45.

³² Fryer G. Somatic dysfunction: updating the concept. *Australian Journal of Osteopathy* 1999;10(2):14-19.