

NEUROLOGY

CARRIER ERYTHROCYTE ENTRAPPED THYMIDINE PHOSPHORYLASE THERAPY FOR MNGIE

N. F. Moran, M. D. Bain, M.M.K. Muqit and B. E. Bax

Neurology 2008;71;686-688

DOI: 10.1212/01.wnl.0000324602.97205.ab

This information is current as of September 23, 2008

The online version of this article, along with updated information and services, is located on the World Wide Web at:

<http://www.neurology.org/cgi/content/full/71/9/686>

Neurology® is the official journal of the American Academy of Neurology. Published continuously since 1951, it is now a weekly with 48 issues per year. Copyright © 2008 by AAN Enterprises, Inc. All rights reserved. Print ISSN: 0028-3878. Online ISSN: 1526-632X.



At the time of reporting there were no reports of significant hepatotoxicity involving levetiracetam in clinical trials. There has been one reported case of a fatal fulminant hepatic failure in a patient with refractory epilepsy treated with combination carbamazepine and levetiracetam. Autopsy findings revealed complete hepatocyte necrosis⁵ but it was unclear if levetiracetam was the only or primary culprit in causality.⁵

In our patient careful consideration has been given toward other potential etiologies of hepatotoxicity. Phenytoin was deemed unlikely to be the cause due to preexisting deranged LFTs prior to commencing it and was still administered in the postoperative period when his LFTs were improving. Azathioprine can cause hepatotoxicity but the timing of its commencement did not correlate with the recurrence of abnormal LFTs. This very same reason applies to all his other posttransplant medications which were continued safely upon discharge. Oxcarbazepine and albendazole were already ceased prior to the development of documented hepatotoxicity making them very unlikely culprits. None of the antimicrobials were ceased when the patient's LFTs deteriorated posttransplant and its improvement thereafter was not related to their withdrawal.

Exclusion of other possible etiologies has left levetiracetam as the most likely cause of fulminant hepatic failure in our patient. This link was further strengthened by the inadvertent rechallenge with the

drug after post liver transplant resulting in deterioration of the LFTs and biopsy findings suggestive of a toxic cause.

From the Department of Gastroenterology and Hepatology (T.C.H.T., L.A.A., G.P.J., G.M.), WA Liver and Kidney Transplant Service (A.M., L.D., G.P.J.), Sir Charles Gairdner Hospital, Western Australia; Division of Tissue Pathology (B.W.d.B.), PathWest, Queen Elizabeth II Medical Centre, Western Australia; and Department of Medicine (L.A.A., G.M.), University of Western Australia.

Disclosure: The authors report no disclosures.

Received August 3, 2007. Accepted in final form March 19, 2008.

Address correspondence and reprint requests to Dr. Terrence C.H. Tan, Department of Gastroenterology and Hepatology, Sir Charles Gairdner Hospital, Nedlands, Western Australia 6008 Australia; perthfracp@gmail.com

Copyright © 2008 by AAN Enterprises, Inc.

1. Ben-Menachem E, Gilland E. Efficacy and tolerability of levetiracetam during 1-year follow up in patients with refractory epilepsy. *Seizure* 2003;12:131–135.
2. Radtke RA. Pharmacokinetics of levetiracetam. *Epilepsia* 2001;42 suppl 4:24–27.
3. Patsalos PN. Clinical pharmacokinetics of levetiracetam. *Clin Pharmacokinet* 2004;43:707–724.
4. Patsalos PN. Pharmacokinetic profile of levetiracetam: toward ideal characteristics. *Pharmacol Ther* 2000;85:77–85.
5. Skopp G, Schmitt HP, Pedal I. Fulminant liver failure in a patient on carbamazepine and levetiracetam associated with status epilepticus. *Archiv Kriminologie* 2006;217:161–175.

N.F. Moran, MBChB,
MRCP, MSc
M.D. Bain, MD
M.M.K. Muqit, MRCP
B.E. Bax, PhD

CARRIER ERYTHROCYTE ENTRAPPED THYMIDINE PHOSPHORYLASE THERAPY FOR MNGIE

Mitochondrial neurogastrointestinal encephalomyopathy (MNGIE) is an autosomal recessive condition caused by mutations in the nuclear gene ECGF1 coding for thymidine phosphorylase (TP).^{1,2} Clinical features include gastrointestinal dysmotility, peripheral sensorimotor polyneuropathy, progressive external ophthalmoplegia, and hepatopathy. In vitro evidence and the improvement following stem cell transplantation (alloSCT) in one patient suggest the pathogenesis centers on elevated systemic levels of the TP substrates, thymidine (Thd) and deoxyuridine (dUrd).^{3,4}

Case report. In September 2005, a 21-year-old woman presented after a 4-week history of progressive bilateral distal lower limb numbness and foot drop. She had bouts of unexplained gastrointestinal symptoms and weight loss since age 6 years and at 19 developed an acute abdomen leading to a laparotomy that revealed gross small bowel distension (thought to be caused by an elevated liga-

ment of Treitz) and hepatosplenomegaly. A gastrojejunostomy was performed.

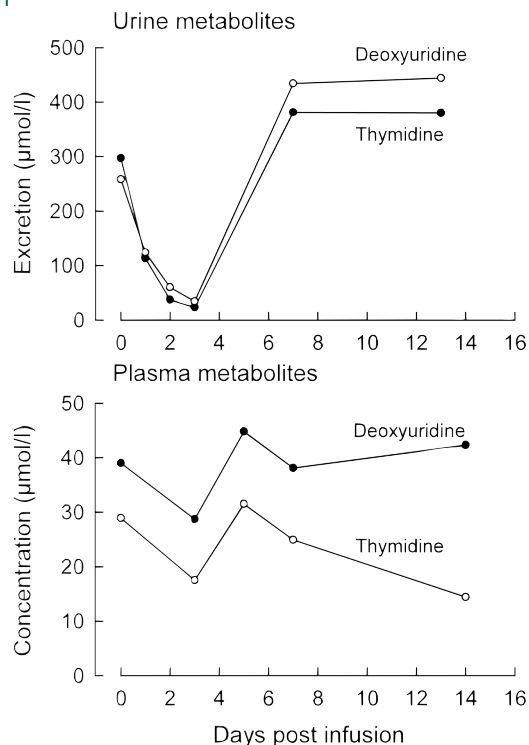
On neurologic examination, the positive findings were subtle pigmentary retinopathy, partial ptosis, slight reduction of eye abduction, markedly slow horizontal saccades, severe weakness of ankle movements, absent muscle stretch reflexes and plantar reflexes, and stocking diminution for light touch and pain (all findings bilateral and symmetric). Of note on systemic examination: underweight, gross hepatosplenomegaly, tachycardia, and hyperdynamic cardiac apex.

Her parents were not related. She left higher education in autumn 2005 due to her illness.

After the laparotomy, investigations including hepatitis serology and serum copper were normal; a liver biopsy revealed steatohepatitis. A brain MRI was normal except equivocal diffuse high T2 signal in the centrum semiovale bilaterally.

Following the initial presentation, abnormal results included normochromic normocytic anemia; serum lactate 3.72 mmol/L; CSF protein 1.95 g/L;

Figure Plasma and urine metabolite values before and after CEETP infusion



Normal ranges: plasma deoxyuridine <0.05 µmol/L; plasma thymidine <0.05 µmol/L; urine deoxyuridine undetectable; urine thymidine undetectable.

CSF lactate 5.6 mmol/L; plasma Thd 13 µmol/L and dUrd 16 µmol/L (normal: both <0.05 µmol/L); urine Thd and dUrd 1.94 mmol/L and dUrd 1.95 mmol/L (normal: both undetectable); TP activity measured by HPLC was undetectable in leukocytes and platelets (ranges for controls expressed as nmol/hour/mg prot: leukocytes 321–1,341; platelets 377–1,078). Mitochondrial DNA analysis of blood cells for 3243>G and 8993T>C/G was negative. Nerve conduction studies confirmed a generalized sensorimotor polyneuropathy. Abdomen CT showed gross hepatosplenomegaly with marked hepatic steatosis and nodularity.

Analysis of ECGF1 in blood cells demonstrated a homozygous mutation of the conserved AG nucleotide of the 3'-splice site of intron 2 corresponding to IVS3-1G>C.

Through 2006, she was increasingly unwell, with neuropathic upper limb involvement and worsening abdominal symptoms. She required TPN and subsequently a nasojejun tube due to gastroparesis. Blood results showed albumin 27 g/L, INR 1.16, bilirubin 8 mmol/L, ALP 135IU/L, AST 92IU/L, and GGT 129IU/L. She required recurrent paracentesis for massive ascites and developed hematemesis from esophageal varices which were banded.

Treatment. Approval for a trial of carrier erythrocyte entrapped thymidine phosphorylase therapy (CEETP) was given by the local New Clinical Procedures Committee, local Ethics Committee, and Administration of Radioactive Substances Advisory Committee, UK. A patient information sheet was provided and written informed consent obtained. On day one, 140 mL of whole blood was collected aseptically and the erythrocytes were loaded with TP using the previously described hypo-osmotic dialysis procedure.⁵ The washed and packed TP-loaded carrier erythrocytes were resuspended in an equal volume of retained plasma and returned to the patient by slow IV infusion. The administered dose of TP was 1,020 units encapsulated within 20.25×10^{10} erythrocytes (where 1 unit of TP is defined as the activity required to convert 1.0 µmol of Thd and phosphate to thymine and 2-deoxyribose 1-phosphate per minute at 25°C).

Pretreatment and serial postinfusion blood samples and 24-hour urine collections were made.

Results. Three days postinfusion (figure), the urinary excretion of Thd was 6% and that of dUrd 13% of the pretherapy values. The plasma concentrations decreased in parallel. Unfortunately, the patient's clinical condition remained poor and she died of pneumonia 21 days after CEETP.

Discussion. CEETP was associated with marked reduction of plasma and urine Thd and dUrd. Although these metabolites can fluctuate widely in patients with MNGIE, the consistency of the fall would suggest a causal relationship with the administered CEETP. The results are encouraging, particularly as a low dose was administered. An observed clinical effect was unlikely given advanced disease and the use of a single treatment.

We had discounted alloSCT and liver transplant because of an unacceptable mortality risk due to the patient's severe clinical state. Autologous erythrocytes encapsulated adenosine deaminase has been used successfully in a patient with adenosine deaminase deficiency.^{6,7} The approach is applicable to disorders where the erythrocyte membrane is permeable to target plasma metabolites. Encapsulation prevents the formation of neutralizing antibodies and maintains enzyme activity for the erythrocyte life span. We hypothesize that a reduction of Thd and dUrd in the plasma would lead to similar reductions in the intracellular compartment, as observed in other conditions, thus translating into clinical improvement.

Our previous in vivo survival studies demonstrated an initial splenic sequestration of carrier erythrocytes, followed by a reflux into the circulation

24 to 144 hours postinfusion; this may contribute to the fluctuations observed in plasma metabolite concentrations.⁵ The disjunction of the plasma metabolites at day 14 is based on a single observation; this might be explained by saturation of the erythrocyte membrane nucleoside transporter.

The main safety consideration was of an immunologic reaction to bacterial TP or endotoxins. Endotoxin levels were within pharmaceutical safe levels. Our previous experience with adenosine deaminase indicates immunologic protection with encapsulation within carrier erythrocytes, but we cannot exclude the possibility following repeated administrations.

CEETP may be a promising treatment for MNGIE. However, repeated administration, probably two to four weekly and potentially lifelong, would be required, with costs not too dissimilar to other enzyme replacement therapies (\$200,000 per year). The frequency of administration is likely to be influenced by many factors, particularly the severity of TP dysfunction and erythrocyte half life. The latter was satisfactory in the current case despite massive splenomegaly. The clinical utility of reducing Thd and dUrd concentrations remains largely theoretical. Carrier erythrocyte entrapped TP enzyme therapy offers the opportunity to impose a period of lowered Thd and dUrd concentrations during which any clinical benefit can be assessed before considering alloSCT.

From Kent & Canterbury Hospital (N.F.M.), Canterbury; Kings College Hospital (N.F.M.), London; Department of Child Health (M.D.B., B.E.B.), Division of Clinical and Developmental Sciences, St George's, University of London; and Institute of Molecular Neuroscience (M.M.K.M.), Institute of Neurology, London.

Disclosure: The authors report no disclosures.

Received August 28, 2007. Accepted in final form April 2, 2008.

Address correspondence and reprint requests to Dr. Nicholas Frederick Moran, Neurology, Kent & Canterbury Hospital, Ethelbert Road, Canterbury, CT1 3NG, UK; nfm10@aol.com

Copyright © 2008 by AAN Enterprises, Inc.

ACKNOWLEDGMENT

The authors posthumously acknowledge the subject of this paper, Rosie, as well as her family, who supported her through her protracted illness. The treatment was administered in the hope of ameliorating her condition, but Rosie was fully aware of its experimental nature and was hopeful that other patients with MNGIE might ultimately be successfully treated. The authors acknowledge Dr. Lynette Fairbanks of the Purine Research Laboratory, St. Thomas' Hospital, London, for the biochemical analysis; and Dr. Michio Hirano, Columbia University College of Physicians and Surgeons, New York, for his input into the clinical management of this patient.

1. Hirano M, Silvestri G, Blake DM, et al. Mitochondrial neurogastrointestinal encephalomyopathy (MNGIE): clinical, biochemical, and genetic features of an autosomal recessive mitochondrial disorder. *Neurology* 1994; 44:721–727.
2. Nishino I, Spinazzola A, Hirano M. Thymidine phosphorylase gene mutations in MNGIE, a human mitochondrial disorder. *Science* 1999;283:689–692.
3. Marti R, Nishigaki Y, Hirano M. Elevated plasma deoxyuridine in patients with thymidine phosphorylase deficiency. *Biochem Biophys Res Commun* 2003;303: 14–18.
4. Hirano M, Marti R, Casaali C, et al. Allogenic stem cell transplantation corrects biochemical derangements in MNGIE. *Neurology* 2006;67:1458–1460.
5. Bax BE, Bain MD, Talbot PJ, Parker-Williams EJ, Chalmers RA. Survival of human carrier erythrocytes in vivo. *Clin Sci* 1999;96:171–178.
6. Bax BE, Bain MD, Fairbanks LD, Simmonds HA, Webster AD, Chalmers RA. Carrier erythrocyte entrapped adenosine deaminase therapy in adenosine deaminase deficiency. *Adv Exp Med Biol* 2000;486:47–50.
7. Bax BE, Bain MD, Fairbanks LD, Webster ADB. A nine year evaluation of carrier erythrocyte encapsulated adenosine deaminase therapy in a patient with adult-type adenosine deaminase deficiency. *Eur J Haematol* 2007;79: 338–348.

**CARRIER ERYTHROCYTE ENTRAPPED THYMIDINE PHOSPHORYLASE
THERAPY FOR MNGIE**

N. F. Moran, M. D. Bain, M.M.K. Muqit and B. E. Bax

Neurology 2008;71;686-688

DOI: 10.1212/01.wnl.0000324602.97205.ab

This information is current as of September 23, 2008

**Updated Information
& Services**

including high-resolution figures, can be found at:
<http://www.neurology.org/cgi/content/full/71/9/686>

Subspecialty Collections

This article, along with others on similar topics, appears in the following collection(s):
All Clinical Neurology
http://www.neurology.org/cgi/collection/all_clinical_neurology **All Toxicology**
http://www.neurology.org/cgi/collection/all_toxicology **All Epilepsy/Seizures**
http://www.neurology.org/cgi/collection/all_epilepsy_seizures **Antiepileptic drugs**
http://www.neurology.org/cgi/collection/antiepileptic_drugs **Generalized seizures**
http://www.neurology.org/cgi/collection/generalized_seizures

Permissions & Licensing

Information about reproducing this article in parts (figures, tables) or in its entirety can be found online at:
<http://www.neurology.org/misc/Permissions.shtml>

Reprints

Information about ordering reprints can be found online:
<http://www.neurology.org/misc/reprints.shtml>

