



**QUEEN'S
UNIVERSITY
BELFAST**

Retinal drusen

Williams, M., Craig, D., Passmore, P., & Silvestri, G. (2009). Retinal drusen: Harbingers of age, safe havens for trouble. *Age and Ageing*, 38(6), 648-654. DOI: 10.1093/ageing/afp136

Published in:
Age and Ageing

Queen's University Belfast - Research Portal:

[Link to publication record in Queen's University Belfast Research Portal](#)

General rights

Copyright for the publications made accessible via the Queen's University Belfast Research Portal is retained by the author(s) and / or other copyright owners and it is a condition of accessing these publications that users recognise and abide by the legal requirements associated with these rights.

Take down policy

The Research Portal is Queen's institutional repository that provides access to Queen's research output. Every effort has been made to ensure that content in the Research Portal does not infringe any person's rights, or applicable UK laws. If you discover content in the Research Portal that you believe breaches copyright or violates any law, please contact openaccess@qub.ac.uk.

REVIEW

Retinal drusen: harbingers of age, safe havens for trouble

M. A. WILLIAMS^{1,2}, D. CRAIG¹, P. PASSMORE¹, G. SILVESTRI²

¹Department of Geriatric Medicine, Whitla Medical Building, Queen's University of Belfast, 97 Lisburn Road, Belfast, BT9 7BL, UK

²Centre for Vision Science, Royal Hospitals Trust, Grosvenor Road, Belfast, BT12 6BA, UK

Address correspondence to: Michael Williams. Tel: (+44) 2890972153; Fax: (+44) 2890325839.

Email: mikewilliams99@hotmail.com

Abstract

Drusen are small focal extracellular deposits underneath the retina, visible ophthalmoscopically as yellow dots. The more hard drusen there are, the greater the risk of developing soft drusen and retinal pigmentary changes, which in turn increase the risk of developing advanced age-related macular degeneration. Much remains to be discovered about drusen. For the patient with drusen, basic advice on diet and smoking and maintenance of a high level of vigilance for visual changes is appropriate management.

Keywords: *retinal drusen, macular degeneration, vision: ocular, elderly*

Introduction

Much of healthcare is concerned with lumps and bumps. Drusen are small extracellular lumps in the eye, visible ophthalmoscopically as focal yellow dots (Figure 1a). Drusen are wedged between the deepest layer of the retina, the retinal pigmented epithelium (RPE) and Bruch's membrane, which separates the retina from the choriocapillaris. The appearance of drusen is a characteristic change that can occur in the macula as a function of age, along with retinal pigment abnormalities and patchy atrophy of the retinal pigment epithelium (Figure 1b). This cluster of changes constitutes early age-related macular degeneration (AMD), and while early AMD does not affect day-to-day vision [1], these signs may herald the beginning of a process progressing towards advanced AMD [central geographic atrophy or choroidal neovascularisation (CNV)]. Advanced AMD is the most common cause of acquired visual impairment in Europeans aged over 65 years [2]. It is not known however why only some individuals with drusen develop advanced AMD, but it is undisputed that drusen have a role: almost all patients with AMD have drusen. This review seeks to collate the current stage of knowledge on drusen, specifically on their clinical features, classification, composition and clinical relevance.

Methods

We based this review on a search of PubMed. The following search terms were used: 'drusen' and each of the following

in turn—'AMD'; 'age-related AND macular AND degeneration'; 'age-related AND maculopathy'; 'classification'; 'grading'; 'epidemiology'; 'laser'; 'antioxidants'; 'statins'; 'treatment'; and 'prevention'. The articles which were judged to be the most relevant, important and reliable were selected. This is a narrative review as the assessment of what information to present was subjective, being based on the collective expertise of the authors. It may be that certain studies were included which should not have been, and others were not included which should have. However, every effort was made to avoid bias and to present a representative and balanced picture of evidence. None of the authors have any conflicts of interest.

Identification of population-based studies investigating the incidence of AMD (Table 2) was done using Pubmed. Most papers described previous population-based studies on the subject, facilitating their identification. The use of images for this review followed the tenets of the Declaration of Helsinki.

How are drusen described?

Drusen are considered a hallmark feature of AMD [3, 4], but there is no universally accepted AMD classification system. The Wisconsin Age-Related Maculopathy Grading System was one of several considered by investigators who collaborated in 1995 to agree on an AMD grading system [5]. Refinements abound, such as the 'AREDS simplified severity scale' [6, 7].

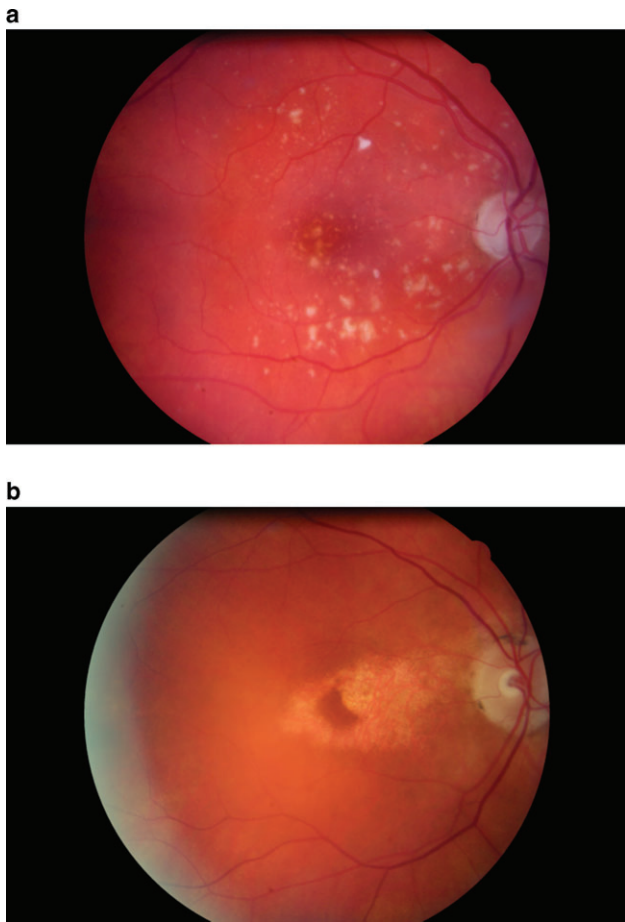


Figure 1. (a) Hard, soft distinct and soft indistinct drusen. (b) Geographic atrophy surrounding the fovea, with a tongue of atrophy extending onto the central fovea.

Drusen are typically round and yellow. Clinically, age-related drusen are described as hard or soft. Those $<63 \mu\text{m}$ in diameter are classed as hard drusen, while those $<125 \mu\text{m}$ may be classed as hard if they look flat. As a guide, the diameter of the average retinal vein as it crosses the optic disc edge is considered to be $125 \mu\text{m}$. Drusen $>63 \mu\text{m}$ which appear to have substance are soft drusen. Apparent bulk of drusen can be, however, only discerned binocularly, rather than with the monocular view offered by a direct ophthalmoscope or a photograph. Soft distinct drusen have uniform density and sharp edges, whereas soft indistinct drusen have decreasing density from the centre out, and fuzzy edges.

Drusen can also be described by location, macular or peripheral, and some specific patterns have been described. For example, reticular drusen are ill-defined ribbons of broad interlacing networks of drusen [8]. ‘Early-adult onset grouped drusen’ [9] fluoresce discretely during fundus fluorescein angiography, described as giving a ‘beautiful star-in-the-sky’ appearance [10]. Histological labels exist: basal laminar deposits are diffusely deposited materials lying internal to the RPE basal lamina [4]. In clinical practice, clinicians usually limit their descriptions of drusen to hard, soft distinct or soft indistinct. Drusen may be difficult to distinguish from similar

lesions, such as cotton wool spots or exudates. If distinction of retinal lesions is difficult, the wider picture should be taken into account, for example whether there are other signs of AMD or diabetic retinopathy, as well as non-ocular factors such as the age of the patient.

In what clinical situations other than increasing age are macular drusen found?

Drusen are on occasion not age related. For example, they can be found in chronic retinal detachment, phthisis bulbi, specific inherited macular dystrophies and membranoproliferative glomerulonephritis type II. Drusen seen with choroidal pigmented lesions are reassuring, implying longevity of the lesion and reducing suspicion of malignancy.

In the original description of these lesions [11], Donders used the German word for a rock structure consisting of a solid outer shell and an internal cavity, typically containing sparkling crystals and known in geological circles as a ‘geode’. The German word for geode is druse. Similarly hard drusen have a substructure, and can be calcified giving a sparkling appearance. In contrast, soft drusen are microscopically homogeneous consisting of liquefied material [12].

The make-up of drusen varies with the age of the subject, size of druse, retinal location of the druse and AMD status. An abundance of types of cells and molecules have been found in drusen; dendritic cells [4], proteins [3], lipids [13] and sugar-containing molecules [14]. The presence of some components of drusen raises intriguing themes. For example, non-fibrillar amyloid- β in drusen intriguingly hints that similar processes may occur in the pathogenesis of Alzheimer’s disease as AMD [15]. Advanced-glycation endproducts indicate oxidative damage. Myriad inflammatory mediators have been described in drusen [4].

The biogenesis of drusen is not fully understood. They are thought to result from diffuse biochemical dysfunction in the local environment. Their components may originate from the choroidal vasculature [3] or consist of accumulated excrescences from RPE cells [16]. A nidus of unknown origin may herald the beginning of a druse’s life, around which macromolecules gather [17]. Phagocytes may attempt to engage the abnormal material [18], and inflammatory debris may contribute to the expansion, if not form the initial seed itself. Oxidative damage and protein cross-linking may further contribute to the failure to clear a nascent druse [3]. It is thought that drusen have a dynamic life-cycle of nucleation, expansion and coalescence, with calcification or involution as possible sequelae [19] and they may spontaneously disappear [20].

How prevalent are drusen?

There are many estimates of the prevalence of drusen [2, 21–30], some of which are given in Table 1. The estimates vary as the populations studied and the samples selected vary in demographic and risk factor profiles. The validity

Table 1. Prevalence of macular drusen (percentage)

Study	Size or type of drusen	All ages (minimum age of subjects, years)	Age in late 40s	Age in late 50s	Age in late 60s	Age in late 70s
Beaver Dam Eye Study [22]	Any	95 (43 years)	96.9	96.9	94.4	92.2
Proyecto VER [26]	Any	92 (50 years)		93.4	91.6	88.7
Waterman Eye Study [31]	Any	86 (30 years)	84	89	87	84
EUREYE [2]	>63 μm	52.4 (65 years)				
Barbados Eye Study [30]	<63 μm	40.3	40.5	41.5	39.8	33.0
	64–250 μm	21.9 (40 years)	13.5	20.6	32.7	40.6
	>250 μm	1.1	0.3	1.3	1.2	2.6
Visual Impairment Project [25]	Small hard	77 (40 years)				
	Soft distinct	7.5	M: 2.7 F: 2.5	M: 3.4 F: 6.3	M: 8.8 F: 9.0	M: 15.7 F: 15.1
	Soft indistinct	4.3	M: 0.48 F: 1.3	M: 1.0 F: 1.3	M: 3.6 F: 4.8	M: 9.4 F: 12.3
Los Angeles Latino Eye Study (40 years) [28] (at least one drusen present in 98.2%)	Only small hard	(40 years)	67.2	57.4	46.1	35.2
	Soft distinct		12.7	16.6	24.2	28.6
	Soft indistinct		3.6	6.2	9.0	16.5

Table 2. Population based studies investigating the incidence of AMD

Study title	Ref.	No. with gradable photos at follow-up (no. examined at baseline) ^a	Age of subjects at baseline (years)	Follow-up period (years)	Selected pertinent significant risk factors for development of advanced AMD (GA or CNV) present at baseline ^b , or pertinent comment
Barbados Eye Study	[36]	2793 (4631)	40–84	9	Early AMD
Beaver Dam Eye Study (USA)	[37]	2119 (4926)	43–86	15	More severe drusen type ^c Larger area of drusen
Blue Mountains Eye Study (Australia)	[7]	1952 (3654)	49 or older	10	More severe drusen type ^{c,d} - Larger drusen size
Copenhagen City Eye Study (Denmark)	[38]	327 (946)	60–80	14	- More severe drusen type ^c Larger drusen size
Hisayama Study (Japan)	[39]	961 (1482)	50 or older	5	Eight subjects with incident late ARM had early ARM at baseline ^f
Melton Mowbray study (UK)	[40]	88 (529)	77 or older	7	Drusen size and severity is slightly more likely to increase with time than regress ^c
Reykjavik Eye Study (Iceland)	[41]	846 (1045)	50 or older	5	No comment was made on risk factors for advanced AMD
Rotterdam Study (Netherlands)	[42]	4688 (6780)	55 or older	6.5	More severe drusen type ^f
Salisbury Eye Evaluation Project (USA)	[43]	1937 (2240)	65–84	2	Larger drusen size
Visual Impairment Project (Australia)	[44]	1625 (3271)	40 or older	4.5	More severe drusen type ^f Larger drusen size
Waterman Study (USA)	[20]	483 (838)	Over 30	5	Increasing numbers of small drusen increase the risk of large drusen

^aReasons for drop in numbers included death of eligible participants, loss to follow-up, refusal to participate and exclusion from analysis, for example due to advanced AMD at baseline or ungradable photos at baseline.

^bRetinal pigmentary changes (hypo- or hyper-pigmentation) have also consistently been identified as a significant risk factor for the development of advanced AMD in these studies.

^cUsing the Wisconsin Age-Related Maculopathy Grading System [45].

^dUsing the AREDS Simplified Severity Scale [6].

^eUsing a modified Wisconsin Age-Related Maculopathy Grading System.

^fUsing the International Classification System for AMD [5].

of extrapolation of study findings will vary correspondingly. Overall it is evident that a majority of patients aged >40 years have some type of drusen, and while the prevalence of small hard drusen does not increase with age, the prevalence of soft drusen does. This may be because hard drusen evolve into larger drusen with time, or because advancing media opacities with age may make smaller drusen more difficult to identify.

Are drusen guilty of causing progression to advanced AMD?

Drusen exceed normal age-related changes, but whether they play an active role in causing disease is not known. In a review of drusen and AMD, Anderson *et al.* [32] describe how drusen may either be epiphenomena, passive markers

Table 3. Risk of advanced AMD according to number and type of drusen present at baseline in the Beaver Dam cohort: 15-year follow-up [37]

Most 'severe' drusen type present at baseline	Risk (incidence) of advanced AMD at 15-year follow-up (central geographic atrophy or choroidal neovascularisation)
1 or 2 hard drusen	0.4%
8 hard drusen	1.5%
Few soft distinct drusen	1.6%
Extensive soft drusen	13.1%
13–32 soft indistinct drusen	27.0%
>32 soft indistinct drusen	41.0%

of age-related changes, or contributors to RPE and subsequent photoreceptor cell dysfunction and death, for example by impairing the transfer of metabolites between the choriocapillaris and RPE, ultimately starving and choking the RPE. Drusen attract inflammatory activity, and a compelling narrative describes how this could provoke a cascade of molecular events resulting in necrotic [4] or apoptotic [33] RPE cell death or CNV [34]. The presence of complement factors as constituents of drusen is especially pertinent, given that genetically determined defects in the regulation of the complement cascade have been implicated in the pathogenesis of AMD [35]. Thus, drusen may represent a safe haven, harbouring dangerous elements that threaten the health of the eye.

What is the prognostic significance of macular drusen?

Not all individuals with drusen develop AMD. Several studies on subjects drawn from population sampling have described the natural history of drusen; all of such studies of which we are aware are presented in Table 2.

The longest follow-up periods reported to date are 14 years [38] and 15 years [37]. In the Copenhagen study [38], in which a cohort of individuals aged between 60 and 80 years at baseline was followed for 14 years, the 'most severe' drusen type present was found to be significant. A total of 2.9% of those with hard drusen at baseline developed central geographic atrophy or CNV, while this occurred in 26.7% of eyes with soft distinct drusen. In eyes with soft indistinct drusen, geographic atrophy developed in 34.4% and CNV in 53.1%. Thus to estimate an individual's risk of AMD, identifying the drusen type is crucial. In the Beaver Dam study [37], in which the follow-up period was 15 years, the number of drusen at baseline was a significant determinant of AMD incidence (Table 3). A larger area of small hard drusen was associated with a greater risk of subsequent soft indistinct drusen or retinal pigment abnormalities, and these changes in turn were associated with greater risk of advanced AMD. However, 18% of soft indistinct drusen disappeared, not in association with advancing AMD, and these eyes had a reduced risk of advanced AMD of 80%.

The risk of AMD varies with many other factors from lifestyle, ethnic and genetic factors to availability and uptake of screening and treatment. However, in the presence of high-risk features a high level of vigilance is appropriate to detect late AMD early, particularly CNV for which treatment may be possible. Although this review focuses on drusen, retinal pigmentary abnormalities and RPE atrophy, which have also been consistently identified as risk factors for progression, should also be noted.

How should the patient with drusen be managed?

There are no effective treatments to restore vision lost to geographic atrophy, and although there has been a revolution in the management of CNV, most patients with wet AMD do not recover lost vision. Drusen are the first clinically evident sign of AMD, but age-related retinal changes probably begin long before drusen can be spotted. Treatment that prevents AMD could have a major public health impact even if only modestly effective. The only risk factors for AMD that have been consistently identified are age, genetic susceptibility and smoking. There appears to be a dose–response relationship between smoking and risk of AMD, and smoking precedes the development of AMD, suggesting a causative relationship [46].

Regression of drusen following laser photocoagulation was first described by Gass [47]. After the initial observation, several case series reported results although these series were often small, short or uncontrolled. Drusen regression followed laser treatment, occurring more quickly following more intense burns [48], but results relating to the incidence of CNV and visual outcome were mixed. There was enough encouragement to spur controlled studies such as the CNV Prevention Trial [49]. Eyes with >10 large drusen in both eyes, or in one eye with neovascular AMD in the other, were assigned to perifoveal argon laser treatment or no treatment. Recruitment was suspended early due to an increased incidence of CNV in the treated eyes. The same fate befell the Drusen Laser Study [50], a similarly controlled pilot study. Two multicentre clinical trials [51, 52] were initiated to investigate the effects of variations of laser treatments but in neither case was laser for drusen recommended.

Antioxidant supplements are frequently marketed to protect vision. The retina is uniquely exposed to high levels of oxidative stresses and these may contribute to drusen formation [3]. A Cochrane review of the use of antioxidants to prevent drusen developing found no evidence that dietary antioxidant supplements were of benefit [53]. It may be that in certain populations, such as those with genetic susceptibility or those with a poor diet, such supplementation is effective. Evidence for the effectiveness either of zinc alone or in combination with antioxidants (beta carotene, vitamin C and vitamin E) in preventing progress from drusen to advanced AMD emerged from the Age-Related Eye Disease Study (AREDS) [54, 55]. Benefit was only shown, however,

for those with at least one druse $>125 \mu\text{m}$ or extensive drusen of between 63 and $125 \mu\text{m}$ or non-central geographic atrophy. The proportion with these signs which developed neovascular AMD or central geographic atrophy after 6 years was 28% in the placebo group, and only 20% in those zinc and antioxidants. No benefit was evident for those with less severe drusen. Given the plausibility of their benefit and their apparent safety, individuals with no drusen or only small drusen may elect to take AREDS-like formulations despite lack of evidence for their benefit. Some caution is due as these supplements do not guarantee prevention of progression, and safety concerns cannot be ignored; beta-carotene for example may increase the risk of lung cancer in smokers. For such intervention to be used outside the AREDS indications, and publically funded, quality evidence of cost-effectiveness is needed.

Statins have lipid-lowering ability and anti-inflammatory effects. As lipids are a major component of drusen, and as inflammation has been implicated in the pathogenesis of drusen, statins may retard the appearance of drusen and AMD. Most studies have shown no apparent protective effect of statins; these, however, have been observational [56–60]. There have been calls for a randomised controlled trial of statin use in preventing drusen or drusen progression [61].

Conclusion

In ancient times, it was thought that darts of light emerge from the eye [62]. While such an idea is ridiculed now, perhaps in centuries to come our paucity of understanding about drusen will be mocked. While most eye care practitioners have, in their careers, seen thousands of drusen, their structure and composition have not been fully catalogued, their role in disease is unclear and their prognostic significance is just emerging. Better understanding of the composition and mechanism of formation of drusen may offer important clues about AMD's pathogenesis. In the future, measurements of drusen may contribute to precise quantification of an individual's risk of developing AMD.

Key points

- Drusen are small focal extracellular deposits underneath the retina, visible ophthalmoscopically as yellow dots.
- The more hard drusen there are, the greater the risk of developing soft drusen and retinal pigmentary changes, which in turn increase the risk of developing age-related macular degeneration.
- Much remains to be discovered about drusen.
- For the patient with drusen, basic advice on diet and smoking, and maintenance of a high level of vigilance for visual changes is the most appropriate management.

Conflicts of interest

None.

Funding

The first author was supported by a Dunhill Medical Trust/Royal College of Physicians Research Fellowship and a grant from the Alzheimer's Research Trust.

References

1. Hogg RE, Stevenson MR, Chakravarthy U *et al.* Early features of AMD. *Ophthalmology* 2007; 114: 1028.
2. Augood CA, Vingerling JR, de Jong PT *et al.* Prevalence of age-related maculopathy in older Europeans: the European Eye Study (EUREYE). *Arch Ophthalmol* 2006; 124: 529–35.
3. Crabb JW, Miyagi M, Gu X *et al.* Drusen proteome analysis: an approach to the etiology of age-related macular degeneration. *Proc Natl Acad Sci USA* 2002; 99: 14682–7.
4. Hageman GS, Luthert PJ, Victor Chong NH *et al.* An integrated hypothesis that considers drusen as biomarkers of immune-mediated processes at the RPE-Bruch's membrane interface in aging and age-related macular degeneration. *Prog Retin Eye Res* 2001; 20: 705–32.
5. Bird AC, Bressler NM, Bressler SB *et al.* The International ARM Epidemiological Study Group. An international classification and grading system for age-related maculopathy and age-related macular degeneration. *Surv Ophthalmol* 1995; 39: 367–74.
6. Ferris FL, Davis MD, Clemons TE *et al.* A simplified severity scale for age-related macular degeneration: AREDS Report No. 18. *Arch Ophthalmol* 2005; 123: 1570–4.
7. Wang JJ, Rochtchina E, Lee AJ *et al.* Ten-year incidence and progression of age-related maculopathy: the blue Mountains Eye Study. *Ophthalmology* 2007; 114: 92–8.
8. Klein R, Meuer SM, Knudtson MD *et al.* The epidemiology of retinal reticular drusen. *Am J Ophthalmol* 2008; 145: 317–26.
9. Russell SR, Gupta RR, Folk JC *et al.* Comparison of color to fluorescein angiographic images from patients with early-adult onset grouped drusen suggests drusen substructure. *Am J Ophthalmol* 2004; 137: 924–30.
10. Gass J. *Stereoscopic Atlas of Macular Diseases: Diagnosis and Treatment*, 2nd edition. St. Louis: Mosby, 1977.
11. Donders F. Beitrage zur pathologischen Anatomie des Auges. *Archiv Für Ophthalmologie* 1854; 1: 106–18.
12. Rudolf M, Clark ME, Chimento MF *et al.* Prevalence and morphology of druse types in the macula and periphery of eyes with age-related maculopathy. *Invest Ophthalmol Vis Sci* 2008; 49: 1200–9.
13. Haimovici R, Gantz DL, Rumelt S *et al.* The lipid composition of drusen, Bruch's membrane, and sclera by hot stage polarizing light microscopy. *Invest Ophthalmol Vis Sci* 2001; 42: 1592–9.
14. Mullins RF, Hageman GS. Human ocular drusen possess novel core domains with a distinct carbohydrate composition. *J Histochem Cytochem* 1999; 47: 1533–40.
15. Dentchev T, Milam AH, Lee VM *et al.* Amyloid-beta is found in drusen from some age-related macular degeneration retinas, but not in drusen from normal retinas. *Mol Vis* 2003; 9: 184–90.
16. Ishibashi T, Patterson R, Ohnishi Y *et al.* Formation of drusen in the human eye. *Am J Ophthalmol* 1986; 101: 342–53.

17. Hageman GS, Mullins RF, Russell SR *et al.* Vitronectin is a constituent of ocular drusen and the vitronectin gene is expressed in human retinal pigmented epithelial cells. *Faseb J* 1999; 13: 477–84.
18. Johnson LV, Ozaki S, Staples MK *et al.* A potential role for immune complex pathogenesis in drusen formation. *Exp Eye Res* 2000; 70: 441–9.
19. Li CM, Clark ME, Chimento MF *et al.* Apolipoprotein localization in isolated drusen and retinal apolipoprotein gene expression. *Invest Ophthalmol Vis Sci* 2006; 47: 3119–28.
20. Bressler NM, Munoz B, Maguire MG *et al.* Five-year incidence and disappearance of drusen and retinal pigment epithelial abnormalities. Waterman study. *Arch Ophthalmol* 1995; 113: 301–8.
21. Vingerling JR, Dielemans I, Hofman A *et al.* The prevalence of age-related maculopathy in the Rotterdam Study. *Ophthalmology* 1995; 102: 205–10.
22. Klein R, Klein BE, Linton KL. The Beaver Dam Eye Study. Prevalence of age-related maculopathy. *Ophthalmology* 1992; 99: 933–43.
23. Mitchell P, Smith W, Attebo K *et al.* The Blue Mountains Eye Study. Prevalence of age-related maculopathy in Australia. *Ophthalmology* 1995; 102: 1450–60.
24. Cruickshanks KJ, Hamman RF, Klein R *et al.* The Colorado-Wisconsin Study of Age-Related Maculopathy. The prevalence of age-related maculopathy by geographic region and ethnicity. *Arch Ophthalmol* 1997; 115: 242–50.
25. VanNewkirk MR, Nanjan MB, Wang JJ *et al.* The prevalence of age-related maculopathy: the visual impairment project. *Ophthalmology* 2000; 107: 1593–600.
26. Munoz B, Klein R, Rodriguez J *et al.* Prevalence of age-related macular degeneration in a population-based sample of Hispanic people in Arizona: Proyecto VER. *Arch Ophthalmol* 2005; 123: 1575–80.
27. Gupta SK, Murthy GV, Morrison N *et al.* Prevalence of early and late age-related macular degeneration in a rural population in northern India: the INDEYE feasibility study. *Invest Ophthalmol Vis Sci* 2007; 48: 1007–11.
28. Varma R, Fraser-Bell S, Tan S *et al.* Prevalence of age-related macular degeneration in Latinos: the Los Angeles Latino eye study. *Ophthalmology* 2004; 111: 1288–97.
29. Dickinson AJ, Sparrow JM, Duke AM *et al.* Prevalence of age-related maculopathy at two points in time in an elderly British population. *Eye* 1997; 11: 301–14.
30. Schachat AP, Hyman L, Leske MC *et al.* The Barbados Eye Study Group. Features of age-related macular degeneration in a black population. *Arch Ophthalmol* 1995; 113: 728–35.
31. Bressler NM, Bressler SB, West SK *et al.* The grading and prevalence of macular degeneration in Chesapeake Bay watermen. *Arch Ophthalmol* 1989; 107: 847–52.
32. Anderson DH, Mullins RF, Hageman GS *et al.* A role for local inflammation in the formation of drusen in the aging eye. *Am J Ophthalmol* 2002; 134: 411–31.
33. Luitl V, Isas JM, Kayed R *et al.* Drusen deposits associated with aging and age-related macular degeneration contain nonfibrillar amyloid oligomers. *J Clin Invest* 2006; 116: 378–85.
34. Nozaki M, Raisler BJ, Sakurai E *et al.* Drusen complement components C3a and C5a promote choroidal neovascularization. *Proc Natl Acad Sci USA* 2006; 103: 2328–33.
35. Lotery A, Trump D. Progress in defining the molecular biology of age related macular degeneration. *Hum Genet* 2007; 122: 219–36.
36. Leske MC, Wu SY, Hennis A *et al.* Nine-year incidence of age-related macular degeneration in the Barbados Eye Studies. *Ophthalmology* 2006; 113: 29–35.
37. Klein R, Klein BE, Knudtson MD *et al.* Fifteen-year cumulative incidence of age-related macular degeneration: the Beaver Dam Eye Study. *Ophthalmology* 2007; 114: 253–62.
38. Buch H, Nielsen NV, Vinding T *et al.* 14-year incidence, progression, and visual morbidity of age-related maculopathy: the Copenhagen City Eye Study. *Ophthalmology* 2005; 112: 787–98.
39. Miyazaki M, Kiyohara Y, Yoshida A *et al.* The 5-year incidence and risk factors for age-related maculopathy in a general Japanese population: the Hisayama study. *Invest Ophthalmol Vis Sci* 2005; 46: 1907–10.
40. Sparrow JM, Dickinson AJ, Duke AM *et al.* Seven year follow-up of age-related maculopathy in an elderly British population. *Eye* 1997; 11(Pt 3): 315–24.
41. Jonasson F, Arnarsson A, Peto T *et al.* 5-year incidence of age-related maculopathy in the Reykjavik Eye Study. *Ophthalmology* 2005; 112: 132–8.
42. van Leeuwen R, Klaver CC, Vingerling JR *et al.* The risk and natural course of age-related maculopathy: follow-up at 6 1/2 years in the Rotterdam study. *Arch Ophthalmol* 2003; 121: 519–26.
43. Chang MA, Bressler SB, Munoz B *et al.* Racial differences and other risk factors for incidence and progression of age-related macular degeneration: Salisbury Eye Evaluation (SEE) Project. *Invest Ophthalmol Vis Sci* 2008; 49: 2395–402.
44. Mukesh BN, Dimitrov PN, Leikin S *et al.* Five-year incidence of age-related maculopathy: the Visual Impairment Project. *Ophthalmology* 2004; 111: 1176–82.
45. Klein R, Dais MD, Magli YL *et al.* The Wisconsin age-related maculopathy grading system. *Ophthalmology* 1991; 98: 1128–34.
46. Thornton J, Edwards R, Mitchell P *et al.* Smoking and age-related macular degeneration: a review of association. *Eye* 2005; 19: 935–44.
47. Gass JD. Photocoagulation of macular lesions. *Trans Am Acad Ophthalmol Otolaryngol* 1971; 75: 580–608.
48. Olk RJ, Friberg TR, Stickney KL *et al.* Therapeutic benefits of infrared (810-nm) diode laser macular grid photocoagulation in prophylactic treatment of nonexudative age-related macular degeneration: two-year results of a randomized pilot study. *Ophthalmology* 1999; 106: 2082–90.
49. Choroidal Neovascularization Prevention Trial Research Group. Laser treatment in eyes with large drusen. Short-term effects seen in a pilot randomized clinical trial. *Ophthalmology* 1998; 105: 11–23.
50. Owens SL, Guymer RH, Gross-Jendroska M *et al.* Fluorescein angiographic abnormalities after prophylactic macular photocoagulation for high-risk age-related maculopathy. *Am J Ophthalmol* 1999; 127: 681–7.
51. Friberg TR, Musch DC, Lim JI *et al.* Prophylactic treatment of age-related macular degeneration report number 1: 810-nanometer laser to eyes with drusen. Unilaterally eligible patients. *Ophthalmology* 2006; 113: 622 e1.
52. Laser treatment in patients with bilateral large drusen: the complications of age-related macular degeneration prevention trial. *Ophthalmology* 2006; 113: 1974–86.
53. Evans JR, Henshaw K. Antioxidant vitamin and mineral supplements for preventing age-related macular degeneration. *Cochrane Database Syst Rev* 2008; CD000253.

54. A randomized, placebo-controlled, clinical trial of high-dose supplementation with vitamins C and E, beta carotene, and zinc for age-related macular degeneration and vision loss: AREDS report no. 8. *Arch Ophthalmol* 2001; 119: 1417–36.
55. Evans JR. Antioxidant vitamin and mineral supplements for slowing the progression of age-related macular degeneration. *Cochrane Database Syst Rev* 2006; CD000254.
56. Tan JS, Mitchell P, Rochtchina E *et al.* Statins and the long-term risk of incident age-related macular degeneration: the Blue Mountains Eye Study. *Am J Ophthalmol* 2007; 143: 685–7.
57. van Leeuwen R, Tomany SC, Wang JJ *et al.* Is medication use associated with the incidence of early age-related maculopathy? Pooled findings from 3 continents. *Ophthalmology* 2004; 111: 1169–75.
58. Smeeth L, Cook C, Chakravarthy U *et al.* A case control study of age related macular degeneration and use of statins. *Br J Ophthalmol* 2005; 89: 1171–5.
59. McGwin G, Jr, Modjarrad K, Hall TA *et al.* 3-hydroxy-3-methylglutaryl coenzyme a reductase inhibitors and the presence of age-related macular degeneration in the Cardiovascular Health Study. *Arch Ophthalmol* 2006; 124: 33–7.
60. Delcourt C, Michel F, Colvez A *et al.* Associations of cardiovascular disease and its risk factors with age-related macular degeneration: the POLA study. *Ophthalmic Epidemiol* 2001; 8: 237–49.
61. Wong TY, Rogers SL. Statins and age-related macular degeneration: time for a randomized controlled trial? *Am J Ophthalmol* 2007; 144: 117–9.
62. Ings S. *The Eye, a Natural History*, London: Bloomsbury Publishing, 2007.

Received 8 January 2009; accepted in revised form 21 May 2009